

# Case reports

---

## Cerebrovascular accident with unusual electrocardiographic changes

Gary J. Anderson, M.D.

Robert Woodburn, M.D.\*

Charles Fisch, M.D., F.A.C.C.

Indianapolis, Ind.

Recent reports<sup>1-4</sup> and reviews<sup>5-7</sup> have drawn attention to the electrocardiographic (ECG) changes in cerebrovascular disease. The purpose of this case report is to describe interesting and relatively unusual electrocardiographic changes in a ten-year-old girl with pathologically proven intracerebral hemorrhage.

### Case report

The patient, a ten-year-old girl, was admitted on June 19, 1971, because of a left hemiparesis. The child had previously been in excellent health until the morning of admission, when upon rising, she complained of abdominal pain, pain over her right eye, and shortly thereafter developed left hemiparesis. No seizure activity was noted, nor was a history of trauma elicited.

Physical examination revealed a well-developed, poorly-responsive female child. The apical heart rate was 60 and irregular, and the blood pressure was 110/70 mm. Hg. Respirations were 20 per minute. Cardiac auscultation was unremarkable except for the irregular rhythm. Neurological examination revealed anisocoria, R > L, and both pupils showed a sluggish light response. Dysconjugate gaze was noted. Ophthalmoscopic examination was un-

remarkable. Left hemiplegia was apparent, and was associated with a positive Babinski sign on the left.

Complete blood count, serum sodium, chloride, CO<sub>2</sub> content blood urea nitrogen, calcium, and urinalysis were all normal. Serum potassium was 2.8 mEq./L. Arterial oxygen saturation was 96.6 per cent and Pco<sub>2</sub> was 40.0 mm. Hg. Arterial pH was 7.308. Sickle cell preparation was negative. Chest x-ray and skull films were unremarkable. Cerebral angiograms were within normal limits. Lumbar puncture revealed grossly bloody cerebrospinal fluid. A rhythm strip obtained in the emergency room (Fig. 1, *top*) demonstrated Mobitz Type I second degree AV block with junctional escape beats and periods of AV dissociation. The patient was given 0.3 mg. of atropine intravenously, and 1:1 conduction resumed with sinus tachycardia and wandering atrial pacemaker (Fig. 1, *bottom*). The child's clinical course deteriorated with deepening coma and hypothermia (rectal temperature 94° F.). A 12-lead ECG at that time (Fig. 2) revealed sinus bradycardia with a rate of 50 per minute and a P-R interval of 0.18 second. The ST segment was elevated. Maximal ST segment elevation occurred in Leads V<sub>2</sub>, V<sub>3</sub>, and V<sub>4</sub> with an elevation exceeding 5 mm. The QT interval was 0.64 second and QT<sub>c</sub> was 0.58 second. The patient died 29 hours after admission.

Necropsy examination was unremarkable except for the findings in the central nervous system.

From The Krannert Institute of Cardiology, Marion County General Hospital, and the Department of Medicine, Indiana University School of Medicine, Indianapolis, Ind.

Supported in part by the Herman C. Krannert Fund, United States Public Health Service Grants HL-06308, HL-05363, and HL-05749, the Indiana Heart Association, and the American Medical Association Committee for Research on Tobacco and Health.

Received for publication Oct. 12, 1972.

Reprint requests to: Gary J. Anderson, M.D., 1100 West Michigan St., Indianapolis, Ind. 46202.

\*Dr. Woodburn is a Resident in Medicine, Department of Medicine, Indiana University School of Medicine, Indianapolis, Ind.

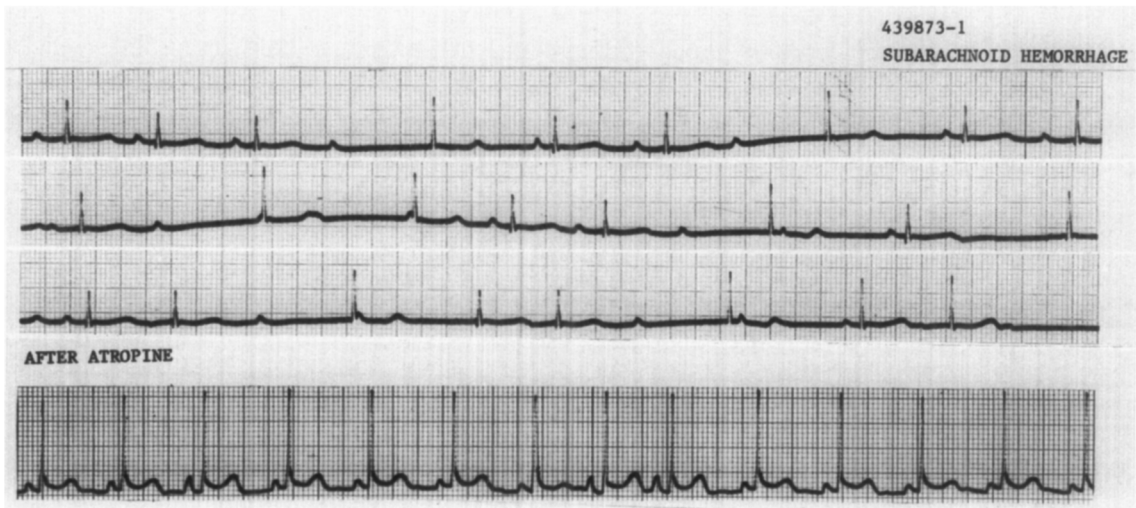


Fig. 1. *Top panel*, Rhythm strip of the patient on admission demonstrating Mobitz Type I AV block with periods of AV dissociation. *Bottom panel*, Restoration of 1 : 1 conduction with wandering atrial pacemaker after 0.3 mg. atropine intravenously.

A vascular malformation was found to involve the cingulate gyrus at the right frontal-parietal junction. This vascular malformation had ruptured resulting in intraventricular and subarachnoid hemorrhage. Transtentorial and transforaminal herniation had occurred.

### Discussion

The case reported is characterized by two interesting electrocardiographic changes.

Fig. 1 demonstrates second degree AV block and periods of AV dissociation with return of AV conduction to normal following administration of atropine. To our knowledge the Wenckebach block seen in this patient, clearly related to a cerebrovascular accident, has not been previously described, although 2 : 1 block has been observed.<sup>4</sup>

Recent papers<sup>8-11</sup> have drawn attention to the fact that increased vagal tone contributes to the development of the observed arrhythmias in cerebrovascular accident. Experimental studies<sup>12</sup> have shown that the production of Wolff-Parkinson-White pre-excitation and AV dissociation<sup>8,12</sup> may occur with electrical stimulation of the mesencephalic reticular formation or the dorsomedial hypothalamic nucleus. These experimental studies suggest that enhanced vagal tone significantly contributes to the development of various cardiac arrhythmias. Such enhanced vagal tone may be a result of stimulation of vagal fibers innervating the circle of Willis,<sup>13</sup> enhanced vagal

tone secondary to the baroreceptor reflex,<sup>8</sup> or stimulation of Area 13, the chief cortical representation of the vagus nerve.<sup>9</sup> In our patient the lesion involved the cingulate gyrus, containing Areas 23, 24, and 32. These areas are thought to control autonomic functions of the heart.<sup>9,14</sup> Thus, involvement of the cingulate gyrus may have accounted for the observed cardiac arrhythmia.

A second interesting feature of this case is the ST and T wave changes. Cerebrovascular accidents are, as a rule, associated with ST segment prolongation and depression<sup>1</sup> and T wave inversion,<sup>1,3</sup> occasionally simulating myocardial infarction.<sup>15,16</sup> On the other hand, ST segment elevation is less frequently observed.<sup>16</sup> It has been proposed<sup>1</sup> that such changes may be secondary to electrolyte imbalance, pH, and blood gas abnormalities, the latter supported by experimental studies.<sup>17,18</sup> Abnormalities of serum  $K^+$  and pH were observed in the reported case and may have contributed to the ECG pattern of elevated ST segment.<sup>18</sup> Hypokalemia has also been implicated in the development of second degree heart block.<sup>19</sup> The second positive deflection at the J junction (Fig. 2, Leads II, III, aV<sub>F</sub>, and V<sub>4</sub> through V<sub>6</sub>), as well as the prolonged QT<sub>c</sub> may have been due, in part, to hypothermia,<sup>20,21</sup> in addition to enhanced vagal tone.

Experimental studies have demonstrated

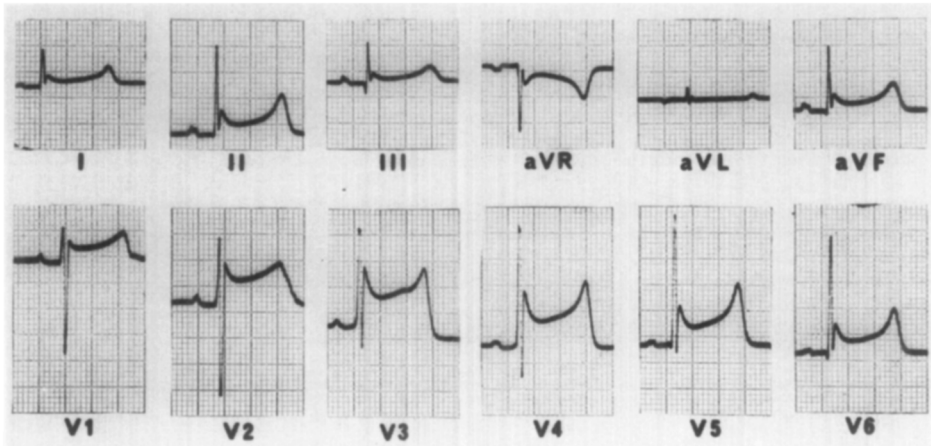


Fig. 2. Twelve lead electrocardiogram approximately 24 hours after admission (see text).

that intracerebral disease may induce sub-endocardial hemorrhage<sup>6</sup> and ultrastructural myocardial changes.<sup>22,23</sup> Such changes may be of sufficient magnitude to induce Q waves.<sup>6</sup> While the association between cerebrovascular accidents and myocardial infarction has been made in patients prone to both conditions,<sup>16</sup> the question may be raised as to whether ST segment elevation may be due to myocytolysis alone. The case reported demonstrated normal microscopic examination of the heart, suggesting that the ST segment changes were mediated either by alteration of autonomic tone, pH, electrolyte disturbances, or a combination of all of these factors.

### Summary

This case report describes a 10-year-old girl sustaining a cerebrovascular accident secondary to a vascular malformation involving the cingulate gyrus. The patient developed a Mobitz Type I block with periods of AV dissociation. A 12-lead electrocardiogram revealed the frequently observed prolongation of the QT interval. Her ECG also demonstrated diffuse ST segment elevation. Neurophysiological mechanisms are discussed.

### REFERENCES

1. Burch, G. E., Myers, R., and Abildskov, J. A.: A new electrocardiographic pattern observed in cerebrovascular accidents, *Circulation* **9**:719, 1954.
2. Levine, H.: Non-specificity of the electrocardiogram associated with coronary artery disease, *Am. J. Med.* **15**:344, 1953.
3. Hersch, C.: Electrocardiographic changes in head injuries, *Circulation* **28**:853, 1961.
4. Hersch, C.: Electrocardiographic changes in subarachnoid hemorrhage, meningitis, and intracranial space occupying lesions, *Br. Heart J.* **26**:785, 1964.
5. Abildskov, J. A., Millar, K., Burgess, M. J., and Vincent, W.: The electrocardiogram and the central nervous system, *Progr. Cardiovasc. Dis.* **13**:210, 1970.
6. Greenhoot, J. H., and Reichenbach, D. D.: Cardiac injury and subarachnoid hemorrhage: a clinical, pathological and physiological correlation, *J. Neurosurg.* **30**:521, 1969.
7. Abildskov, J. A.: Electrocardiographic waveforms and the nervous system, *Circulation* **41**:371, 1970.
8. Korteweg, G. C. J., Boeles, J. F., and Ten Cate, J.: Influence of stimulation of some subcortical areas on electrocardiogram, *J. Neurophysiol.* **20**:100, 1957.
9. Fulton, J. F.: Functional localization in the frontal lobes and cerebellum, London, 1949, Oxford University Press, p. 66.
10. Jacobson, S. A., and Danufsky, P.: Marked electrocardiographic changes produced by head trauma, *J. Neuropathol. Exp. Neurol.* **13**:462, 1954.
11. Smith, M., and Ray, C. T.: Cardiac arrhythmias, increased intracranial pressure, and the autonomic nervous system, *Dis. Chest* **61**:125, 1972.
12. Mauck, H. P., Hockman, C. H., and Hoff, E. C.: ECG changes after cerebral stimulation I. Anomalous atrioventricular excitation elicited by electrical stimulation of the mesencephalic reticular formation, *AM. HEART J.* **38**:98, 1964.
13. Poole, J. L.: Vasocardiac effects of the circle of Willis, *Arch. Neurol. Psychiatr.* **78**:355, 1957.
14. Brodal, A.: Neurological anatomy in relation to clinical medicine, London, 1969, Oxford University Press, p. 662.
15. Beard, E. F., Robertson, J. W., and Robertson, R. C.: Spontaneous subarachnoid hemorrhage stimulating acute myocardial infarction, *AM. HEART J.* **58**:755, 1959.

16. Cropp, G. J., and Manning, G. J.: Electrocardiographic changes simulating myocardial ischemia and infarction associated with spontaneous intracranial hemorrhage, *Circulation* **22**:25, 1960.
17. Roberts, K. E., and Magida, M. G.: Electrocardiographic alterations produced by a decrease in plasma, pH, bicarbonate, and sodium as compared with those produced by an increase in potassium, *Circ. Res.* **1**:206, 1953.
18. Magida, M. G., and Roberts, K. E.: Electrocardiographic alterations produced by an increase in plasma, pH, bicarbonate and sodium as compared with those seen in a decrease in potassium, *Circ. Res.* **1**:214, 1953.
19. Fisch, C., Knoebel, S. B., Feigenbaum, H., and Greenspan, K.: Potassium and the monophasic action potential, electrocardiogram, conduction and arrhythmias, *Progr. Cardiovasc. Dis.* **8**:387, 1966.
20. Osborn, J. J.: Experimental hypothermia: respiratory and blood pH changes in relation to cardiac function, *Am. J. Physiol.* **175**:389, 1953.
21. Byer, E., Ashman, R., and Toter, L. A.: Electrocardiogram with large upright T waves and long Q-T intervals, *AM. HEART J.* **33**:796, 1947.
22. Burch, G. E., Sobral, R. S., Sun, S. C., and Colcolough, H. L.: Effects of experimental intracranial hemorrhage on the ultrastructure of the myocardium of mice, *AM. HEART J.* **77**:427, 1969.
23. Connor, R. C.: Heart damage associated with intracranial lesions, *Br. Med. J.* **3**:29, 1968.