

Bilateral extracranial internal carotid artery injury due to non-penetrating trauma—report of three cases

By T. M. H. Chakera, M.R.C.P., F.R.C.R., M.R.A.C.R.

Department of Diagnostic Radiology, Royal Perth Hospital, Perth, Western Australia

(Received December 1978 and in revised form April 1979)

ABSTRACT

Angiographic features of three patients with bilateral internal carotid artery injury (spasm/dissection/thrombosis) due to non-penetrating trauma are reported. All three patients were involved in motor vehicle accidents. Focal-localizing neurological signs were present and the patients were suspected of having extracerebral haematomas. The diagnosis of traumatic spasm/dissection/thrombosis of the cervical portion of the internal carotid arteries was made following angiography. The need to include views of the cervical carotid arteries in cases of traumatic hemiparesis is stressed and possible effect of cranial CT scanning in these patients on diagnosis of carotid artery injury discussed.

Spasm and thrombosis (with or without complete occlusion) of the extracranial internal carotid artery resulting from blunt trauma has been reported not infrequently in medical literature. However, to date there has only been one report of bilateral internal carotid thrombosis associated with non-penetrating trauma (Ojemann and Moser, 1964). All three patients described here with bilateral carotid artery injury were suspected of having an epi- or subdural haematoma and the diagnosis was not made until carotid angiography was carried out.

CASE REPORTS

Case 1

A forty-four-year-old woman, who was the driver of a car involved in a head-on collision, was admitted to another hospital complaining of left hip pain. She was wearing a seat belt and was not displaced from her seat. There was no evidence of trauma to the head and neck. Radiographs of the pelvis and left hip did not reveal any fracture. Two-and-a-half hours following admission she had a grand-mal fit and was transferred to Royal Perth Hospital where a neurological examination revealed a left hemiparesis. Again, no external evidence of head and neck injury was detected. Skull and cervical spine radiographs showed no abnormality. Clinical diagnosis of acute right subdural haematoma was made and a bilateral carotid angiogram was carried out. This showed severe, remarkably symmetrical, luminal narrowing and irregularity of both the internal carotid arteries (Figs. 1 and 2). Angiographic interpretation was that the patient had suffered a non-penetrating injury to the cervical portion of the two internal carotid arteries resulting in intimal tears associated with severe spasm and thrombosis. There was no intracranial space occupying lesion and left hemiparesis was thought to be due to distal embolization. The patient was anticoagulated and despite extensive rehabilitation, has made no neurological recovery.

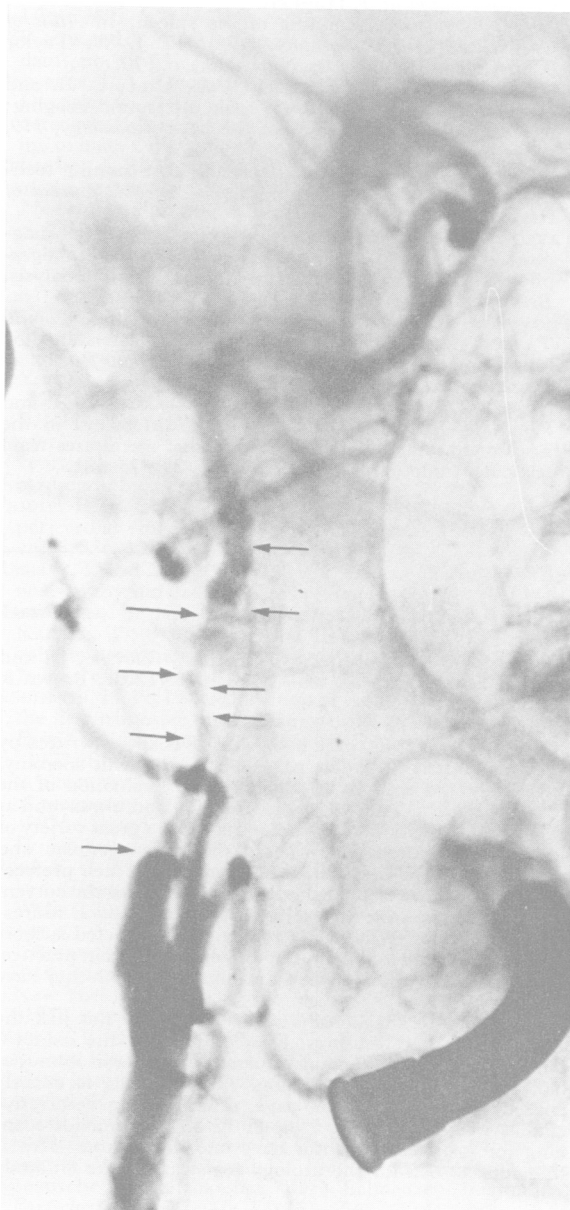


FIG. 1.
Right carotid angiogram.

Bilateral extracranial internal carotid artery injury due to non-penetrating trauma

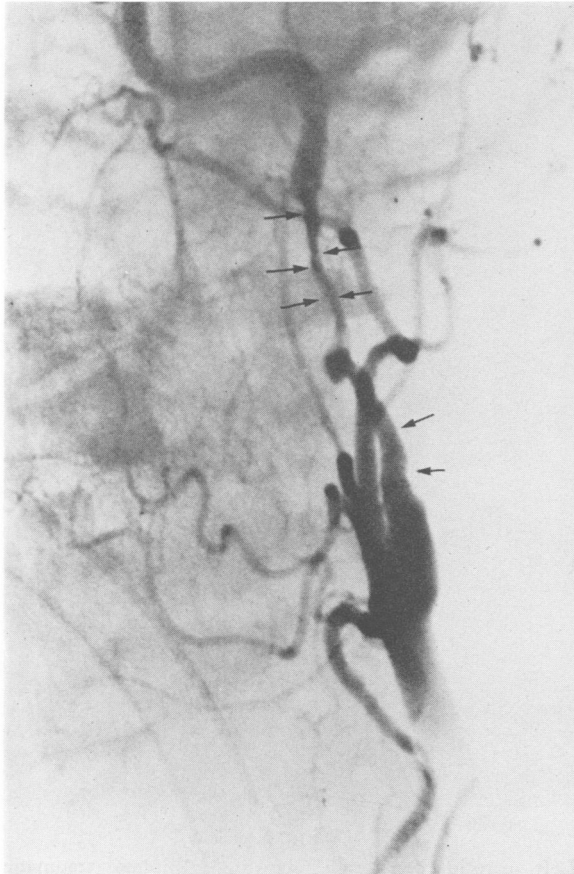


FIG. 2.

Left carotid angiogram. Oblique views showing, as on the right, severe luminal irregularity and narrowing of the internal carotid artery.

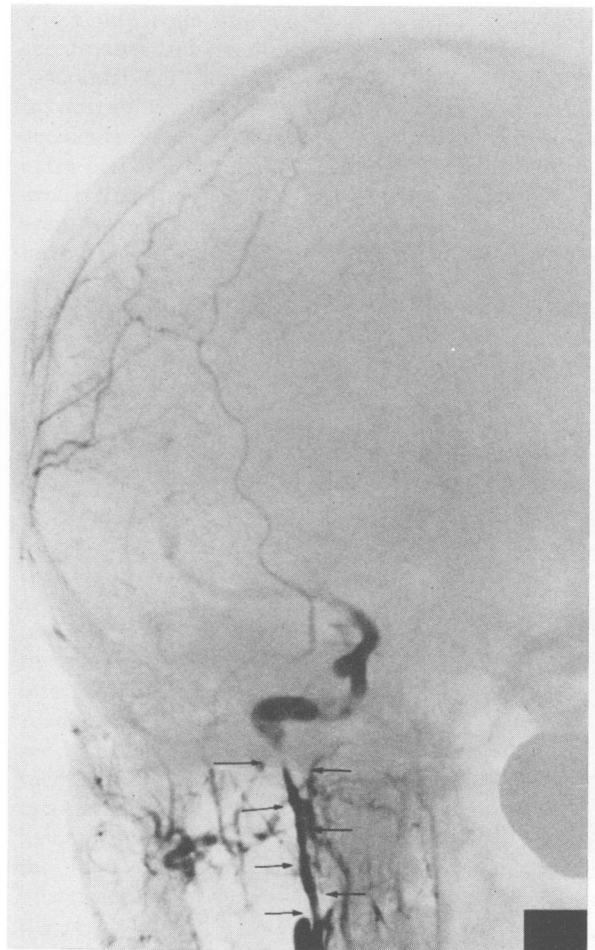


FIG. 3.

Right carotid angiogram showing intimal dissection and narrowing of the lumen of internal carotid artery.

Case 2

A twenty-two-year-old girl (front seat passenger) was thrown out of the car which was involved in an accident. When seen in casualty, she was stuporose and had a left hemiparesis. There was no evidence of trauma to the neck. Radiographs revealed a linear fracture of the right parietal bone. Cervical spine radiographs showed no abnormality. A clinical diagnosis of right-sided epidural haematoma was made. Angiography revealed intimal dissection with incomplete thrombosis of the right internal carotid artery extending from 2.5 cm beyond the bifurcation to the base of the skull, with poor perfusion of the middle cerebral artery (Fig. 3). The left internal carotid artery showed extensive smooth narrowing due to traumatic spasm (Fig. 4). Both the anterior cerebral arteries opacified from the left side. The patient was treated with Dexamethasone and Rheomacrodex. Follow-up 18 months later shows good neurological recovery with minimal residual weakness of the left leg.

Case 3

A twenty-year-old girl was the front seat passenger in a car which was involved in a head-on collision. She was wearing a seat belt and was restrained in her seat. On admission, she was noted to have a right hemiplegia.

There was no evidence of injury to the neck and the admitting casualty officer remarked that the carotid artery pulsations were present and normal. Skull and cervical spine radiographs were normal. Clinically she was suspected of having an acute left-sided subdural haematoma. Angiography revealed complete occlusion of the left internal carotid artery, secondary to traumatic thrombosis extending from 3.0 cm above the bifurcation up to the intracavernous portion of the carotid artery (Fig. 5). The right internal carotid artery showed spasm of a 3.5 cm length of the carotid artery just below the base of the skull (Fig. 6). There was no intracranial space effect. At operation, the presence of traumatic intimal dissection and thrombosis of the left internal carotid artery was confirmed and an endarterectomy was carried out. The adventitia was noted to be intact. Post-operatively she deteriorated and died. Post-mortem examination revealed re-thrombosis of the left internal carotid artery. The right carotid artery was intact and of normal calibre along its entire length, confirming that the segmental narrowing seen on angiography was due to spasm without underlying intimal damage.

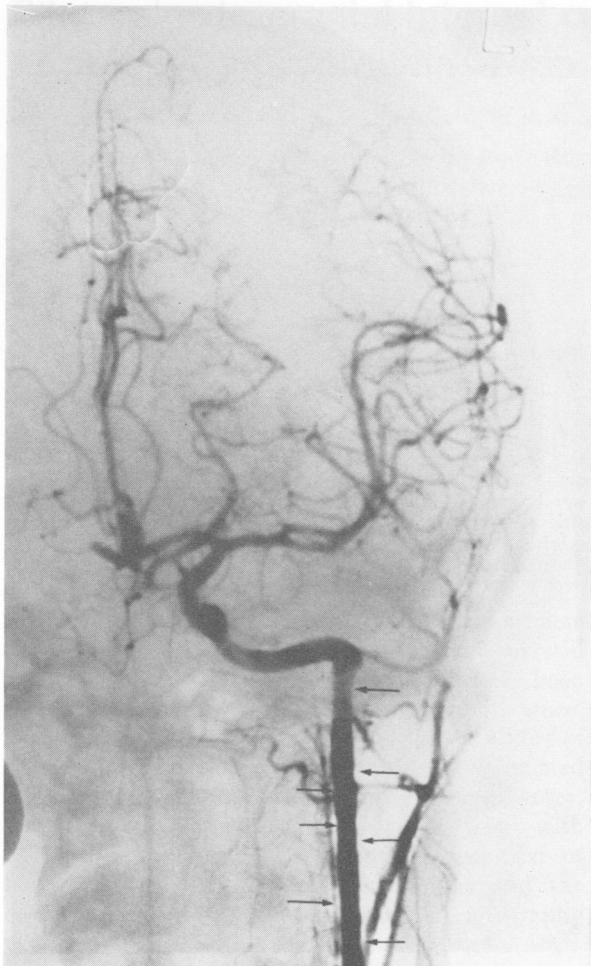


FIG. 4.

Left carotid angiogram showing extensive spasm and "straightening" of the internal carotid artery.

DISCUSSION

In the last three years, we have documented seven cases of internal carotid artery injury following non-penetrating trauma to the neck. Of these, the three cases presented here showed bilateral carotid artery lesions. It is accepted that contusion or stretching of a major artery can damage the intima and media of that vessel (Gurdjian *et al.*, 1971), to cause its occlusion by spasm or thrombosis (Houck *et al.*, 1964). Intimal lacerations may lead to stripping of the intima where the dissected lining forms a plug and occludes the vessel or the intimal tear becomes the site of thrombus formation. Injury to the intima and media may also lead to aneurysm formation (Sullivan *et al.*, 1973). It is of

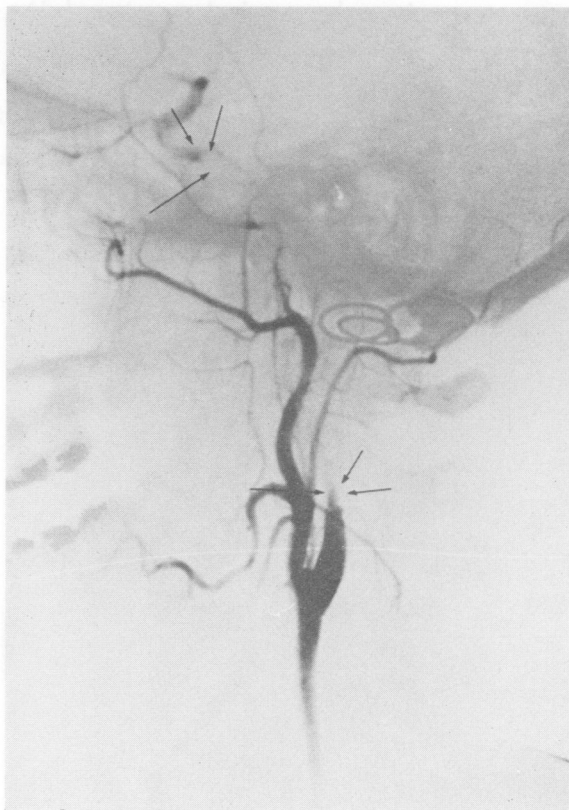

FIG. 5.

Left carotid angiogram showing complete traumatic thrombosis of the internal carotid artery from 3.0 cm above the bifurcation. Note the retrograde filling of the terminal carotid artery.

interest to note that in two of the cases reported here (Nos. 2 and 3) the site of the arterial spasm corresponds to the anatomical explanation put forward by New and Momose (1969). They noted that the distal portion of the cervical carotid artery lies anterior to the lateral articular mass of the atlas. Extension of the head and neck stretches and partly fixes the carotid artery at this level, and contralateral rotation of the head occurring at the atlanto-axial joint further stretches the artery. These two movements carried out suddenly and to the extreme are likely to cause focal compression of the internal carotid artery.

None of the three cases reported here was suspected of having carotid artery injury. Yamada, in a study of 52 cases of injury to the internal carotid artery due to acute non-penetrating trauma, found that only three of the 52 cases were admitted with the diagnosis of carotid artery insufficiency

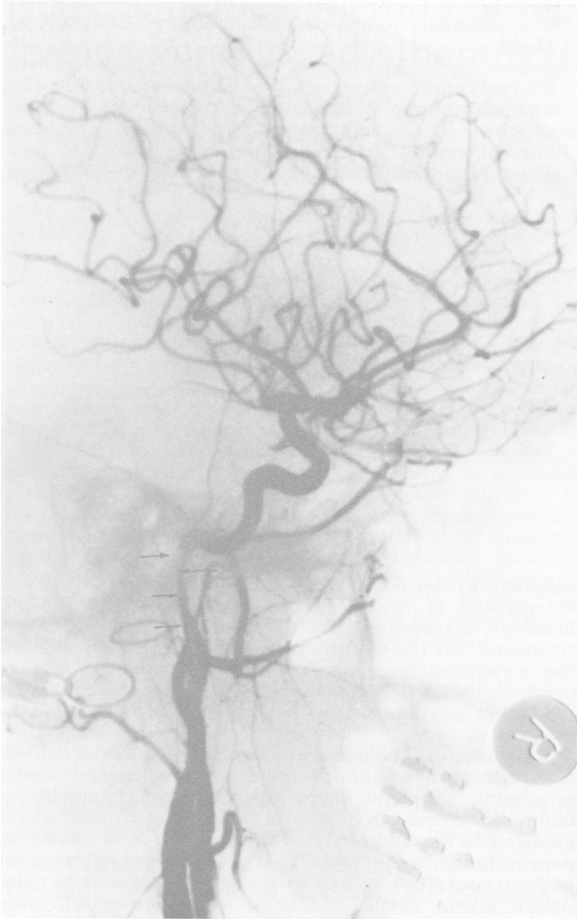Bilateral extracranial internal carotid artery injury due to non-penetrating trauma

FIG. 6.

Right carotid angiogram showing spasm of the internal carotid artery below the skull base.

due to trauma (Yamada *et al.*, 1967). Diagnosis of carotid artery occlusions in non-penetrating injuries is very difficult as the clinical picture resembles that of the more common epi- or subdural haematoma. That the pulsation of vessels in the neck is of poor diagnostic value has been amply confirmed by our third case (Schneider and Lammens 1952). It has been said in the past and this article concurs, that apart from an autopsy, angiography is the only accurate method of diagnosing traumatic lesions of the carotid artery (Gurdjian *et al.*, 1963). Development of neurological signs may be delayed up to 24 hours. The latent period probably represents the time necessary for the formation of thrombus and subsequent occlusion of the vessel or distal embolization. Case 1 reported in this paper had no neurological symptoms or signs when first seen;

left hemiparesis was noted following a grand-mal seizure two-and-a-half hours after admission.

Cranial CT scanning, rightly, is now the first investigation in patients involved in motor vehicle accidents who are suspected of having intra- or extra-cerebral haematoma. However, one should be aware that the patients with a negative cranial CT scan, who have definite neurological signs, may have carotid artery injury even though there may not be any external manifestation of trauma to the neck. Already CT scanning has led to a great reduction in angiograms carried out in most neurosurgical centres. This decrease in the number of carotid angiograms in patients with suspected head trauma may, in fact, lead to a "false" reduction in the number of diagnosed carotid artery injuries from non-penetrating trauma. When carotid angiography is carried out in patients suspected of having epi- or subdural haematoma, it is imperative that the views of the cervical portion of the carotid arteries are included. If this is not done, then patients who are suffering from spasm/dissection/thrombosis of the extracranial portion of the internal carotid artery will be missed (Zilkha, 1970). Also, as indicated in this report, it is not unusual to see bilateral lesions. It is the policy of the Department of Diagnostic Radiology to carry out bilateral carotid angiography in all trauma cases suspected of having epi- or subdural haematoma. We feel that the high detection rate (three out of seven) of bilateral carotid artery lesions in our experience is the result of this policy. At Royal Perth Hospital, most of the cerebral angiography is performed by transfemoral catheterization. This approach, we feel, minimizes the risks of iatrogenic damage to the carotid arteries and allows bilateral carotid angiography to be carried out without much difficulty. In all three of our cases, post-traumatic hemiplegia was the reason for angiography. If the angiographic study had been limited to the appropriate side, bilaterality of lesions would not have been recognized. We would like to suggest that bilateral internal carotid artery injury is not uncommon in patients with non-penetrating trauma to the neck. A limited angiographic study advocated in the past (Murray, 1957) would account for the lack of previous reports indicating the bilaterality of lesions.

ACKNOWLEDGMENTS

I thank all members of the Department of Diagnostic Radiology for their encouragement and also thank the staff of the Department of Neurosurgery for allowing me to study these patients. My thanks also to Miss Alison Swales for typing this manuscript.

REFERENCES

- GURDJIAN, E. S., ANDET, B., SIBAYAN, R. W., and THOMAS, L. M., 1971. Spasm of the extracranial internal carotid artery resulting from blunt trauma demonstrated by angiography. *Journal of Neurosurgery*, 35, 742-747.
- GURDJIAN, E. S., HARDY, W. G., LINDNER, D. W., and THOMAS, L. M., 1963. Closed cervical cranial trauma associated with involvement of carotid and vertebral arteries. *Journal of Neurosurgery*, 20, 418-427.
- HOUCK, W. S., JACKSON, J. R., ODOM, G. L., and YOUNG, W. G., 1964. Occlusion of the internal carotid artery in the neck secondary to closed trauma to the head and neck. *Annals of Surgery*, 159, 219-221.
- MURRAY, D. S., 1957. Post-traumatic thrombosis of the internal carotid and vertebral arteries after non-penetrating injuries of the neck. *British Journal of Surgery* 44, 556-561.
- NEW, P. F. J., and MOMOSE, K. J., 1969. Traumatic dissection of the internal carotid artery at the atlantoaxial level secondary to non-penetrating injury. *Radiology*, 93, 41-49.
- OJEMANN, R. G., and MOSER, H. W., 1964. Acute bilateral internal carotid artery occlusion. Report of case following a parachute jump. *Neurology*, 14, 565-568.
- SCHNEIDER, R. C., and LEMMEN, L. J., 1952. Traumatic internal carotid artery thrombosis secondary to non-penetrating injuries to the neck. *Journal of Neurosurgery*, 9, 495-507.
- SULLIVAN, H. G., VINES, F. S., BECKER, D. P., 1973. Sequelae of indirect internal carotid injury. *Radiology*, 109, 91-98.
- YAMADA, S., KINDT, G. W., and YOUMANS, J. R., 1967. Carotid artery occlusion due to non-penetrating injury. *The Journal of Trauma*, 7, 333-342.
- ZILKHA, A., 1970. Traumatic occlusion of the internal carotid artery. *Radiology*, 97, 543-548.

Book review

Corcadeus' Gynaecologic Cancer (Fifth Edition). Edited by S. B. Gusberg and H. C. Frick II, pp. xii+494, 1978 (The Williams and Wilkins Company, Baltimore), \$49.50. ISBN 0-683-03854-0.

In the preface, the authors reflect that the 1940's were notable for the increasing sophistication of surgical and radiotherapeutic techniques, the 50's saw the trend towards methods of earlier diagnosis, the 60's heralded developments in cell physiology and kinetics for chemotherapy, radiation physics, tumour immunology and epidemiological studies to select high risk patients. The 1970's may be known as the "decade of therapeutic translation" when the insights derived can be applied.

The introduction covers the statistics of incidence, site, stage at presentation and the factors which influence the outcome. Known aetiological factors and the principles of diagnosis including cytology, histology and radiological methods are discussed. This section is well illustrated with photomicrographs and contains much useful information based on personal experience.

The principles of radiation therapy are covered in a broad way dealing with intracavitary and external radiation techniques. This is a short, factual chapter summarizing the art, providing the pros and cons of various treatments, giving dosages but avoiding detailed physics and radiotherapy techniques. I did not find any reference to after-loading techniques which can be so useful in reducing the exposure to staff and which in this country are becoming increasingly popular.

There is a chapter dealing with the principles of chemotherapy which, in addition to basic principles, includes reference to the dosages which are most often used in gynaecological malignancy. These are classified in the usual way based on their chemistry but there is also reference to the phases of action in relation to cell cycle theory. There is a particularly useful table of the characteristics and properties of the various stages of the cell cycle which makes a convenient summary of our present understanding.

Chapters then follow dealing in full detail with the

common gynaecological cancers. These cover the usual aspects such as incidence, aetiology, investigation, staging, histology, management and the results of various forms of treatment. All these chapters are very well illustrated and the views expressed are very representative of current practice. This will be of considerable value to those studying for higher examinations in radiotherapy as well as gynaecological surgery.

In addition to the more common neoplasms, the authors deal with sarcomas and various gestational trophoblastic neoplasms. The chapter about the latter covers hydatidiform mole and chorio-carcinoma in a way which offers sound guidance to the clinician. It is very good to see a section on pain included in the book. This discusses the neurological pathways involved as well as the various theories of pain, before giving details of the different analgesics, anti-depressants and surgical operations for control of pain.

As well as a useful account of menopausal problems there is a section on the endocrinological aspects of gynaecological cancer. This includes the physiological processes involved and also the production of hormones in certain pathological states, for example by tumours. Current views on the metabolism of hormones in target tissues and the present theory of the roles of receptor sites in breast cancer are included for completion. Breast cancer is usually not included in works on gynaecological cancer and understandably is not covered in this volume.

There is a particularly interesting chapter on basic clinical immunology for the gynaecologist. This covers this very complex topic in a concise and readable way. It was thoughtful to include a glossary of immunological terms which will be greatly appreciated.

The volume closes with chapters on epidemiology and biostatistics. It is an extremely well prepared work covering the subject and a great many more related problems, in a concise and informative way. It is well illustrated throughout and fully indexed. It can be highly recommended to radiotherapists and gynaecologists.

B. HALE.