

*Short report*

## Internal carotid artery occlusion caused by giant cell arteritis

R. E. CULL

*From the Department of Medical Neurology, University of Edinburgh, Royal Infirmary, Edinburgh*

**SUMMARY** A case of hemiplegia in a 46 year old woman is described. Total occlusion of the right internal carotid artery was discovered at angiography. Because of persistent elevation of the ESR, and characteristic plasma protein abnormalities, biopsy of the temporal artery was carried out and demonstrated the typical features of giant cell arteritis.

Giant cell arteritis is a disorder of unknown cause which affects a wide variety of large and medium-sized arteries (Cooke *et al.*, 1946; Meadows, 1966). Typically, the disease affects patients over 60 years of age, and the most common severe complication is blindness caused by involvement of the ophthalmic vessels (Ross Russell, 1959; Meadows, 1966). The patient described below sustained a hemiplegia as a result of occlusion of the internal carotid artery secondary to giant cell arteritis. This is a rare but noteworthy cause of stroke in middle age.

### Case report

A 46 year old housewife developed aching and stiffness in the left leg and knee. These symptoms disappeared spontaneously after three to four weeks. She remained well until some five months later when, after two days of light headedness and nausea, she awoke one morning with severe weakness of the left arm and leg. There were no other specific features in the history—in particular, there was no headache, malaise, weight loss, or visual disturbance.

Six weeks after the onset of the hemiplegia, the patient was admitted to a neurological unit. There had been some return of power to the left leg, but the arm remained profoundly weak. On examination, she had a left hemiparesis which involved the face. The tendon reflexes in the left arm and leg were pathologically brisk, and the left plantar response was extensor. The optic fundi and visual acuity were normal. Both com-

mon carotid and all peripheral limb pulses were palpable. There was no tenderness over the temporal arteries. There were no carotid nor cranial bruits. The pulse was regular at 80/minute; blood pressure was 140/80 mmHg. There were no cardiac murmurs. Carotid angiography showed a complete occlusion of the right internal carotid artery, just distal to its origin from the common carotid artery.

Routine haematology was normal apart from an ESR of 68 mm in the first hour. During the week after her admission the ESR rose to 84 mm in the first hour. Her fasting serum cholesterol was slightly elevated at 7.4 mmol/l (normal range: 3.9–6.2), while total glycerol was within normal limits. Lipoprotein electrophoresis showed an increase in the  $\beta$  fraction. Plasma protein analysis revealed: total protein 74 g/l; albumin 43.6 g/l; globulins (% of total)  $\alpha_1$  4.3 (normal 1–5.7),  $\alpha_2$  16.3 (normal 4.9–11.2),  $\beta$  16.6 (normal 7–13),  $\gamma$  19.2 (normal 9.8–18.2). Antinuclear and rheumatoid factors and serological tests for syphilis were all negative.

Because of the ESR and plasma protein pattern, and despite the absence of cranial tenderness, biopsy of the left superficial temporal artery was carried out. On microscopy, the lumen of the artery was found to be obliterated by intimal hypertrophy and fibrosis. The media and elastic layers were infiltrated with round cells and multinucleate giant cells. In places, the internal elastic lamina was disrupted and fragmented. The features were typical of giant cell arteritis (Figure).

The patient was given prednisolone 40 mg/day. The ESR fell to 30 mm in the first hour over the

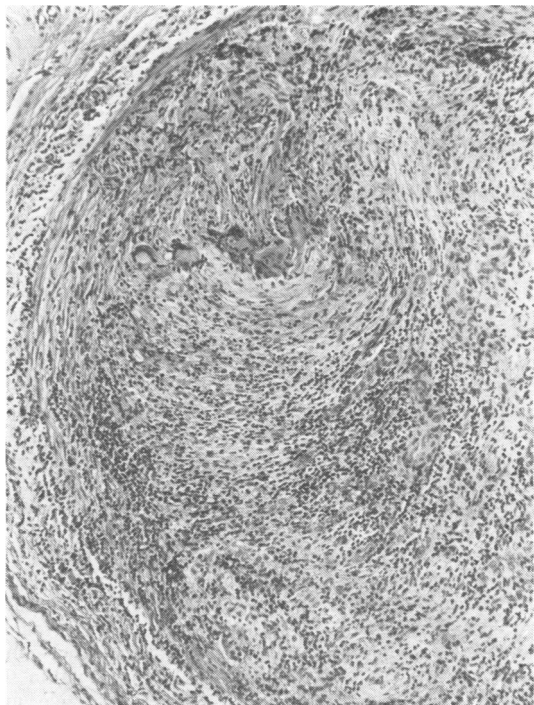


Figure Photomicrograph of section cut transversely through superficial temporal artery. Stained by haematoxylin and eosin, original magnification  $\times 120$ . The arterial lumen is occluded by intimal fibrosis and hypertrophy. The media is infiltrated with small round cells and giant cells.

next five days, and was 11 mm in the first hour 10 days after this. The patient remains on a maintenance dose of prednisolone and is regaining power in the left arm and leg.

### Discussion

Giant cell arteritis often involves branches of the external carotid artery (Meadows, 1966). The ophthalmic vessels are frequently severely

affected, and the resulting visual loss has been found in as many as 50% of cases (Ross Russell, 1959). Postmortem studies suggest that the vertebral arteries are also severely affected in a high proportion of cases (Wilkinson and Ross Russell, 1972), and this is supported by the occurrence of brain stem infarction in about 25% of cases in that study. Although mild involvement of internal carotid arteries was found in 10–25% of post-mortem cases (Wilkinson and Ross Russell, 1972), and several authors quote carotid disease as a complication (Ross Russell, 1959; Meadows, 1966; Wilkinson and Ross Russell, 1972), severe involvement of this vessel must be very rare. Ross Russell (1959) reported one case (out of a series of 35 cases) in which hemiplegia occurred; but carotid occlusion was not shown. Wilkinson and Ross Russell (1972) quote two cases of hemisphere ischaemia, but did not find carotid occlusion in any of the 12 cases they reviewed.

The case reported here indicates that internal carotid artery occlusion from giant cell arteritis may cause cerebral hemisphere infarction in middle age, and that this may occur in the absence of the usual symptoms and signs associated with the disorder.

I thank Dr C. Mawdsley for his permission and encouragement to report this case.

### References

- Cooke, W. T., Cloake, P. C. P., Govan, A. D. T., and Colbeck, J. C. (1946). Temporal arteritis: a generalised vascular disease. *Quarterly Journal of Medicine*, **15**, 47–75.
- Meadows, S. P. (1966). Temporal or giant cell arteritis. *Proceedings of the Royal Society of Medicine*, **59**, 329–333.
- Ross Russell, R. W. (1959). Giant cell arteritis. *Quarterly Journal of Medicine*, **28**, 471–489.
- Wilkinson, I. M. S., and Ross Russell, R. W. (1972). Arteries of the head and neck in giant cell arteritis. *Archives of Neurology (Chicago)*, **27**, 378–391.