

# Friedreich's Ataxia in Childhood

## Case Report with Possible Myocardial Infarction, Cerebrovascular Thromboembolization, and Persistent Elevation of Cardiac Specific LDH

Ehud Krongrad, M.D.,\* and Howard A. Joos, M.D.\*\*

**A seven-year old Caucasian girl with Friedreich's ataxia, cerebral thromboembolism, possible repeated myocardial infarctions and severe cardiac involvement is presented. The father and a paternal uncle both died of myocardial infarction at an early age. Persistent elevation of LDH isoenzyme 5 following angina-like attacks is reported for the first time in Friedreich's ataxia and suggests continuing damage to the myocardium.**

The clinical picture of Friedreich's ataxia (Fr at) is well known.<sup>1-3</sup> Onset of ataxia, hypoactive or absent knee and ankle reflexes and progressive cerebellar dysfunction are commonly the presenting symptoms. Intermediate forms and families in which one member presents the typical features while others show only abortive forms are also known.<sup>4,5</sup>

Only a few reports have documented the onset of the disease during childhood, particularly that with severe cardiac involvement as a major manifestation.<sup>6,7</sup> The cardiac involvement in childhood usually consists of electrocardiographic (ECG) changes,<sup>6</sup> occasionally cardiomegaly,<sup>1,6,7</sup> anginal pain or myocardial infarction,<sup>7,8</sup> and rarely congestive heart failure.<sup>3,6</sup> We are not aware, however, of a documented clinical case supported by laboratory evidence of myocardial infarction in the pediatric age group. We found only one case report in which serum glutamic oxalacetic transaminase (SGOT) and serum glutamic-pyruvic transaminase (SGPT) were elevated in a patient with Friedreich's ataxia.<sup>9</sup> This was the case in our patient on two different occasions. In addition, persistent elevation of cardiac specific serum lactic dehydrogenase (SLDH) was observed for more than 12 months and suggested for the first time laboratory evidence of continuous myocardial damage.

\*Associate, Division of Pediatric Cardiology, Department of Pediatrics, Babies Hospital, Columbia University, College of Physicians and Surgeons, New York.

\*\*Professor of Pediatrics, State University of New York, Downstate Medical Center; and Director of Pediatric Services Maimonides Medical Center, Brooklyn.

Reprint requests: Dr. Joos, 4802 Tenth Avenue, Brooklyn 11219

### CASE REPORT

A seven-year-old Caucasian girl was admitted to Maimonides Medical Center for evaluation and treatment of congenital heart disease and chronic congestive cardiac failure. The patient was the product of a normal full-term pregnancy and delivery; subsequent growth and development were normal. At the age of three years the patient was noted to have a waddling gait and poor balance. Her gait resembled that of a deceased sibling. Weakness was found in all extremities without loss of muscle bulk. Deep tendon reflexes were hypoactive and toe responses were flexor bilaterally. Results of skull x-ray examinations, electroencephalogram and serum creatinine were all reported as normal.

Because of a history of heart disease in a sibling, the patient was referred for cardiac evaluation. A soft apical systolic murmur was described, and the ECG was interpreted as showing combined ventricular hypertrophy. Chest x-ray films and cardiac fluoroscopy gave normal results.

At five years of age the patient was hospitalized elsewhere because of abdominal pain and vomiting. Pertinent physical findings included questionable distention of neck veins, liver palpable 2 to 3 cm below the right costal margin, absent deep tendon reflexes and flexor toe responses. The ECG showed marked left ventricular hypertrophy. ST segments were depressed and deep Q waves were seen in leads II, III and aVF. The chest x-ray picture showed marked cardiomegaly and pulmonary congestion. The patient was digitalized and received meralluride (Mercuhydrin). Pentaerythritol tetranitrate (Peritrate) was also given, and prednisone was added because of the possibility of myocarditis. Episodes of rapid heart rate occurred and complaints of abdominal and chest pain associated with general pallor. At such times the ECG showed tachycardia of 180 per minute. Diphenylhydantoin (Dilantin) was given in an effort to reduce myocardial irritability, and she improved enough to be discharged.

Three weeks later she was readmitted because of headache and vomiting. She was incoherent and the liver was palpable 7 cm below the costal margin. The toe response was questionably extensor on the right. Laboratory data, including spinal fluid examination, were noncontributory. After

several days a left-sided flaccid paralysis developed which was believed to have resulted from cerebrovascular embolization (CVE).

The patient's father died at 36 years of age following a second myocardial infarction, the first of which occurred at age 30. He had been previously healthy. The diagnosis of myocardial infarction was verified at autopsy which showed marked coronary artery narrowing (Fig 1) and recent healing myocardial infarction as well as the scar of an old myocardial infarct. The central nervous system was not examined. The father's brother died at 39 years of age, also following a myocardial infarction. He had been well until a year before his death at which time diabetes mellitus was diagnosed and managed by dietary treatment alone. Physical and neurologic examination of his eight year old son gave normal results as did the ECG and chest x-ray examination.

The father's sister was said to have had unsteadiness and a tendency to fall, which she allegedly outgrew. She had two children, now 7 and 12 years of age, whose physical and neurologic examinations, ECG and chest x-ray films are normal.

A sister of the patient first showed weakness and waddling gait at 4½ years of age at which time she was hospitalized elsewhere. Ataxia, generalized weakness, and absent deep tendon reflexes were found. The toe response was flexor bilaterally. Mild lumbar scoliosis and spina bifida occulta at L-5 and S-1 were found. The urinary creatine-creatinine ratio was normal as was an electromyogram. A chest x-ray picture disclosed cardiac enlargement which suggested congenital heart disease. She died a few months later, three days after having been readmitted for abdominal pain and vomiting. At autopsy, marked idiopathic myocardial hypertrophy was found, together with bronchopneumonia and passive visceral congestion. No evidence of nervous or muscular disease was found by routine studies. The coronary arteries and their ostia were reported to be normal.

Physical examination of the patient at the time of admission at Maimonides Medical Center revealed an enlarged heart. The palpable impulse was maximal in the sixth left intercostal space in the anterior axillary line, and a left precordial heave was noted. S1 was normal, and S2 was normally split. A high-pitched systolic murmur of grade 2/6 intensity was heard at the apex. Kyphoscoliosis and questionable bilateral pes cavus were noted. Neurologic examination\* revealed a child who could neither stand nor walk. A flaccid left hemiparesis was accompanied by a decrease in muscle bulk in the left arm and leg. Deep tendon reflexes were absent in all extremities and plantar responses were extensor on the left and flexor on the right. Left lower facial weakness and slurred speech were noted. Nystagmus was absent. Sensory responses to pinprick, touch, vibration and position senses seemed intact, although testing for the latter was difficult. She could sit alone without support but was unable to stand erect on the right leg without assistance. She could not maintain balance on the hemiparetic left leg. No involuntary movements were seen. Affect was appropriate for her age. Intellect was estimated as dull normal.

Blood counts, urinalysis, serum electrolytes, spinal fluid, electroencephalogram, chromosome analysis, and serum proteins as well as electrophoretic pattern were all normal. LE cells were absent. Serum enzyme levels were SGOT 30 units, SGPT 60 units, SLDH 1,414 units, serum creatine phospho-

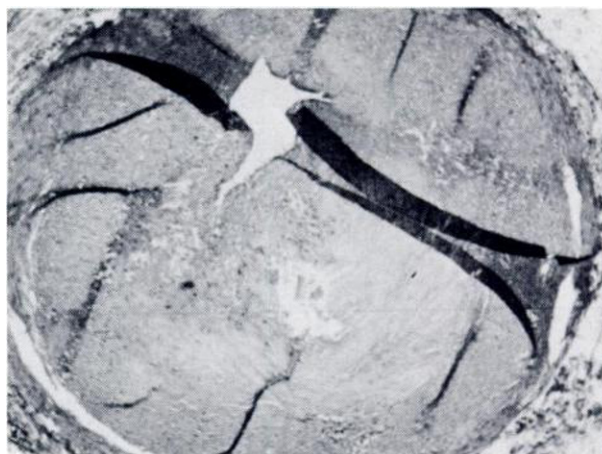

FIGURE 1. Photomicrograph of coronary artery of the patient's father ( $\times 2.5$ ). Severe, occlusive, intimal disease virtually obstructs the lumen. The lesion is mainly fibrous with some atheromatous material and smooth muscle cells.

kinase (CPK) 8 units, and aldolase 15 units. Total serum cholesterol was 321 mg percent and total lipids 597 mg percent. Serotonin and coproporphyrins were absent from the urine. There was no aminoaciduria. The electromyogram showed no myopathic or neuropathic potentials. Skull x-ray films were normal. The ECG and chest x-ray pictures were the same as previously described.

The suspicious family history, cardiomegaly, and the neurologic observations led to consideration of the possibility of Friedreich's ataxia. The autopsy findings of the deceased sister were reviewed, and special stains of the central nervous system specimens revealed marked demyelination of the posterior lateral columns and spinocerebellar tracts of the spinal cord, loss of myocardial fibers with round cell infiltration and marked hypertrophy of the heart.

Attacks of "abdominal pain," vomiting, and sweating often associated with tachycardia of 140 to 180 per minute occurred many times during the patient's hospitalization, with pain often referred to the left arm. Carotid sinus pressure and eyeball pressure failed to decrease the heart rate. Edrophonium chloride (Tensilon) test suggested sinus tachycardia.<sup>10</sup> Fever developed after one of these episodes at which time the WBC was 13,700, corrected sedimentation rate 17 mm per hour, serum amylase 102 units, SGOT 570 units, SGPT 370 units, and the SLDH 1,320 units, most of which was of cardiac origin (isoenzyme 5) (Fig 2). The ECG showed elevation of S-T segments in leads V<sub>1</sub>-V<sub>3</sub> consistent with an "injury pattern" of the anteroapical myocardial wall.

Anticoagulant therapy in the form of sodium warfarin (Dicumarol) was initiated because of the possibility of recent myocardial infarction, the history of CVE, and in view of her currently limited physical activity and decreased chance for self-injury.

An attempt to relieve the frequent episodes of tachycardia with prolonged administration of neostigmine in addition to digoxin, failed. Further, the elevated serum LDH persisted. The persistence and reproducibility of this high level of cardiac specific SLDH was verified on two different occasions by splitting a sample of blood drawn and sending it to two different laboratories. The results were similar and abnormally high.

Twelve months later she was readmitted because of a one day history of severe back pain referred to both arms, and persistent vomiting. ECG in the emergency room showed an "injury pattern" of the anterior wall (Fig 3), and she was

\*Dr. S. B. Brown currently Assistant Professor of Neurology and Pediatrics, University of Miami, Miami, Florida. Formerly Chief, Pediatric Neurology, Maimonides Medical Center.

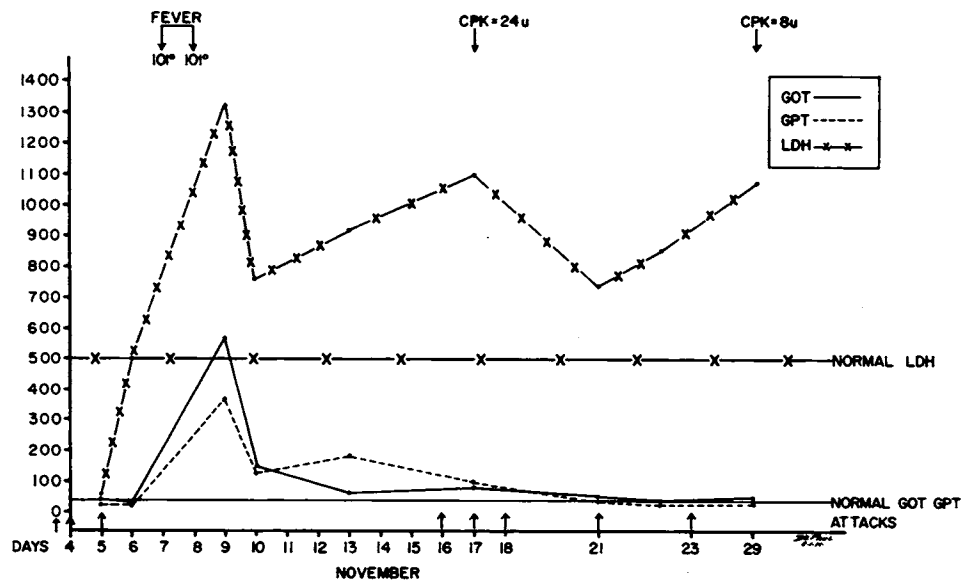


FIGURE 2. Serum LDH, GOT and GPT following severe attacks of abdominal pain and vomiting as observed from November 5 to November 29. The LDH remained elevated for the following 12 months, indicating possible continuing insult to the heart. GOT = glutamic-oxalacetic transaminase, GPT = glutamic-pyruvic transaminase, LDH = lactic dehydrogenase, CPK = creatine-phosphokinase. Initial levels of serum enzymes reported (10/5) were SGOT 44  $\mu$ , SGPT 20  $\mu$ , SLDH 56  $\mu$ . The next day (10/6) SGOT 39  $\mu$ , SGPT 24  $\mu$  and SLDH 500 $\mu$ . First significant elevations were noted on October ninth.

admitted with a diagnosis of a possible myocardial infarction. The prothrombin time was 36/12 seconds. The SGOT reached 240 units on the second day of hospitalization at which time the SGPT was 185 units and the CPK 30 units. The SLDH which was 550 units at the time of admission rose to 1160 units on the tenth day and remained abnormal throughout her hospitalization. Repeated abdominal pain occurred during her four weeks in the hospital until discharge. Neurologic findings were unchanged but bilateral pes cavus was now definite.

#### COMMENT

The clinical findings of the patient and the clinical as well as the autopsy findings on the patient's sister are consistent with the diagnosis of Friedreich's ataxia. Unfortunately, the upper central nervous system, particularly the cerebellum, was not available for pathologic review. Speculation is possible, therefore, that the family reported herein might have some other form of spinocerebellar degeneration. However, the diagnosis of a specific variant even when the complete nervous system can be examined is at times difficult, if not impossible. Cerebellar degeneration in various degrees often occurs in Friedreich's ataxia, and the final diagnosis depends upon the extent of neurologic degeneration in the various components of the central nervous system. The same could be said of the clinical manifestations, as formes frustes, and transitional forms do occur in many variations. At times even a prolonged follow-up may fail to define precisely the exact variant.

Neurologic manifestations preceded cardiac involvement in both sisters. The absence of extensor toe response as occurred in both sisters has been previously noted by others. This was the case in four of the patients reported by Boyer and co-workers.<sup>1</sup> In the patient reported by us, when the extensor toe response appeared it was evidently secondary to CVE.

Heart disease, however, is best known in Friedreich's ataxia. Hower<sup>11</sup> reported it to be present in 100 percent of adult patients. The same author was unable to find any reference to descriptions of cardiac pathology in conditions such as Roussy-Levy syndrome, familial spastic paraplegia and peroneal muscular atrophy—conditions closely allied to Friedreich's ataxia. Clinical as well as ECG abnormalities, however, have been previously reported in these diseases.<sup>12,13</sup>

The progressive cardiac damage in patients with Friedreich's ataxia has been attributed to various etiologic factors, including coronary artery disease and small vessel occlusion.<sup>1,7,14</sup> The heart muscle of the deceased sibling of our patient showed marked and diffuse myocardial hypertrophy with scattered areas of loss of myocardial fibers and minimal round cell infiltration, consistent with findings reportedly associated with Friedreich's ataxia.<sup>11</sup> The absence of small vessel occlusion in our autopsy material, could be accounted for by the small block available for review and by the fact that only about 10 percent of the arteries are

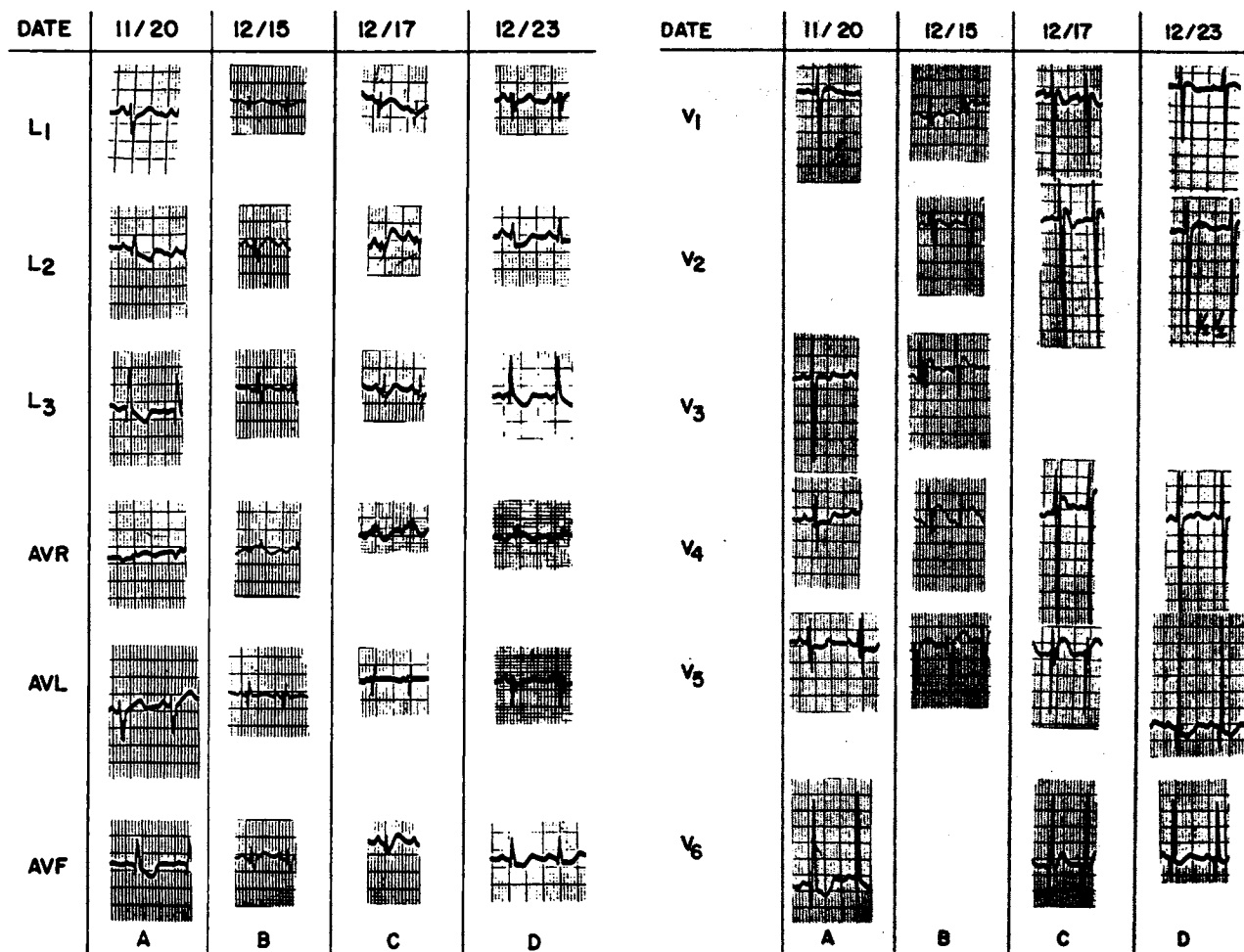


FIGURE 3. ECG three weeks prior to admission (A), in the emergency room on the day of admission (B), two days (C), and eight days (D) thereafter.

narrowed.<sup>11</sup>

Only one other case of Friedreich's ataxia has been reported in which the SGOT and SGPT were elevated.<sup>9</sup> Others have failed to find these enzymes abnormal.<sup>12</sup> The intermittent and episodic elevation of these enzymes as in our case may explain such apparently diverse observations.<sup>2</sup>

In our patient, the severity of the "abdominal pain" often extending to the left arm associated with increased sweating, was very similar to that seen in adults with severe anginal pains. The pain, sweating, fever, and enzyme elevation are all compatible with a severe myocardial insult, most probably a myocardial infarction. The absence of more specific ECG criteria such as the development of deep q waves and persistent reduction in QRS amplitude do not exclude this diagnosis, since ECG changes depend on size of area involved. In addition, localizing ECG changes may not appear following myocardial infarction if the tracing was previously abnormal.

The differential diagnosis in atypical cases may include such diverse possibilities as rheumatic fever,

chorea, cerebellar neoplasm, congenital heart disease and muscular dystrophy.<sup>6,7</sup> Indeed, the deceased sister of our patient was once diagnosed as having muscular dystrophy. Familial idiopathic myocardiopathy had been suggested until the central nervous system was studied with special staining techniques. The patient herself had suffered a CVE in the past, the neurologic consequences of which confused and delayed the correct diagnosis. CVE's are known to occur in association with Friedreich's ataxia.<sup>12</sup> This complication can occur either as a result of detachment of a mural thrombus secondary to a recent myocardial infarction or, more commonly in the pediatric age group, as a nonspecific complication in association with cardiac enlargement.

The father of our patient and his brother both died of myocardial infarction in their thirties. Their history of myocardial infarction at a young age is very similar to that reported by Roth,<sup>15</sup> Manning<sup>16</sup> and Tyrer and Sutherland.<sup>13</sup> This could be consistent as an isolated "cardiac" form of Friedreich's ataxia as has been suggested.<sup>12,15,16</sup> However, in

none of the previously reported "isolated myocardial forms" was the extent of coronary occlusion or its nature documented.

This report and the cases described by Nadas and co-authors<sup>7</sup> with anginal pain or coronary occlusion<sup>14</sup> in children and young adults suggest the possibility that a metabolic or toxic factor may cause or predispose to premature coronary occlusion in some patients with Friedreich's ataxia.

In our patient, total serum cholesterol level, once obtained, was elevated for age. No lipoprotein pattern is available of the patient, her father, or paternal uncle. It is therefore possible that the "toxic" or "metabolic factor" previously referred to in early reports,<sup>17</sup> might be hyperlipoproteinemia. This possibility has been neither documented nor excluded in earlier cases or in our own.

The development of diabetes mellitus (DM) in the paternal uncle one year prior to his death is intriguing. Diabetes mellitus occurred in nine of 113 (8 percent) of patients with Friedreich's ataxia studied by Hewer and Robinson<sup>18</sup> and in nine of 50 (18 percent) reported by Thoren.<sup>12</sup> These figures are well above the figures obtained from population surveys of the same age.<sup>18</sup> In a survey of 286 siblings of 112 probands with Friedreich's ataxia, 130 had Friedreich's ataxia and 10 (7.7 percent) had diabetes mellitus. Two of the siblings had diabetes mellitus with no evidence of Friedreich's ataxia. Podolsky and Sheremata<sup>19</sup> who collected 74 patients in 14 families with diabetes mellitus and Friedreich's ataxia, were unable to find this association in relatives other than sibs. The paternal uncle reported by us is the first patient other than a sibling to be reported with diabetes mellitus in a family with Friedreich's ataxia. His sudden death due to myocardial infarction is unlikely to be related to diabetes mellitus in view of its mildness and brief duration. Whether this association occurred by chance or is associated with the basic anomaly remains speculative.

#### REFERENCES

- 1 Boyer SH IV, Chisholm AW, McKusick VA: Cardiac aspects of Friedreich's ataxia. *Circulation* 25:493-505, 1962
- 2 Keith JD, Rowe RD, Vlad P: Heart Disease in Infancy and Childhood. Ed. 2. New York, The Macmillan Company, 1967
- 3 Moore AAD, Lambert EC: Cardiomyopathy associated with muscular and neuromuscular disease. In *Paediatric Cardiology* (Watson H, ed). St. Louis, CV Mosby Company, 1968, p 766
- 4 Wilson SAK: Neurology (Bruce AN, ed). New York, Hafner Publishing Company, Inc, 1970, vol 2, p 948-963
- 5 Giannelli A, Serra A, Bacciagaluppi M: An atypical hereditary spinocerebellar syndrome: a clinical and genetic study. *Acta Neurol Scand* 41:387-412, 1965
- 6 Thilenius OG, Grossman GJ: Friedreich's ataxia with heart disease in children. *Pediatrics* 27:246-254, 1961
- 7 Nadas AS, Alimurung MM, Sieracki LA: Cardiac manifestations of Friedreich's ataxia. *New Eng J Med* 244:239-244, 1951
- 8 Graham GR: Friedreich's disease. In *Ciba Foundation Symposium: Cardiomyopathies*, London, 1964 (Wolstenholme GEW, O'Connor M, ed). Boston, Little, Brown and Company, 1964, p 358
- 9 Gautier E, Richterich R: Valeur diagnostique d'activites enzymatiques du serum en pediatrie. II. Constance et specificite des anomalies enzymatiques. *Helv Paediat Acta* 18:32-79, 1963
- 10 Moss AJ, Aledort LM: Use of edrophonium (Tensilon) in the evaluation of supraventricular tachycardias. *Amer J Cardiol* 17:58-62, 1966
- 11 Hewer RL: The heart in Friedreich's ataxia. *Brit Heart J* 31:5-14, 1969
- 12 Thoren C: Cardiomyopathy in Friedreich's ataxia: with studies of cardiovascular and respiratory function. *Acta Paediat Scand* 53 Suppl 153:1-131, 1964
- 13 Tyrer JH, Sutherland JM: The primary spino-cerebellar atrophies and their associated defects, with a study of the foot deformity. *Brain* 84:289-300, 1961
- 14 James TN, Fisch C: Observations on the cardiovascular involvement in Friedreich's ataxia. *Amer Heart J* 66:164-175, 1963
- 15 Roth M: On a possible relationship between hereditary ataxia and peroneal muscular atrophy; with a critical review of the problems of "intermediate forms" in the degenerative disorders of the central nervous system. *Brain* 71:416-433, 1948
- 16 Manning GW: Cardiac manifestations in Friedreich's ataxia. *Amer Heart J* 39:799-816, 1950
- 17 Russell DS: Myocarditis in Friedreich's ataxia. *J Path Bact* 58:739-748, 1946
- 18 Hewer RL, Robinson N: Diabetes mellitus in Friedreich's ataxia. *J Neurol Neurosurg Psychiat* n.s. 31:226-231, 1968
- 19 Podolsky S, Sheremata WA: Insulin-dependent diabetes mellitus and Friedreich's ataxia in siblings. *Metabolism* 19:555-561, 1970

#### Editorial Expression

The occurrence of cardiopathy in Friedreich's ataxia is well established, and could result from a genetically determined biochemical abnormality affecting both the heart and the central nervous system. This excellent paper provokes speculation concerning a possible relationship to the hyper-

lipidemias or diabetes, both familial disorders producing early diffuse coronary arterial disease, and points to a need for continuing study in this context.

A. A. Douglas Moore  
Norfolk