

ACUTE POSTERIOR MULTIFOCAL PLACOID PIGMENT EPITHELIOPATHY ASSOCIATED WITH CEREBRAL VASCULITIS AND HOMONYMOUS HEMIANOPIA

JESSE SIGELMAN, M.D., MYLES BEHRENS, M.D., AND SADEK HILAL, M.D.

New York, New York

The ophthalmic manifestations of acute posterior multifocal placoid pigment epitheliopathy have been established by Gass.¹ Both the original case descriptions and subsequent reports have shown an association of this disease with a variety of ophthalmic and systemic manifestations including a significant association with central nervous system disease. We describe herein a case of acute posterior multifocal placoid pigment epitheliopathy associated with cerebral vasculitis and probable occipital infarction. These findings add further evidence to the concept of a common underlying vascular inflammatory basis for the ophthalmic and systemic manifestations in patients with acute posterior multifocal placoid pigment epitheliopathy. To the best of our knowledge, this is the first reported case with such concomitant visual defects.

CASE REPORT

On Aug. 5, 1977, an 18-year-old man awoke with bilateral blurred vision and retrobulbar pain with severe headache. The night before he had drunk large amounts of bourbon and beer, vomited, and slept. He had a family history of migraine headaches and a five-day long episode of headache and vomiting in April 1977 while taking parenteral antibiotics for chronic bronchitis.

On Aug. 9, 1977, he was hospitalized because of blurred vision and a suggestion of a left homony-

mous hemianopia. Results of laboratory tests including a complete blood count and urinalysis were normal. The cerebrospinal fluid had a normal glucose level and negative culture but a protein level of 55 mg/100 ml with a red blood cell count of 90/mm³. A computed axial tomography scan was initially considered negative, but then suggested a right occipital abnormality and the electroencephalogram showed slow alpha rhythm in the right occipital area. On Aug. 11, 1977, corrected visual acuity was R.E.: 6/21 (20/70) and L.E.: 6/6 (20/20). Visual fields then showed a central scotoma in the right eye without obvious homonymous hemianopia. Pigmentary disturbance of the right macula was noted.

On Aug. 16, 1977, visual acuity was R.E.: 6/21 (20/70) and L.E.: 6/6 (20/20). Color vision was normal in each eye as measured by the AO H-R-R plates. Visual field (Fig. 1) and Amsler grid testing showed a central scotoma in the right eye that was densest nasally and a temporal central scotoma in the left eye that extended slightly across the midline. Inferior left homonymous hemianopic depression was evident, which was more marked in the right eye.

Ophthalmoscopic examination of the right eye showed a central pigmentary lesion with cream-colored placoid lesions (Fig. 2). The posterior pole of the left eye showed no placoid lesions or pigmentary disturbance. Peripheral flat pigmentary lesions without fresh placoid lesions were present in the periphery of each eye. These were more marked in the right eye (Fig. 3). Fluorescein angiography (Fig. 4) showed blocking defects at the areas of the posterior pole pigmentary disturbance and placoid lesions in the right eye with late staining and slight leakage at the placoid lesion sites (Fig. 5).

An electroencephalogram showed an abnormality in the right occipital region and right occipital infarction was suggested by dynamic technetium scan. A computed axial tomographic scan also suggested probable right occipital infarction. Transfemoral selective cerebral angiography showed multiple disseminated areas of focal narrowing compatible with vasculitis (Fig. 6). Lumbar puncture again showed a high protein level (52 mg/100 ml with IgG of 3.3 mg/100 ml with five mononuclear cells and a normal glucose level. Other laboratory results were normal including complete blood cell count, erythrocyte sedimentation rate, latex fixation, antistreptolysin O titer, cold agglutinins, lupus erythematosus preparation, antinuclear antibody, and anti-DNA antibody.

During the eight days of hospitalization, visual

From the E. S. Harkness Eye Institute, Columbia-Presbyterian Medical Center, New York, New York (Drs. Sigelman and Behrens); and the Department of Radiology and the New York Neurological Institute, Columbia-Presbyterian Medical Center, New York, New York (Dr. Hilal). Dr. Sigelman was supported in part by the Glorney-Raisbeck Foundation of the New York Academy of Medicine.

Reprint requests to Jesse Sigelman, M.D., 635 W. 165th St., New York, NY 10032.

3W/1000

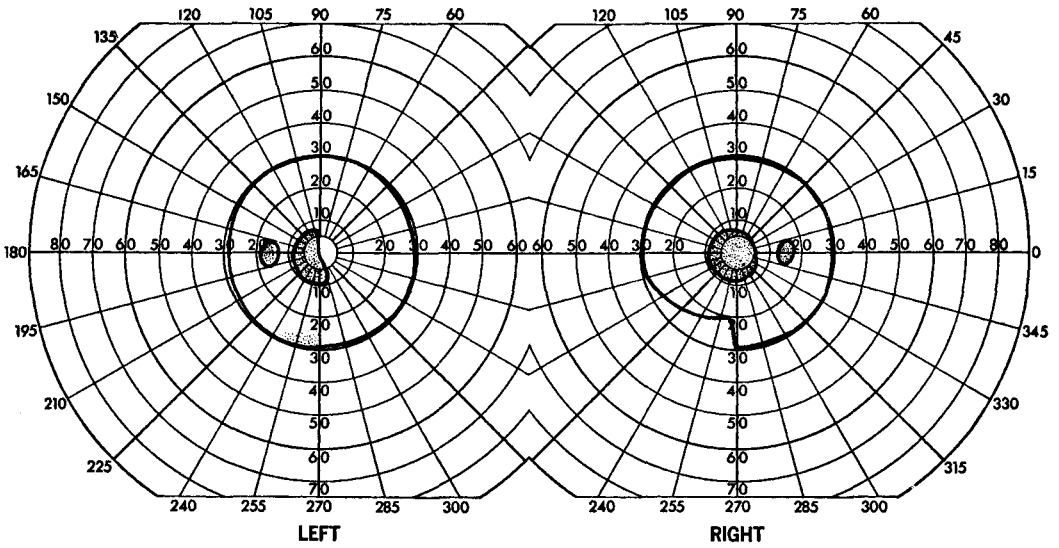


Fig. 1 (Sigelman, Behrens, and Hilal). The central scotoma was densest nasally in the right eye. The temporal central scotoma of the left eye extended slightly across midline. Inferior homonymous hemianopic depression was more marked in the right eye.

acuity in the right eye improved to 6/12 (20/40) with progression of pigmentation (Fig. 7). The left eye maintained visual acuity of 6/6 (20/20) despite development of small placoid lesions inferior and superotemporal to the macula (Fig. 8). The severity of the

headache gradually decreased by the time of discharge on Aug. 26, 1978.

By Sept. 30, 1978, symptoms were essentially gone and examination then as well as on March 9, 1978, showed visual acuity of R.E.: 6/7.5 (20/25) and L.E.: 6/6 (20/20). Visual fields showed a persistent left homonymous hemianopic scotoma. The right

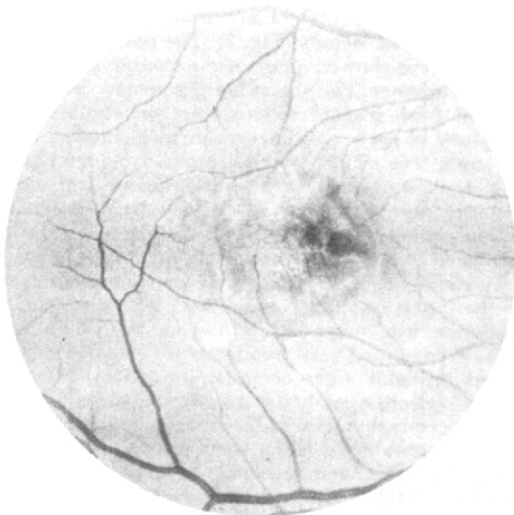

Fig. 2 (Sigelman, Behrens, and Hilal). The pigment epithelium of the posterior pole showed uneven thickness and pigmentation with a yellow-white coloration of the borders of the lesion and of the satellite lesion. The overlying retina and vitreous were uninvolved.

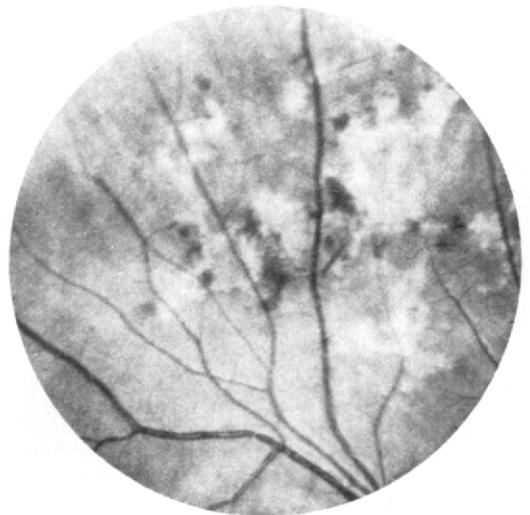

Fig. 3 (Sigelman, Behrens, and Hilal). Flat pigmented lesion without fresh pigment epithelial swelling as seen in both peripheries.

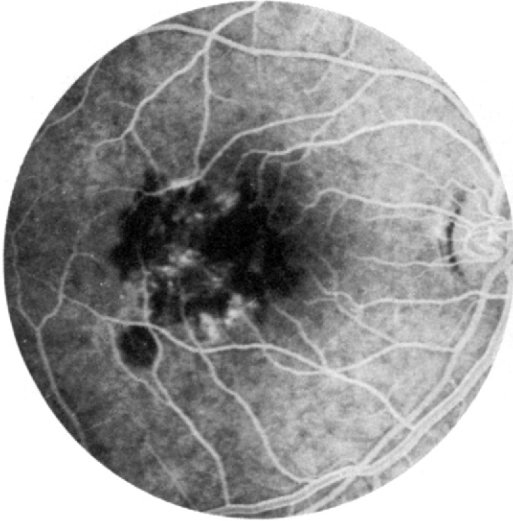


Fig. 4 (Sigelman, Behrens, and Hilal). Arteriovenous phase fluorescein angiogram showing blocking defects by both the original central lesion and the later onset satellite lesion.

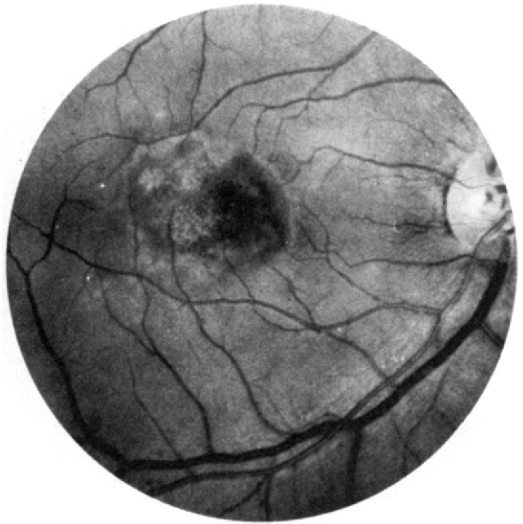

Fig. 5 (Sigelman, Behrens, and Hilal). Late angiogram shows staining and slight leakage of the central and satellite lesions.

macula showed a diffuse but mottled pigment epithelial hypertrophy and pigment scatter. The left macula had no visible lesion. The peripheral retinal lesions were unchanged.

DISCUSSION

The sudden appearance of cream-colored placoid lesions in the posterior pole

of one eye in a young adult followed by development of similar lesions in the posterior pole of the opposite eye characterizes acute posterior multifocal placoid pigment epitheliopathy.¹⁻⁴ Positive scotomas develop corresponding to the

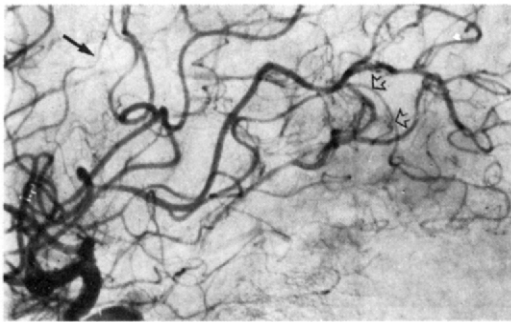


Fig. 6 (Sigelman, Behrens, and Hilal). Magnification, lateral view, of a selective right internal carotid angiogram with subtraction. Multiple segments of focal narrowing are evident. The most pronounced change is seen in the middle cerebral branch originating in the center of the sylvian group (black solid arrow). Another segment of narrowing is seen in the posterior temporal branch supplying the temporal occipital region (double hollow arrows). Close scrutiny of the angiogram shows multiple areas of focal narrowing disseminated throughout. The changes are compatible with those seen in vasculitis.

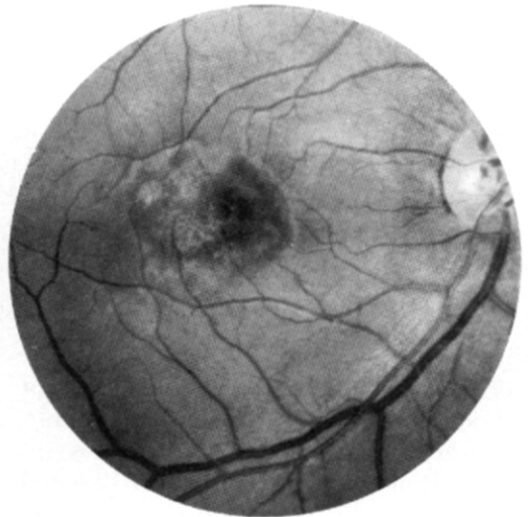

Fig. 7 (Sigelman, Behrens, and Hilal). Eight days after their appearance as shown in Figure 2, both the central and satellite lesions showed evolving pigment disturbance. Visual acuity improved during the pigmentation.

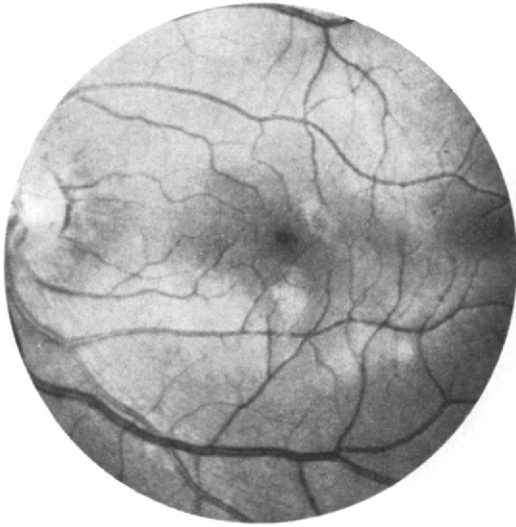

Fig. 8 (Sigelman, Behrens, and Hilal). Yellow-white placoid lesions of the pigment epithelium developed in the posterior pole of the left eye one week after the discovery of the peripheral lesions in both eyes and the macular lesions in the right eye.

points of the placoid lesions. Visual acuity decreases if a lesion occurs at the fovea. The course of acute posterior multifocal placoid pigment epitheliopathy is rapid, both with acute onset, in hours, and resolution over a period of weeks. Visual impairment and positive scotomas resolve more slowly than does the ophthalmoscopic appearance of the lesions whose pigment scattering may appear stable months before final resolution of visual acuity.

The acute placoid lesions, on contact lens examination, are deeper than the retina with the lesions always involving the pigment epithelium. The overlying vitreous, retina, retinal vessels, and optic nerve characteristically are normal except for occasional cases with evidence of retinal arteritis and secondary vitreous inflammation. Although rare, the associated occurrence of papillitis,^{3,5-7} episcleritis⁸ and marginal corneal thinning⁸ have been interpreted to be additional manifestations of an underlying vasculitis as the

basis of acute posterior multifocal placoid pigment epitheliopathy.

The characteristic fluorescein angiographic pattern in acute posterior multifocal placoid pigment epitheliopathy consists of an early blocking defect at the site of the lesions with late staining and occasional late leakage.^{1,9} This pattern has been interpreted as the result of swelling of the pigment epithelial cells with occasional breakdown of their tight junctions at the lesion sites. An angiographic finding of Deutman and Lion¹⁰ has suggested that localized blockage of choriocapillaris perfusion may be the primary cause of the problem. In one case, Deutman and Lion¹⁰ found absence of choriocapillaris perfusion at the site of a placoid lesion where choroidal circulation could be seen. It had been thought previously that the lack of visibility of choroidal circulation at the site of the lesions was caused by swelling of the overlying pigment epithelial cells.

Our case was the second to show an association between acute posterior multifocal placoid pigment epitheliopathy and cerebral vasculitis.⁷ The only ocular finding in our case that deviated from the classic description of acute posterior multifocal placoid pigment epitheliopathy was the homonymous hemianopia apparently the result of cerebral vasculitis with occipital lobe infarction. The combined visual field defects of these two diseases produced a complex visual field defect. The existence of cerebral vasculitis with occlusion was documented by cerebral arteriography with occipital lobe infarction suggested by a computed axial tomographic scan. The existence of central nervous system inflammation was further suggested by the high cerebrospinal fluid protein level and slight pleiocytosis.

Review of 60 published case reports of acute posterior multifocal placoid pig-

TABLE
 ACCOMPANYING DISORDERS IN 60 REPORTED CASES OF ACUTE POSTERIOR
 MULTIFOCAL PLACOID PIGMENT EPITHELIOPATHY

Disorder	No. of Cases	Authors
Neurologic		
Headache three to four days before onset of acute posterior multifocal placoid pigment epitheliopathy	12	Ryan and Maumenee ² Holt, Regan, and Trempe ⁷
Headache simultaneous with onset of acute posterior multifocal placoid pigment epitheliopathy	6	Gass ¹ Ryan and Maumenee ² Holt, Regan, and Trempe ⁷ Reuscher ¹⁴ Bullock, Thomas, and Fletechur ¹⁵
Transient expressive aphasia with cerebral vasculitis	1	Holt, Regan, and Trempe ⁷
Abnormal electroencephalogram	1	Savino and associates ³
Cerebrospinal fluid pleiocytosis		Holt, Regan, and Trempe ⁷
Cases with cerebrospinal fluid evaluation	5	Kirkman, Ffytche, and Sanders ⁵ Fishman, Baskin, and Jednock ¹⁶
Cases with cerebrospinal fluid pleiocytosis or elevated protein	3	
Systemic		
Erythema multiforme	1	Van Buskirk, Lessel, and Friedman ¹¹
Thyroiditis	1	Jacklin ⁸
Ocular		
Papillitis	6	Savino and associates ³ Kirkman, Ffytche, and Sanders ⁵ Jenkins, Savino, and Pilkerton ⁶ Jacklin ⁶
Posterior uveitis	4	Savino and associates ³ Kirkman, Ffytche, and Sanders ⁵ Jacklin ⁸
Retinal vasculitis with serous retinal detachment	1	Reuscher ¹⁴
Serous retinal detachment without arteritis	2	Bird and Hamilton ¹²
Iridocyclitis	2	Anneseley, Tomer, and Shields ⁴ Deutman, Oesterhuis, and Bven-Tan ⁹
Peripheral corneal thinning	1	Jacklin ⁸
Episcleritis	2	Anneseley, Tomer, and Shields ⁴ Holt, Regan, and Trempe ⁷

ment epitheliopathy¹⁻¹⁶ suggests a high rate of concomitant central nervous system involvement (Table). The high incidence of both ocular and systemic associations with acute posterior multifocal placoid pigment epitheliopathy may indicate that it is a specific ocular manifestation of a systemic vascular inflammatory disease. The association with an influenza type of syndrome in some patients before development of acute posterior

multifocal placoid pigment epitheliopathy has suggested a possible viral cause.

The differential diagnosis of acute posterior multifocal placoid pigment epitheliopathy should include the maculopathy of Dawson's subacute sclerosing panencephalitis,^{17,18} serous or hemorrhagic detachments of the pigment epithelium,¹⁹ inactive foci of presumed ocular histoplasmosis,²⁰ retinal pigment epitheliitis,²¹

Best's vitellieruptive degeneration,²² and acute herpes simplex retinitis.²³

SUMMARY

An 18-year-old man developed acute posterior multifocal placoid pigment epitheliopathy and homonymous hemianopia. Cerebral angiography showed cerebral vasculitis probably with occipital infarction. To the best of our knowledge, this is the first reported case with such concomitant visual defects. Other published reports suggest that such cerebral vasculitis may not be unusual in acute posterior multifocal placoid pigment epitheliopathy.

REFERENCES

- Gass, J. D. M.: Acute posterior multifocal placoid pigment epitheliopathy. *Arch. Ophthalmol.* 80:177, 1968.
- Ryan, S. J., and Maumenee, A. E.: Acute posterior multifocal placoid pigment epitheliopathy. *Am. J. Ophthalmol.* 74:1066, 1972.
- Savino, P. J., Weinberg, R. J., Yassin, J. G., and Pilkerton, A. R.: Diverse manifestations of acute posterior multifocal placoid pigment epitheliopathy. *Am. J. Ophthalmol.* 77:659, 1974.
- Anneseley, W. H., Tomer, T. L., and Shields, J. A.: Multifocal placoid pigment epitheliopathy. *Am. J. Ophthalmol.* 76:511, 1973.
- Kirkman, T., Ffytche, T., and Sanders, M.: Placoid pigment epitheliopathy with retinal vasculitis and papillitis. *Br. J. Ophthalmol.* 56:875, 1972.
- Jenkins, R. B., Savino, P. J., and Pilkerton, A. R.: Placoid pigment epitheliopathy with swelling of the optic discs. *Arch. Neurol.* 29:204, 1973.
- Jacklin, H. N.: Acute posterior multifocal placoid pigment epitheliopathy and thyroiditis. *Arch. Ophthalmol.* 95:995, 1977.
- Holt, W. S., Regan, C. D. J., and Trempe, C.: Acute posterior multifocal placoid pigment epitheliopathy. *Am. J. Ophthalmol.* 81:403, 1976.
- Deutman, A. F., Oesterhuis, J. A., and Bven-Tan, T. N.: Acute posterior multifocal placoid pigment epitheliopathy. *Br. J. Ophthalmol.* 56:863, 1972.
- Deutman, A., and Lion, F.: Choriocapillaris nonperfusion in acute multifocal placoid pigment epitheliopathy. *Am. J. Ophthalmol.* 84:652, 1977.
- Van Buskirk, E. B., Lessel, S., and Friedman, E.: Pigment epitheliopathy and erythema nodosum. *Arch. Ophthalmol.* 85:369, 1971.
- Bird, A. C., and Hamilton, A. M.: Placoid pigment epitheliopathy presenting with bilateral serous retinal detachments. *Br. J. Ophthalmol.* 56:881, 1972.
- Laatikainen, L., and Erkkila, H.: Clinical and fluorescein angiographic findings of acute multifocal central subretinal inflammation. *Acta Ophthalmol.* 51:645, 1973.
- Reuscher, A.: Zur pathogenese der segenanten akuten hinteren multifokalex placeiden pigment epitheliopathy. *Klin. Monatsbl. Augenheilkd.* 165:775, 1974.
- Bullock, J. D., Thomas, E. R., and Fletechur, R. L.: Cerebrospinal fluid abnormalities in acute posterior multifocal placoid pigment epitheliopathy. Presented at the Association for Research in Vision and Ophthalmology Central Section meeting, Ann Arbor, Michigan, Oct. 15, 1975.
- Fishman, G. A., Baskin, M., and Jednock, N.: Spinal fluid pleocytosis in acute posterior placoid pigment epitheliopathy. *Ann. Ophthalmol.* 9:33, 1977.
- Nelsen, D. A., Weiner, A., Yanoff, M., and de Peralta, J.: Retinal lesions in SSPE. *Arch. Ophthalmol.* 84:613, 1970.
- La Piana, F., Tso, M. O., and Jenis, E. H.: The retinal lesions of subacute sclerosing panencephalitis. *Ann. Ophthalmol.* 6:603, 1974.
- Maumenee, A. E., and Emery, J. M.: An anatomic classification of diseases of the macula. *Am. J. Ophthalmol.* 74:594, 1972.
- Schlaegel, T. F., Jr., Weber, J. C., Helveston, E., and Kenney, D.: Presumed histoplasmic chorioiditis. *Am. J. Ophthalmol.* 63:919, 1967.
- Krill, A. E., and Deutman, A. F.: Acute retinal pigment epitheliitis. *Am. J. Ophthalmol.* 74:193, 1972.
- Falls, H. F.: The polymorphous manifestations of Best's disease. *Trans. Am. Ophthalmol. Soc.* 67:265, 1969.
- Bloom, J. N., Katz, J. I., and Kaufman, H. E.: Herpes simplex retinitis and encephalitis in an adult. *Arch. Ophthalmol.* 95:1798, 1977.