

THE CONTRIBUTION OF THE 'SECOND' VISUAL SYSTEM TO DIRECTED VISUAL ATTENTION IN MAN

by J. ZIHL and D. VON CRAMON

(From the Max-Planck-Institut für Psychiatrie, D-8000 München, Kraepelinstrasse 10, FRG)

INTRODUCTION

IN a recent paper, Mountcastle (1978) discusses the dominant role of the posterior parietal cortex in the control of visual attention. Electrophysiological observations suggest that the parietal lobe contains a mechanism for shifting the focus of visual attention to events of interest, thus 'executes a matching function' between objects of significance in the environment and the internal state of the organism (Hyvärinen and Poränen, 1974; Lynch, Mountcastle, Talbot and Yin, 1977; Robinson, Goldberg and Stanton, 1978).

Some authors have found it useful to distinguish between the 'first' and 'second' visual systems, the former depending mainly on the geniculostriate pathway, and the latter on the colliculus-pulvinar-parietal lobe pathway (Schneider, 1969; Ingle, 1967; Trevarthen, 1968). The first system is said to be concerned with the identification of objects whereas the second is concerned with the detection of events, their location in space, and the control of orientating responses to them for subsequent identification by the first system. Consistent with the inclusion of the parietal lobe in the second system are the clinical findings that patients with lesions of the parietal lobe are, in general, inattentive to the contralateral visual field, for example, they find difficulty in looking towards targets presented there, and are either slow or unable to shift their gaze from object to object within this area (Patterson and Zangwill, 1944; Hécaen and de Ajuriaguerra, 1954; Oxbury, Campbell and Oxbury, 1974). Removal of the posterior parietal cortex in monkeys produces comparable attentional disorders (Bates and Ettlinger, 1960; Ettlinger and Kalsbeck, 1962; Mendoza and Thomas, 1975), and similar symptoms of 'neglect' for the contralateral half of the visual field have also been observed in monkeys after collicular (Denny-Brown, 1962; Wurtz and Goldberg, 1972; Keating, 1974, 1976; Butter, Weinstein, Bender and Gross, 1978) and pulvinar lesions (Ungerleider and Christensen, 1977). The superior colliculus and the n. pulvinar, therefore, may be important components of the central neural

mechanism responsible for the detection and localization of events in visual space. In contrast, 'blinded' monkeys (with bilateral striate cortex ablations), can still detect and localize stimuli with a high degree of accuracy as judged by their reaching towards briefly presented visual stimuli randomly located in their visual fields (Weiskrantz, Cowey and Passingham, 1977). Analogous results were obtained in patients with a hemianopia due to damage to the geniculostriate visual pathways; such patients are able to make accurate saccadic eye movements to targets presented at different positions within their blind hemifield (Pöppel, Held and Frost, 1973; Weiskrantz, Warrington, Sanders and Marshall, 1974; Perenin and Jeannerod, 1975; Zihl, 1979). Thus, despite damage to the 'first' (geniculostriate) visual system and a consequent loss of sight, detection and localization of objects in visual space is surprisingly not impaired.

Recently we had the opportunity to test a patient with a suspected lesion incorporating the left pulvinar. The major aim of this study was to determine the attentional defects accompanying this supposed pulvinar lesion. The observed 'neglect' for the contralateral visual hemifield and an impairment of the ability to shift the gaze towards light stimuli presented within it suggest, in agreement with the above observations, that the n. pulvinar could be part of a subcortical system concerned with selective visual attention.

CASE HISTORY

The 63-year old right-handed patient suffered for more than 15 years from a severe diabetes mellitus. She refused treatment of the diabetes mellitus with insulin; the blood sugar level, therefore, had never been regulated satisfactorily. She was known to have had high blood pressure for years but it was untreated. In April 1977, total aphasia developed within several hours. In August and September 1978, psychomotor seizures, dysphasic automatisms and autonomous symptoms were observed, which have increased in number since January 1978.

We examined the patient in July 1978. We found a patient (62 kg/156 cm) with a blood pressure of 150/100 mmHg on both arms. Besides congestion of the liver, moderate signs of venous congestion and cardiœdema were found. There was marked hyperlipœmia. Hypertensive changes of the retinal vessels were present. The patellar reflexes were abolished, the ankle reflexes diminished. There was marked atrophy of the left quadriceps muscle.

Neuropsychological examination showed a predominant anomic (amnesic) aphasia. In the Sclar Aphasia test, the following deficits were found:

I	Auditory Decoding	18 per cent
II	Visual Decoding	44 per cent
III	Oral Encoding	26 per cent
IV	Graphic Encoding	40 per cent

Conversational speech occasionally was dysprosodic and poorly articulated. The aphasic disorder was accompanied by an aphasic calculation disturbance and alexia with agraphia. A slight constructional apraxia, but no visual spatial disorientation could be demonstrated (fig. 1). (For visual functions *see below*). Simultaneous application of two cutaneous stimuli at symmetrical points of the body revealed no sensory neglect or extinction of sensation. Her performance in a vigilance task (sustained attention) was somewhat below average. Short- and long-term memory performance (ignoring the aphasic disturbance) was only moderately reduced.

A pathological EEG with a δ -focus in the left temporal lobe but without epileptic potentials was repeatedly recorded. The ECG indicated signs of coronary sclerosis. In the EMG the velocity of nerve conduction was reduced in both peroneal nerves, a finding consistent with the clinical assumption of a diabetic neuropathy.

Left internal carotid angiogram (magnification view) showed filling defects in the left common carotid bifurcation, the left carotid siphon and in several branches of the middle cerebral artery. A relevant narrowing of the arterial lumen was seen in the peripheral branches of the left middle cerebral artery only (e.g. in the angular artery). The temporal and temporo-occipital arteries of the middle cerebral artery were not opacified. The patient refused further angiographic investigations; therefore no information about the left posterior cerebral artery and its main branches is available.

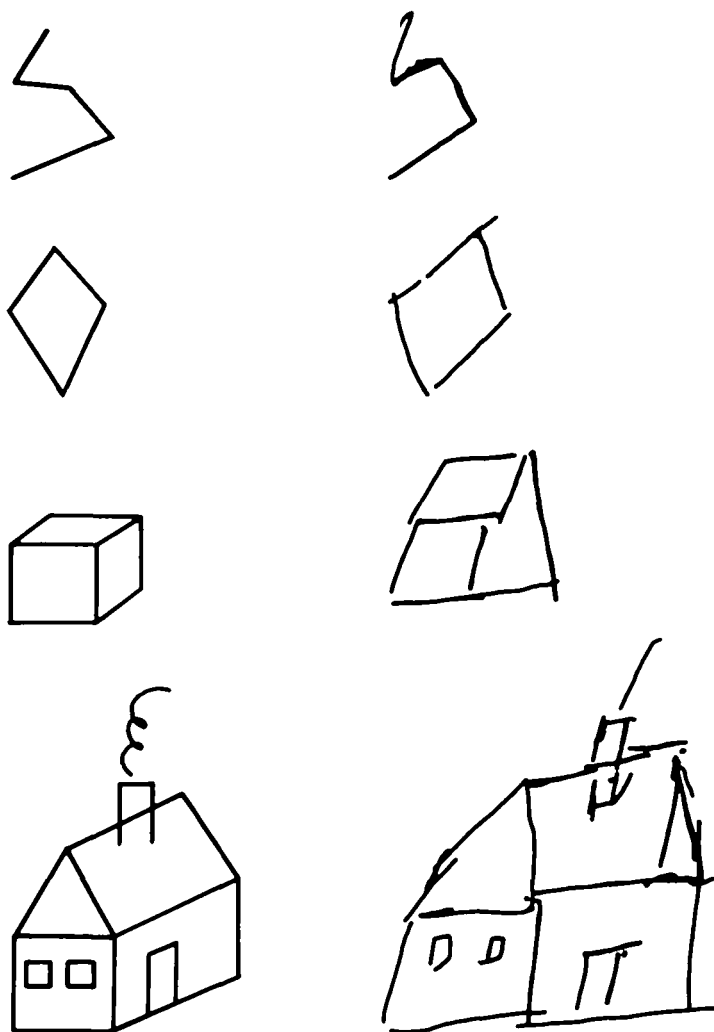


FIG. 1. Model (*left*) and copy (*right*) of a zigzag, a diamond, a cube and a house.

The CT scan (EMI CT 1010) showed an extensive, discontinuous area of low density in the cortex and white matter of the left temporal and parietal lobe (figs. 2A, D). Corresponding segments of the lateral ventricle were markedly enlarged. A small lesion of considerably lower density was found in the left hippocampal formation (fig. 2A). A likewise circumscribed lesion affected the left posterior thalamus, including the n. pulvinar (figs. 2B, C).

In addition, both insular cisterns were moderately widened.

Interpretation of the Main Clinical Findings

The patient suffered from diabetes mellitus with hyperlipæmia and arterial hypertension for a long time without adequate treatment. This increased the speed of development of a generalized atherosclerosis, which could be demonstrated equally in retinal and intracerebral arteries.

The CT scan showed an extensive (ischæmic or embolic?) infarction in the territory of the left middle cerebral artery. The infarcted area affected also the border area between middle and posterior cerebral arteries (*Grenzzoneninfarkt*). The softening in the left hippocampal formation and in the left posterior thalamus indicates the participation of at least some branches of the posterior cerebral artery. The thalamic lesion might be attributed to the territory of the lateral posterior choroid arteries. The branches to the hippocampal formation arise from the ambient segment of the posterior cerebral artery near the origin of the lateral choroidal arteries. The psychomotor seizures might be caused by a hippocampal lesion.

The neuropsychological syndrome seems plausible in the context of the temporo-parietal lesion of the dominant hemisphere if the angular gyrus is included in the infarcted area.

METHODS AND RESULTS

(1) *Visual Field Testing*

The monocular and binocular visual fields were tested by dynamic and static perimetry using the Tübingen perimeter (Sloan, 1971). For *dynamic perimetry*, the target had a diameter of 116 min visual angle; its luminance was 32 cd/m². The target was moved with a velocity of about 1 deg s⁻¹ from the periphery towards the centre of the visual field. The patient had to push a button whenever she detected the target. *Static perimetry* was performed along the horizontal axis; target diameter was 116' and 27' respectively, presentation time was 0.5 s. Target luminance was chosen well above threshold and was then decreased in steps of 0.1 log units. The luminance of the last seen target was defined as threshold when three consecutive targets of 0.1 log units below the threshold were not detected by the patient. *Critical flicker fusion (CFF)* was determined by measuring CFF-fields for 10, 15, 20 and 25 Hz (target: 116' diameter; 32 cd/m²). The flickering target was moved with a velocity of about 1 deg s⁻¹ from the periphery towards the centre of the visual field. The patient was instructed to push a button whenever she could see the target flickering. The boundaries of the CFF-fields were determined for sixteen meridians; the sequence of measurements along the different meridians was randomized. In addition, CFF was measured randomly for static positions at 40, 30, 25, 20, 15, 10 and 5 degrees eccentricity along the horizontal axis in both visual half-fields. A descending method of limits was used to determine CFF at the different eccentricities. The patient had to push a button when she detected the target flickering.

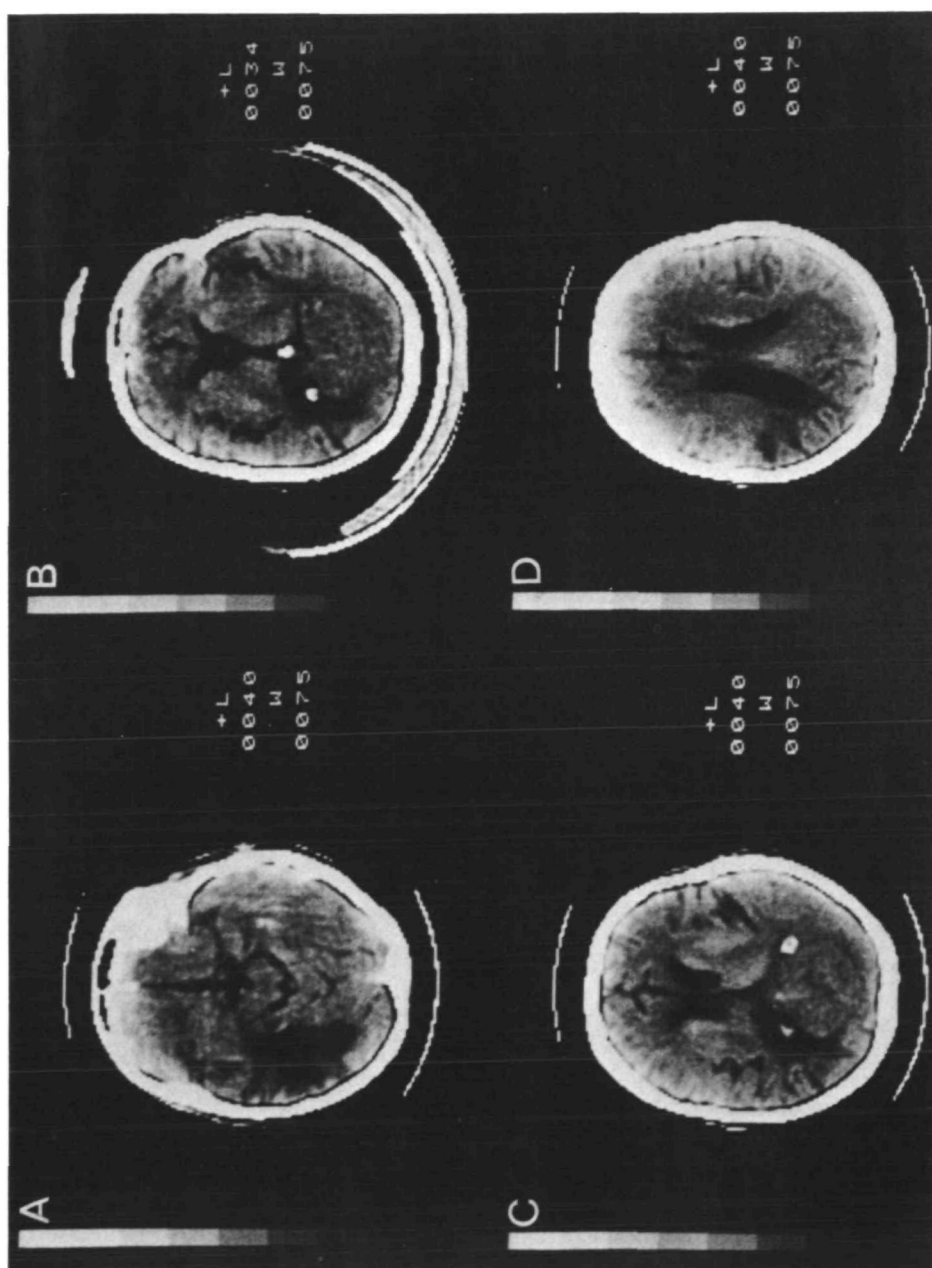


FIG. 2. Results of CT scans obtained at four different levels. For details see text.

In all conditions, the patient fixated a red spot of light (diameter 30 ft) in the centre of the homogeneously illuminated hemisphere of the perimeter. Eye position was monitored by a telescope. Background luminance was 3.2 cd/m^2 .

Monocular and binocular visual fields were normal; there was no evidence of a retinal or geniculate lesion. Fig. 3 shows the boundaries of the intact binocular visual field. Contrast sensitivity (as defined by the light difference threshold along the horizontal axis) was not reduced in the right visual half-field (that is, contralateral to the pulvinar lesion). In addition, the CFF-fields are shown for the different flickering rates. The CFF-fields for 10 and 25 Hz did not differ significantly in their extent in the left and right visual half-field. In contrast, the CFF-fields for 15 and 20 Hz were clearly contracted in the right as compared to the left hemifield. This inferiority in CFF in the right visual half-field was also found for static positions along the horizontal axis (Table 1). Up to 15 degrees eccentricity, there was no difference between the two visual half-fields; beyond 15 degrees the reduction in CFF increased as a function of eccentricity in the right hemifield (i.e. contralateral to the pulvinar lesion).

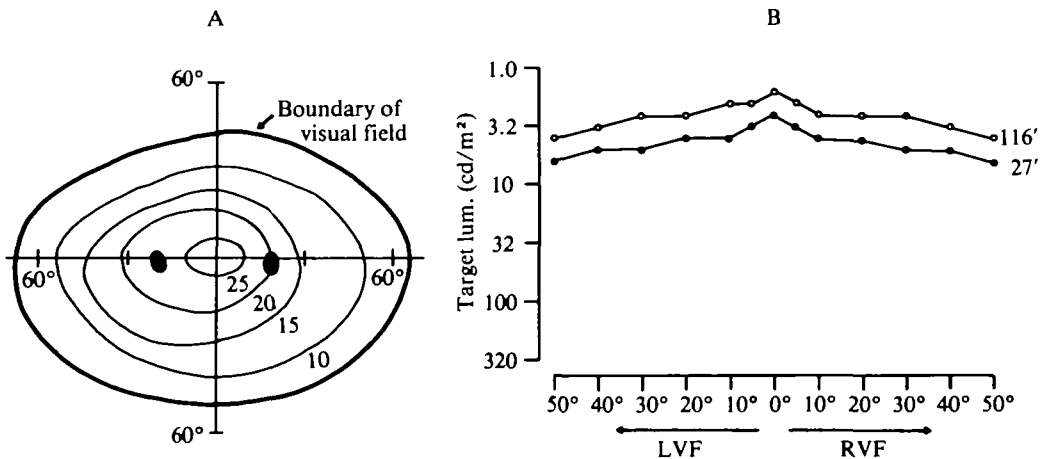


FIG. 3. A, binocular visual field and B, light-difference threshold along the horizontal meridian (LVF = left visual field, RVF = right visual field). In A, boundaries for targets with different flickering rates (10, 15, 20, 25 Hz) are also shown. In B, two different targets (116 min, 27 min) were used to determine contrast-sensitivity.

(2) Adaptation and Resetting in the Two Hemifields

Recently it has been shown that the superior colliculus can modulate contrast sensitivity (as judged by increment threshold for light) in a retinotopically organized way. This modulation of contrast threshold was studied using an adaptation technique, that is, by repetitive determination of the increment threshold in a given part in the left or right visual hemifield. In order to test the function of the retino-tectal pathway in our patient, the same procedure was employed as in patients with a

hemianopia (Singer, Zihl and Pöppel, 1977) and in a patient with a congenital malformation of one superior colliculus (Zihl and von Cramon, 1978; 1979). The Tübingen perimeter was used for this experiment. The patient fixated a red spot of light (30' diameter). Stationary targets of 116' diameter were presented for 0.5 s. A psychophysical descending method of limits was used to determine the threshold. Stimulus intensity steps differed by 0.1 log unit. The luminance of the target was changed on every presentation (trial); between 6 and 8 suprathreshold stimuli were presented for each threshold measurement. The intertrial-interval varied between 1 and 2 s; the time between the end of one threshold determination and the beginning of the next threshold measurement was about 5 s. The criterion for the threshold was the same as in static perimetry (*see above*). In the first part of the

TABLE 1. CRITICAL FLICKER FUSION (TWO MEASUREMENTS) IN HZ AS A FUNCTION OF ECCENTRICITY FOR THE LEFT AND RIGHT VISUAL HALF-FIELD

<i>Eccentricity</i>	<i>Left visual field</i>	<i>Right visual field</i>	<i>Difference</i>
5°	26/26	26/26	—
10°	24/24	24/24	—
15°	23/23	22/22	1
20°	23/23	19/19	4
25°	23/23	18/18	5
30°	21/22	16/17	5
40°	18/18	12/12	6

Note the difference in CFF between the left and right hemifield beyond 15 degrees eccentricity.

experiment, the threshold was measured at 30 degrees eccentricity in the temporal visual field of the left eye (that is, ipsilateral to the lesion). The right eye was covered by an opaque occluder. The increase in increment threshold caused by successive measurements was about 0.6 log units. The adaptation showed an almost total transfer between the two eyes indicating its central nature (fig. 4A). In the temporal visual field of the right eye (that is, contralateral to the lesion) no increase in threshold was found after twenty successive measurements (fig. 4B).

In the second part of the experiment the interaction between the two visual half-fields (binocular condition) was tested. The threshold was measured repeatedly (as described *above*) at 30 degrees eccentricity in the left visual half-field (ipsilateral to the lesion) and once again a decrease in contrast sensitivity was obtained. Control measurements after 2 min showed no spontaneous recovery. Then the threshold was measured at 30 degrees eccentricity in the right visual half-field (mirror symmetrical position, contralateral to the lesion). Immediately after this stimulation the threshold was measured again in the left visual half-field. As can be seen from fig. 5, adaptation was abolished after the measurements at the mirror position. Thus in the visual half-field contralateral to the lesion there was no adaptation, but resetting could be demonstrated.

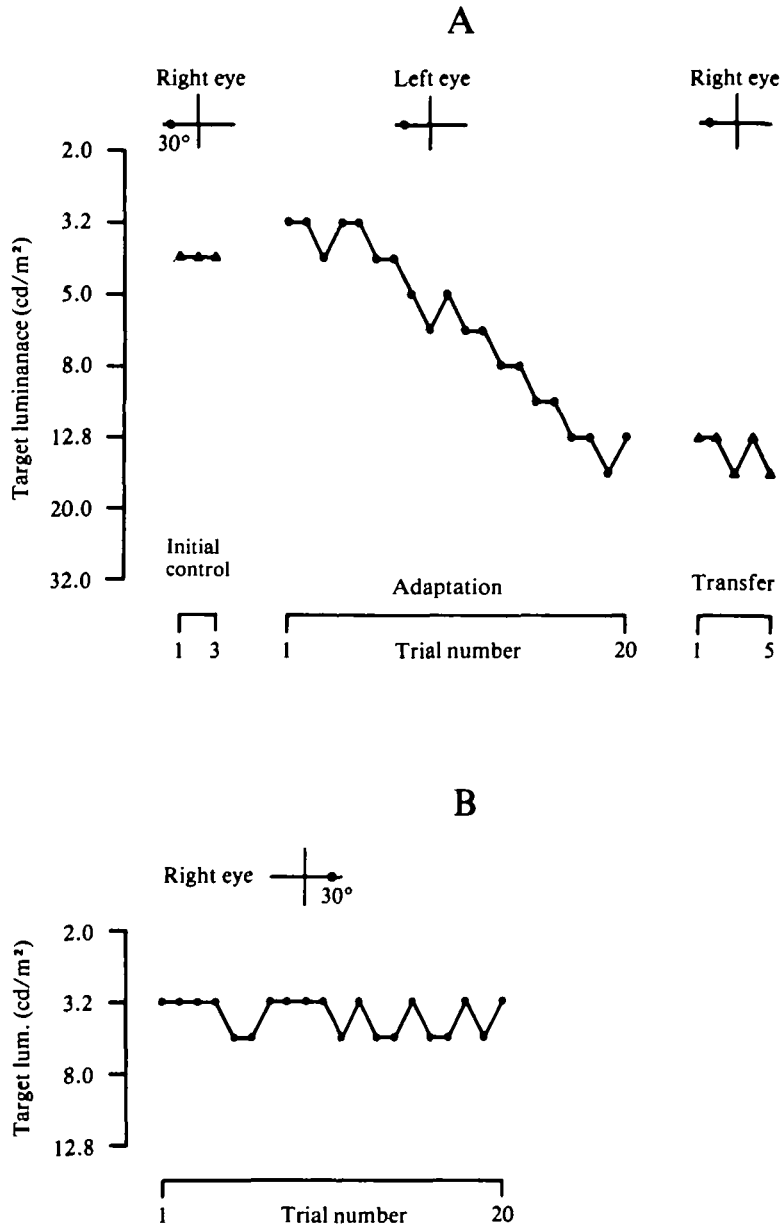


FIG. 4. A, adaptation (left eye, temporal visual field) and interocular transfer (right eye, nasal visual field). B, failure to obtain adaptation in the temporal visual field of the right eye (i.e., contralateral to the lesion). Visual field position is shown in the inserts at the top of the figure. For details *see text*.

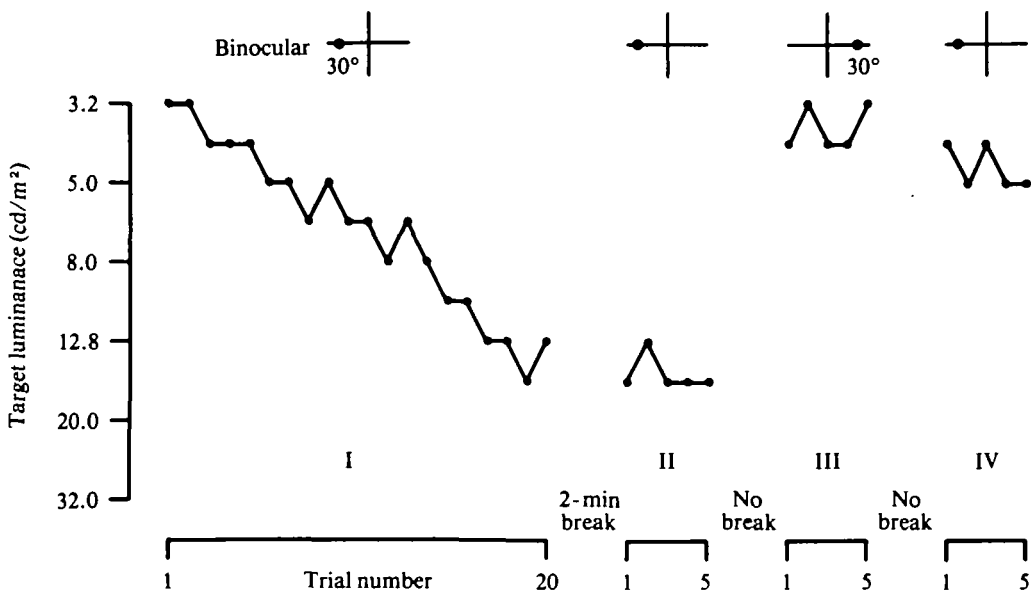


FIG. 5. Adaptation (I) and control measurements (II) in the left hemifield (binocular condition), stimulation at the mirror-symmetric position in the right half-field (III) and immediate resetting of threshold elevation (IV). For details *see text*.

(3) *Simultaneous Bilateral Stimulation*

The following experiments were carried out over three two-day periods, when clinical examinations were also conducted. The patient was seated 120 cm in front of a black wall in a windowless darkened room. Fixation was maintained on a red spot of light (diameter: 1 degree, luminance 2.4 cd/m²), which was projected from behind. Targets were presented simultaneously in the left and right visual half-fields (binocular condition) using two projection tachistoscopes also placed behind the subject. Target luminance was adjusted by neutral density filters. Presentation time, interstimulus interval and time between trials were controlled by electronic circuitry. Eye position was recorded binocularly using a DC-system located behind the subject.




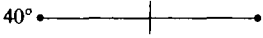
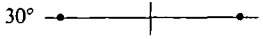
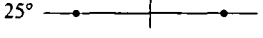
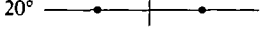
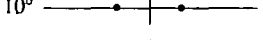
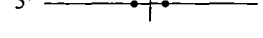

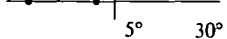
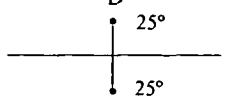
The patient was instructed to fixate the red spot of light and to indicate by finger pointing whether she saw one (on the left or right side) or two light stimuli. She was not allowed to make head movements.

Targets of 0.5 degrees diameter (luminance 1.3 cd/m²; contrast ratio to background 13:1) were presented for 5 ms at 40 degrees eccentricity in the left or right (unilateral condition) or in the left and right visual half-field (bilateral simultaneous stimulation). Intertrial-interval was 5 s for both conditions. In the unilateral condition (50 trials), all targets presented on the left side, but only 22 (44 per cent) targets presented on the right side were detected by the patient. When

two targets were presented simultaneously, one in the left and one in the right visual half-field at 40 degrees eccentricity, the patient pointed only to the target presented in the left in all 100 trials, but never to the target presented in the right visual hemifield, indicating a total 'neglect' for this position in the hemifield contralateral to the pulvinar lesion (Table 2A). Even when she was informed that targets would also appear on the right side, she detected these targets only two or three times. As a control of the patient's detection strategy, blanks were interspersed. Only one (at the left or right side) or no target was presented. No false reactions were observed for this control condition.

In order to investigate this 'neglect' phenomenon in more detail, position in the visual field (eccentricity), size and luminance of the targets and temporal properties

TABLE 2. RESPONSES (%) TO UNILATERAL OR SIMULTANEOUS BILATERAL STIMULATION AT DIFFERENT ECCENTRICITIES

Condition	Responses (%)			
	Both	Left	Right	No response
A				
		100		—
			44	56
	—	100	—	—
B				
	—	94	—	6
	—	96	—	4
	2	84	10	4
	66	30	4	—
	88	4	8	—
	90	6	4	—
C				
	100	—	—	—
	4	96	—	—
D				
	80	8	6	6

Positions of stimulation are indicated by black dots. For details *see text*.

(length of presentation and interstimulus interval) were varied. In each condition 50 trials were carried out. Intertrial-interval was always 5 s. Detection performance was measured in terms of percentage correct responses (i.e. when both targets were detected).

(a) *Simultaneous bilateral stimulation at different eccentricities.* Target size: 0.5 degrees, target luminance: 1.3 cd/m²; presentation time: 5 ms. The different locations of bilateral presentation were randomized. The results are shown in Table 2B. The detection performance for both stimuli decreased as a function of eccentricity; beyond 25 degrees the patient detected the target on the left side only in most of the trials.

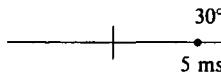
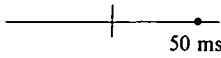

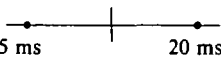

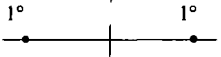
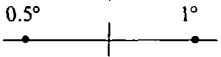

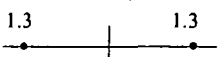


(b) *Simultaneous double stimulation in the same hemifield.* Targets were presented at 5 and 30 degrees eccentricity in the left or right hemifield. Stimulus parameters and presentation time as in (a). As can be seen from Table 2C, the patient detected both targets presented simultaneously in the left half-field with high accuracy. When both targets were presented in the right half-field, the patient pointed only to the target appearing near the fovea (at 5 degrees eccentricity) in most of the trials. This result confirms the observations in (a) indicating that the 'neglect' is limited mainly to the periphery of the right visual hemifield.

(c) *Simultaneous double stimulation in the upper and lower hemifield.* In order to test whether the observed 'neglect' was a phenomenon particularly of the left and right periphery, targets were presented at 25 degrees eccentricity in the upper and lower periphery of the visual field. The results (Table 2D) show quite a good (although not perfect) performance in detecting both stimuli presented along the vertical axis.

(d) *Variation of presentation time, temporal separation and target size and luminance.* The effect of exposure duration on detection performance is shown in Table 3A. Target size was 0.5 degrees in diameter, target luminance 1.3 cd/m². Targets were presented only in one hemifield or simultaneously at 30 degrees eccentricity in the left and right visual hemifield. Increasing presentation time resulted in an improvement in the detection performance for the periphery of the right hemifield. The data for the left hemifield stimulation (100 per cent correct responses) are not shown in the Table.

When the target in the left hemifield was presented for 5 ms and the target in the right hemifield for 20 ms, the patient's detection performance for both targets was over 80 per cent correct responses. In order to test whether this increase in performance was really a function of exposure time or whether it was due to temporal separation, different interstimulus intervals were used. Target size and luminance were the same as in the last experiment. Results are shown in Table 3B; they demonstrate the increase in the percentage of correct responses as a function of interstimulus interval. When the two targets were separated by 20 ms, no 'neglect' could be obtained for the periphery of the right hemifield.

TABLE 3. RESPONSES (%) TO UNILATERAL OR BILATERAL STIMULATION AS A FUNCTION OF EXPOSURE TIME

Condition	Responses (%)			
	Both	Left	Right	No response
A Exposure time				
			44	66
			85	15
	85	9	6	—
	82	8	6	4
B Interstimulus interval				
0	—	96	—	4
10 ms	68	16	10	6
20 ms	92	2	2	4
C Target size				
	—	98	—	2
	—	92	6	2
	40	18	36	6
	64	—	36	—
D Luminance (cd/m²)				
	—	96	—	4
	4	72	20	4
	24	12	60	4

For details see text.

In the next experimental condition, size and luminance of the targets were varied. In Table 3C the effect of target size on detection performance is shown. Increasing the size of both targets (1 degree in diameter; luminance: 1.8 cd/m²) did not influence detection performance, but increasing the size of the target presented in the right hemifield (1 degree and 3 degrees, respectively; luminance: 1.8 and 2.2 cd/m²) resulted in an improvement in detecting this target. Similar results were obtained when the luminance of the target on the right side was increased (16.6 cd/m²; contrast ratio left:right = 1:13.7). Increasing the luminance for both targets (from 1.3 to 6.8 cd/m²), however, did not result in an increase in the percentage correct responses (Table 3D).

(e) 'Extinction' phenomenon during bilateral simultaneous stimulation at 20 degrees eccentricity in the right visual half-field. During the experiments on bilateral simultaneous stimulation at 20 degrees eccentricity (see (a) above) an unusual phenomenon was observed. After about 30 trials the patient pointed only to the target presented in the left hemifield, even though up to this trial number she had detected both targets. In order to study this phenomenon further, targets (0.5 degrees, 1.3 cd/m²; 5 ms presentation time) were presented simultaneously at 10, 20 or 30 degrees eccentricity in both visual half-fields. Table 4 shows the responses for Trial No. 20 to the end of the experiment (Trial No. 50) for the three different eccentricities. The extinction phenomenon occurred only at 20 degrees eccentricity for Trial No. 36 onwards, but not for the position nearer to (10 degrees) or more distant from the fovea (30 degrees eccentricity).

TABLE 4. 'EXTINCTION' PHENOMENON DURING SIMULTANEOUS BILATERAL STIMULATION AT 20 DEGREES ECCENTRICITY

Stimulus No.	Responses									
	10°			20°			30°			
	Both	Left	Right	Both	Left	Right	Both	Left	Right	No response
20	+			+				+		
21	+			+				+		
22	+			+				+		
23	+			+			+			
24	+			+				+		
25	+					+		+		
26	+			+				+		
27	+			+				+		
28	+			+						+
29	+				+				+	
30		+		+				+		
31	+			+				+		
32	+			+				+		
33	+					+		+		
34	+		+	+				+		+
35	+			+				+		
36	+				+			+		
37	+				+			+		
38	+				+			+		
39	+				+			+		
40	+			+				+		
41	+				+					+
42	+				+			+		
43	+				+			+		
44		+			+			+		
45	+				+			+		
46	+				+			+		
47	+				+			+		
48	+				+			+		
49	+				+			+		
50	+				+			+		

Note the failure to detect both targets after Trial No. 35. For 30 deg eccentricity the target in the left visual hemifield was detected only.

(f) *Bilateral simultaneous stimulation: data from normal subjects.* Two normal inexperienced subjects (67 and 25 years old, respectively) participated in the following experiments. In the first experiment, targets with a diameter of 0.5 degrees (luminance: 1.3 cd/m²) were presented for 5 ms at 40 degrees eccentricity in the left and right visual half-field. The instructions were the same as those given to the patient. Both subjects showed a high accuracy in detecting both targets (Table 5A). In the second part of the experiment, the size of the target and its luminance were increased in the right visual half-field only (3 degrees diameter and 16.6 cd/m², respectively; see (d)). Fifty trials were presented for each condition. Neither the increase in target size nor in luminance reduced the percentage correct responses (Table 5B). The results were similar for both subjects, indicating that age did not influence detection accuracy. Furthermore, it seems unlikely that the phenomenon of 'extinction' results from artefacts in the experimental situation or the instructions.

(g) *Oculomotor behaviour: spontaneous lateral eye movements, saccadic responses and saccadic latencies.* In the breaks between the different experimental conditions we observed a paucity of spontaneous lateral saccades towards the right side. To study this phenomenon further, spontaneous lateral saccades were recorded for 6.5 min. The patient kept her eyes at the fixation point for 10 s in order to get a 'steady state' position as a reference line. Then she was instructed that a longer break would be made and that she did not need to maintain fixation during this break. At

TABLE 5. RESPONSES (%) IN 2 NORMAL SUBJECTS TO SIMULTANEOUS BILATERAL STIMULATION (A), AS A FUNCTION OF TARGET SIZE (B) AND LUMINANCE (LEFT TARGET: 1.3 CD/M², RIGHT TARGET: 16.6 CD/M²) ECCENTRICITY WAS 40 DEGREES IN ALL THREE CONDITIONS

		<i>Responses (%)</i>			
		<i>Both</i>	<i>Left</i>	<i>Right</i>	<i>No response</i>
A					
40°	40°				
Subject 1		96	—	—	4
Subject 2		98	2	—	—
B					
0.5°	3°				
Subject 1		90	—	10	—
Subject 2		92	—	8	—
1.3°	16.6°				
Subject 1		88	—	12	—
Subject 2		84	—	16	—

TABLE 6. OCULOMOTOR BEHAVIOUR IN THE PATIENT AND IN A NORMAL SUBJECT

A Spontaneous saccades	To left	To right
Patient (n = 130)	62	38
Normal subject (n = 137)	51	49
B Saccadic responses		
Patient (n = 70)		
Correct responses	67	33
Opposite direction	13	9
No response	20	58
Normal subject (n = 35)		
Correct responses	94	96
Opposite direction	—	—
No response	6	4
C Saccadic latencies (ms)		
Patient (n = 50)		
Mean	423.5	574.4
95% conf. limits	400.6–446.5	518.1–631.3
Range	266–600	330–1066
Normal subject (n = 30)		
Mean	286.5	267.6
95% conf. limits	275.8–297.3	256.2–279.0
Range	200–400	200–400

For details *see text*.

the end of the break the patient was asked to direct her eyes once more to the fixation point and this position was recorded again for 10 s. As can be seen in Table 6A, there is a clear minority of spontaneous saccades to the right side (contralateral to the lesion). Since this recording was performed in the same darkened room and the apparatus was placed behind the subject (both the EOG recording system and the experimenter were located behind a wooden partition), it seems very unlikely that there were any lateralization cues in the darkened room. For comparison (and also for control), spontaneous lateral eye movements were recorded in a normal subject (67-years old) under the same conditions. In this case, no lateralization of spontaneous saccades was observed (Table 6A).

It has been shown in a prior experiment (Table 2A), that the patient often did not respond when the target was presented only in the right side of the hemifield. We repeated this experiment using visually elicited saccadic eye movements. The target was presented without an auditory warning for 5 ms, either in the left or right visual half-field at 30 degrees eccentricity. Target size was 0.5 degrees, target luminance 1.3 cd/m². The patient was asked to make a saccade towards the target presented in the left (or right) side. In the first part, targets appeared only in the left visual hemifield and in the second part only in the right hemifield. A paper velocity of 30 mm/s (1 mm corresponding to 33 ms) was used to evaluate the latency of the saccades.

As just observed in the previous experiment with unilateral stimulation, the patient failed to respond consistently when the target was presented in the right hemifield. Sometimes, also, when targets were presented in the left hemifield no saccadic response could be elicited even though the patient indicated that she had detected the target. For a normal subject (Subject 1), over 90 per cent correct responses to unilateral stimulation was observed (Table 6B). The difficulty in shifting the gaze towards targets presented in the right hemifield was also evident from the delay in the initiation of visually evoked saccadic eye movements. The time between the offset of stimulus and the start of the saccadic response to the right side was markedly increased; the difference as compared to the left side was about 150 ms. In addition, the latencies for saccadic responses to the left hemifield were also increased; the difference from the normal subject was about 140 ms. One may argue that all reaction times are generally increased in the patient and therefore also the latency for visually evoked saccades. The measurement of the visual and acoustic simple reaction time showed, however, that there may be a dissociation of simple hand reaction time to light stimuli and latency for visually evoked saccades. For measurement of hand reaction time, 30 consecutive stimuli were presented, and the patient was instructed to react as quickly as possible to the appearance of each stimulus. The first 10 measurements were taken as a training period. The temporal interval between succeeding stimuli was random, ranging from 2 to 7 s and averaging 4 s. After 10 measurements a break of half a minute was introduced. Mean reaction time to visual stimuli was 279.45 ms ($SD \pm 51.26$), to acoustical stimuli it was 205.15 ms ($SD \pm 41.65$). As reaction time of the saccadic movement is approximately in the same range as that of a hand response to a visual stimulus (Diefendorf and Dodge, 1908; Zihl, 1979), the increased saccadic latency in our patient may result primarily from the damaged left pulvinar. The different presentation times in the two conditions (5 ms exposure duration in the 'saccadic movement' condition and 150 ms in the 'hand response' condition) cannot account for the observed dissociation in the reaction time to visual stimuli. Exposure duration affects hand reaction time below about 50 ms presentation time; the difference, however, is only of the order of 10 ms (Wells, 1913). In addition, control measurements using targets with longer exposure durations (500 ms) showed similar saccadic latencies for the patient.

DISCUSSION

'Neglect' for the Contralateral Hemifield

It has been suggested that the 'second' visual system plays an important role in the control of directed visual attention (Mountcastle, 1978). In addition, neurophysiological observations of monkeys (Goldberg and Wurtz, 1972; Schiller and Malpeli, 1977) and psychophysical data from humans concerning collicular function (Singer *et al.*, 1977; Zihl and von Cramon, 1979) have been interpreted in terms of the

selective control of attention within the visual field. No attempt has been made, however, to test visual attention at a behavioural level.

In our patient the most striking abnormality was a 'neglect' for the periphery of the visual hemifield contralateral to the pulvinar lesion. This was judged by a decrease in the percentage of correct responses of pointing to the target presented in the right half-field (appearing simultaneously with one in the left). However, the degree of this 'neglect' was related both to the position in the right hemifield and to stimulus parameters such as size and luminance. The 'neglect' was only apparent at positions greater than 20 degrees eccentricity in the right hemifield and thus supports the idea that the 'second' visual system is important in the analysis of objects appearing in the periphery of the visual field. Although the 'neglect' was always apparent at greater than 20 degrees eccentricity, at 20 degrees eccentricity it only developed after about 30 trials. No explanation is, as yet, available for this 'extinction' phenomenon in this part of the right visual half-field.

Further, increasing the relative size or luminance of the target presented in the periphery of the right hemifield, or increasing either the length of target presentation or the temporal separation between the target appearing in the left then right hemifield reduced the degree of the 'neglect'.

To our knowledge, this is the first report of a visual 'neglect' observed in a patient suffering from a lesion including the n. pulvinar. This 'neglect' for visual stimuli presented briefly in the right visual half-field was not accompanied by a contralateral 'visuospatial' neglect for visual objects, as observed in patients with parietal lobe lesions (Warrington, 1969; Oxbury *et al.*, 1974). Such 'visuospatial' neglect is qualitatively distinguishable in being an inability to recognize part of an object or to reproduce this part when requested (cf. our patient, fig. 2). Thus, our patient exhibited a single distinctive type of neglect: a reduced ability to detect light stimuli in the periphery of the right visual half-field, that is, that contralateral to the pulvinar lesion, especially during presentation of two simultaneous stimuli.

Oculomotor Responses

Although eye movements were essentially normal, oculomotor behaviour was, in fact, noticeably altered. The poverty of spontaneous horizontal eye movements and the increased latencies of visually evoked saccades directed towards the right visual hemifield are consistent with observations in monkeys subjected to pulvinar (Ungerleider and Christensen, 1977) or collicular lesions (Wurtz and Goldberg, 1972; Latto, 1978). As reported by Heywood and Ratcliff (1975), a patient with unilateral colliculectomy exhibited a similar significant asymmetry of spontaneous saccades; no differences were found, however, in the latency of saccades to targets presented in the hemifield contralateral to the lesion. In our patient latency was, in fact, also increased for visually elicited fast eye movements to the left hemifield. One could argue, therefore, that the increased saccadic reaction time to the right hemifield is composed of, first, a difficulty in the shift of fixation from an original point (which also affected saccadic reactions to the left) and, secondly, of an

increased latency for saccadic eye movements to targets in this hemifield contralateral to the lesion reflecting an attentional deficit with respect to this side. This effect was the only abnormality manifested in both visual hemifields, and one can speculate as to a role of both pulvinars in the change of position of fixation irrespective of the original and subsequent direction of gaze (Ungerleider and Christensen, 1977). Although anatomical investigations have not yet demonstrated a direct interpulvinar pathway, an interaction mediated via an indirect pulvinar—cortex-pulvinar connection—which certainly exists (Benevento and Davis, 1977; Chalupa, 1977)—is quite possible.

Collicular Function—Adaptation and Resetting

As anticipated, an increase in the increment threshold (that is, a decrease in the ability to distinguish a target from a background of differing luminance) occurred, as in normal subjects, after repeated measurement of this contrast threshold in the periphery of the left visual half-field. This decreased sensitivity of the peripheral visual field is in contrast with the foveal situation where such a decrease is not observed (Singer *et al.*, 1977). In the periphery of the right visual hemifield (contralateral to the pulvinar lesion), no increase in the light-difference threshold was obtained. This observation suggests that the modulation of light-difference threshold is mediated by the superior colliculus (Zihl, von Cramon, Pöppel and Singer, 1979) and its projection to the visual cortex via the n. pulvinar. The interruption of this pathway at the level of the pulvinar would explain the lack of adaptation in the right visual hemifield.

After such adaptation at a position in the peripheral visual field, the original sensitivity can be restored by stimulation of the mirror position in the opposite visual half-field. In our patient such a resetting was apparent, suggesting that this is purely a consequence of an interaction between the colliculi, as has been previously discussed by Sprague (1966) for the cat and by Pöppel and Richards (1974) for the human visual system. Further, initial contrast sensitivity (prior to any adaptation) was not diminished in either visual half-field of our patient, whereas this was impaired both in a patient with a collicular lesion (Zihl and von Cramon, 1979) and in monkeys after collicular ablation (Latto, 1977).

Collectively, the above observations provide evidence that collicular function was probably unaffected by the lesion incorporating the n. pulvinar. The abnormalities in visual function observed in our patient, therefore, may be interpreted as primarily consequences of the pulvinar lesion.

Eccentricity-specific Dissociation of Critical Flicker Fusion

In the normal unrestricted visual field of our patient (suffering from a lesion incorporating the left pulvinar), a marked reduction was found in the critical flicker fusion (CFF) only for the periphery of the right visual hemifield. A similar reduction in CFF in the right visual half-field was observed in a patient with a left collicular lesion (Zihl and von Cramon, 1978), whereas in patients with lesions of the geniculo-

striate visual pathway a reduction in CFF was found only for the parafoveal region (Pöppel, von Cramon and Backmund, 1975). The 'second' visual system may, therefore, play a critical role in the processing of rapidly presented visual stimuli in the periphery of the visual field, but, as the peripheral CFF was only partially depressed, the involvement of an additional system (probably the 'first' visual system) in this function should also be taken into consideration. The particular contribution of the 'second' visual system to the differentiation of rapidly presented stimuli appearing in the periphery of the visual field may be an attentional one. Since the size of the visual field capable of distinguishing repeated stimuli at less than 15 Hz was the same for both hemifields, the attentional component of processing rapidly presented stimuli is presumably of greater importance at higher frequencies (cf. fig. 3 and Table 1).

In conclusion, one prominent function of the tectopulvinar extrastriate visual system may be in the control of the direction and, perhaps, the 'intensity' of visual attention. The detection of objects in the peripheral part of the visual field is often a prerequisite for their subsequent foveation, and, in this respect, the pulvinar appears to be critical for fovea-mediated pattern discrimination (Chow, 1954; Chalupa, Coyle and Lindsley, 1976; Chalupa, 1977). An unilateral depression of pulvinar function may result in a 'neglect' of the contralateral hemifield due to an inability to shift visual attention to this side. As an indirect consequence, saccadic responses to objects appearing in the contralateral hemifield are diminished or their latencies are abnormally prolonged.

SUMMARY

The visual functions of a patient suffering from a brain lesion incorporating the left n. pulvinar was examined in order to assess the contribution of this structure to human vision. With the exception of the following abnormalities visual functions were normal. First, there was a decrease in the critical flicker frequency in the periphery (but not in the parafoveal region) of the right visual hemifield, that is, that contralateral to the pulvinar lesion. However, the second and most striking characteristic was—as shown by presenting visual stimuli bilaterally and simultaneously—a 'neglect' for the periphery of this contralateral visual half-field. This 'neglect' was a function of (*a*) position in the visual field (eccentricity), (*b*) stimulus properties (size and luminance), (*c*) temporal properties (length of presentation and interstimulus interval). In addition to this reduced capacity to detect stimuli appearing in the periphery of the right visual hemifield, there was also prolonged latency of visually evoked saccadic eye movements and a paucity of spontaneous eye movements directed towards the right visual hemifield. These results are interpreted in terms of a contribution of the n. pulvinar to the detection of light stimuli presented in the periphery of the visual field, and support the view that the tectopulvinar extrastriate visual pathway plays an important role in the control of visual attention.

ACKNOWLEDGEMENTS

We are deeply grateful to the patient, who gave her willing co-operation throughout many hours of experimental testing. We thank Dr W. Singer for comments, and Mrs M. Osborne and Mr M. Miller for grammatical corrections. We also thank the Deutsche Forschungsgemeinschaft for financial support.

REFERENCES

- BATES, J. A. V. and ETTLINGER, G. (1960) Posterior biparietal ablations in monkeys. Changes to neurological and behavioral testing. *Archives of Neurology, Chicago*, **3**, 177-192.
- BENEVENTO, L. A. and DAVIS, B. (1977) Topographical projections of the prestriate cortex to the pulvinar nuclei in the macaque monkey: an autoradiographic study. *Experimental Brain Research*, **30**, 405-424.
- BUTTER, C. M., WEINSTEIN, C., BENDER, D. and GROSS, C. G. (1978) Localization and detection of visual stimuli following superior colliculus lesions in rhesus monkeys. *Brain Research, Amsterdam*, **156**, 33-49.
- CHALUPA, L. M. (1977) A review of cat and monkey studies implicating the pulvinar in visual function. *Behavioral Biology*, **20**, 149-167.
- COYLE, R. S. and LINDSLEY, D. B. (1976) Effect of pulvinar lesions on visual pattern discrimination in monkeys. *Journal of Neurophysiology*, **39**, 354-369.
- CHOW, K. L. (1954) Lack of behavioral effects following destruction of some thalamic association nuclei in monkey. *AMA Archives of Neurology and Psychiatry*, **71**, 762-771.
- DENNY-BROWN, D. (1962) The midbrain and motor integration. *Proceedings of the Royal Society of Medicine*, **55**, 527-538.
- DIEFENDORF, A. R. and DODGE, R. (1908) An experimental study of the ocular reactions of the insane from photographic records. *Brain*, **31**, 451-489.
- ETTLINGER, G. and KALSBECK, J. E. (1962) Changes in tactile discrimination and in visual reaching after successive and simultaneous bilateral posterior parietal ablations in the monkey. *Journal of Neurology, Neurosurgery and Psychiatry*, **25**, 256-268.
- GOLDBERG, M. E. and WURTZ, R. H. (1972) Activity of superior colliculus in behaving monkey. II. Effect of attention on neuronal responses. *Journal of Neurophysiology*, **35**, 560-574.
- HÉCAEN, H. and DE AJURJAGUERRA, J. (1954) Balint's syndrome (psychic paralysis of visual fixation) and its minor forms. *Brain*, **77**, 373-400.
- HEYWOOD, S. and RATCLIFF, G. (1975) Long-term oculomotor consequences of unilateral colliclectomy in man. In: *Basic Mechanisms of Ocular Motility and their Clinical Implications*. Edited by G. Lennerstrand and P. Bach-y-Rita. Oxford: Pergamon Press, pp. 561-564.
- HYVÄRINEN, J. and PORÄNEN, A. (1974) Function of the parietal associative area 7 as revealed from cellular discharges in alert monkeys. *Brain*, **97**, 673-692.
- INGLE, D. (1967) Two visual mechanisms underlying the behaviour of fish. *Psychologische Forschung*, **31**, 44-51.

- KEATING, E. G. (1974) Impaired orientation after primate tectal lesions. *Brain Research, Amsterdam*, **67**, 538-541.
- (1976) Effects of tectal lesions on peripheral field vision in the monkey. *Brain Research, Amsterdam*, **104**, 316-320.
- LATTO, R. (1977) The effects of bilateral frontal eye-field, posterior parietal or superior collicular lesions on brightness thresholds in the rhesus monkey. *Neuropsychologia*, **15**, 507-516.
- (1978) The effects of bilateral frontal eye-field, posterior parietal or superior collicular lesions on visual search in the rhesus monkey. *Brain Research, Amsterdam*, **146**, 35-50.
- LYNCH, J. C., MOUNTCASTLE, V. B., TALBOT, W. H. and YIN, T. C. T. (1977) Parietal lobe mechanisms for directed selective attention. *Journal of Neurophysiology*, **40**, 362-489.
- MENDOZA, J. E. and THOMAS, R. K. (1975) Effects of posterior parietal and frontal neocortical lesions in the squirrel monkey. *Journal of Comparative and Physiological Psychology*, **89**, 170-182.
- MOUNTCASTLE, V. B. (1978) Brain mechanisms for directed attention. *Journal of the Royal Society of Medicine*, **71**, 14-28.
- OXBURY, J. M., CAMPBELL, D. C. and OXBURY, S. M. (1974) Unilateral spatial neglect and impairments of spatial analysis and visual perception. *Brain*, **97**, 551-564.
- PATTERSON, A. and ZANGWILL, O. L. (1944) Disorders of visual space perception associated with lesions of the right cerebral hemisphere. *Brain*, **67**, 331-358.
- PERENIN, M. T. and JEANNEROD, M. (1975) Residual vision in cortically blind hemifields. *Neuropsychologia*, **13**, 1-7.
- PÖPPEL, E., HELD, R. and FROST, D. (1973) Residual visual function after brain wounds involving the central visual pathways in man. *Nature, London*, **243**, 295-296.
- and RICHARDS, W. (1974) Light sensitivity in cortical scotoma contralateral to small islands of blindness. *Experimental Brain Research*, **21**, 125-130.
- VON CRAMON, D. and BACKMUND, H. (1975) Eccentricity-specific dissociation of visual functions in patients with lesions of the central visual pathways. *Nature, London*, **256**, 489-490.
- ROBINSON, D. L., GOLDBERG, M. E. and STANTON, G. B. (1978) Parietal association cortex in the primate: sensory mechanisms and behavioral modulations. *Journal of Neurophysiology*, **41**, 910-932.
- SCHILLER, P. H. and MALPELI, J. G. (1977) Properties and tectal projections of monkey retinal ganglion cells. *Journal of Neurophysiology*, **40**, 428-445.
- SCHNEIDER, G. E. (1969) Two visual systems. *Science*, **163**, 895-902.
- SINGER, W., ZIHL, J. and PÖPPEL, E. (1977) Subcortical control of visual thresholds in humans: Evidence for modality specific and retinotopically organized mechanisms of selective attention. *Experimental Brain Research*, **29**, 173-190.
- SLOAN, L. L. (1971) The Tübingen perimeter of Aulhorn and Harms. *Archives of Ophthalmology*, **86**, 612-622.
- SPRAGUE, J. M. (1966) Interaction of cortex and superior colliculus in mediation of visually guided behavior. *Science*, **153**, 1544-1547.

- TREVARTHEN, C. B. (1968) Two mechanisms of vision in primates. *Psychologische Forschung*, **31**, 299-337.
- UNGERLEIDER, L. G. and CHRISTENSEN, C. A. (1977) Pulvinar lesions in monkeys produce abnormal eye movements during visual discrimination training. *Brain Research, Amsterdam*, **136**, 189-196.
- WARRINGTON, E. K. (1969) Constructional apraxia. In: *Handbook of Clinical Neurology*. Volume 4. Edited by P. J. Vinken and G. W. Bruyn. Amsterdam: North Holland Publishing Company, pp. 67-83.
- WEISKRANTZ, L., COWEY, A. and PASSINGHAM, C. (1977) Spatial responses to brief stimuli by monkeys with striate cortex ablations. *Brain*, **100**, 655-670
- WARRINGTON, E. K., SANDERS, M. D. and MARSHALL, J. (1974) Visual capacity in the hemianopic field following a restricted occipital ablation. *Brain*, **97**, 719-728.
- WELLS, G. R. (1913) The influence of stimulus duration on reaction time. *Psychological Monographs*, **15** (5, Whole No. 66).
- WURTZ, R. H. and GOLDBERG, M. E. (1972) Activity of superior colliculus in behaving monkey. IV. Effects of lesions on eye movements. *Journal of Neurophysiology*, **35**, 587-596.
- ZIHL, J. (1979) 'Blindsight': Improvement of visually guided eye movements by systematic practice in patients with cerebral blindness. *Neuropsychologia*. In press.
- and VON CRAMON, D. (1978) Perimetric testing of superior colliculus function in man: A case study. *Nervenarzt*, **49**, 488-491.
- (1979) Midbrain function in human vision. *Experimental Brain Research*, **35**, 419-424.
- PÖPPEL, E. and SINGER, W. (1979) Interhemispheric modulation of light-difference threshold in the periphery of the visual field. In: *Structure and Function of the Cerebral Commissures*. Edited by I. S. Russell, M. W. van Hof and G. Berlucchi. London: Macmillan Press, pp. 421-427.

(Received November 21, 1978)