

ACUTE HEMIPLEGIA OF CHILDHOOD WITH TOTAL OCCLUSION OF THE INTERNAL CAROTID ARTERY (SUPRA-CLINOID)

A case report

BOSTON F. MARTIN, M.D.,¹ F.A.C.A., EMILIO TORRES REYES, M.D.²
AND EDUARDO MIRABAL FONT, M.D.³

The Syndrome of Intracranial Arterial Occlusive disease occurs more frequently in childhood than would be expected.^{5, 7}

It is the purpose of this paper to present a case of such a patient and briefly review some of the literature on the subject.

CASE REPORT

A 10 year old left handed boy was admitted to the University Hospital on February 18, 1970 with a chief complaint of sudden weakness of the right side of the body. His mother, who is a nurse anesthetist, gave the following antecedent history:

He was completely well until the day of admission when, at school, he received trauma to the head when he walked into a door (field cut?) at about 9:00 A.M. Approximately 15-30 minutes later, he fell to the ground while jumping over a small obstacle, but he denied striking his head this time. He proceeded to the playground and began playing baseball when, suddenly, he felt a sharp pain in the left side of his head, became unsteady on his feet and sat down. He immediately tried getting up and could not do so. He had to be helped into the classroom by his companions. He again fell to the floor, and this time with the face deviated to the left. He was noted to have tonic-clonic contractions of facial muscles.

He was seen at 9:45 A.M. by a private M.D. who found that he had developed marked difficulty with speech (couldn't pronounce commonly used words, but could recognize people that he knew). He was unusually slow in responding to questions asked and his attention span was noted to be considerably shortened. His right arm and leg were paretic and he had a tendency to fall to the right when trying to walk. He then vomited several times.

The past medical history was entirely normal including birth history.

Upon admission to the University Hospital the general physical and Neurological examination was as noted earlier with the following new findings:

1) Anisocoria with pupil O. S. 3 mm—O. D. 4 mm. Both were reactive and accommodated. Fundoscopic examination was normal.

* Neuro-Diagnostic Center, Hato Rey, Puerto Rico.

From the Departments of Surgery¹ (Neurosurgery), Radiology² (Neuroradiology) and Pediatrics³ (Pediatric Neurology) of The University of Puerto Rico School of Medicine and The University Hospital.

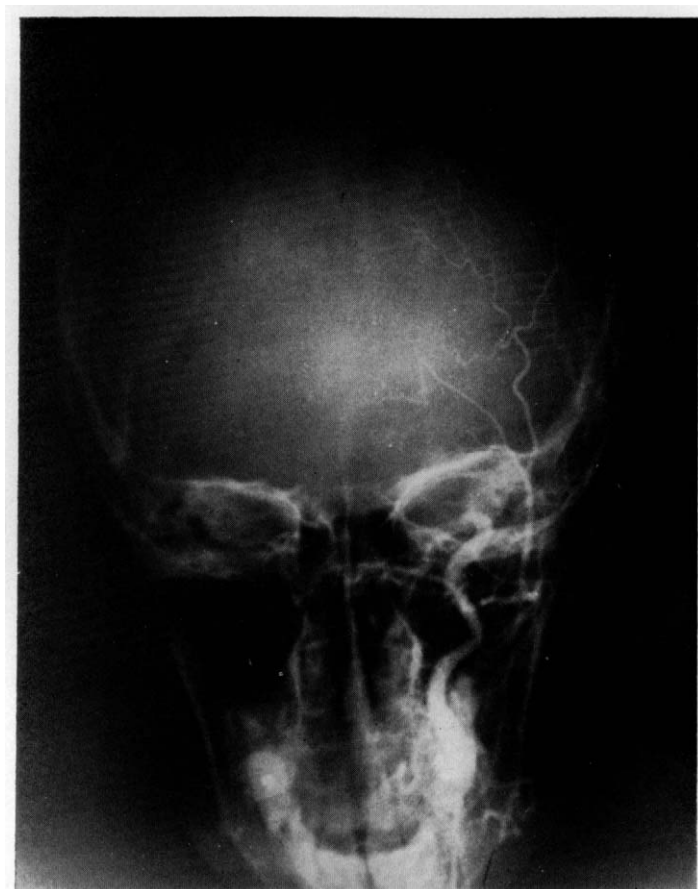

FIG. 1. Antero-Posterior View of left carotid angiogram demonstrating filling of the external carotid.

- 2) Developed right handed astereognosis.
- 3) Had "past-pointing" and intention tremor of R.U.E. upon finger—to—nose testing.
- 4) Deep tendon reflexes decreased on left side.
- 5) Equivocal Babinsky reflex upon right plantar stimulation.

COURSE IN HOSPITAL

Patient was placed on Anti-convulsants and sedation. A lumbar puncture was performed and demonstrated an O.P. 140 mm H₂O. The cerebrospinal fluid was crystal clear and colorless. The glucose was reported as 42 mgm%, Protein 26 mgm%. Two monocytes were seen. No RBC were seen.

A Hemogram, urine analysis, BUN and electrolyte studies were all within normal limits, as were plain skull films and an electrocardiogram. An electroencephalogram, unfortunately, could not be performed on admission, however, one

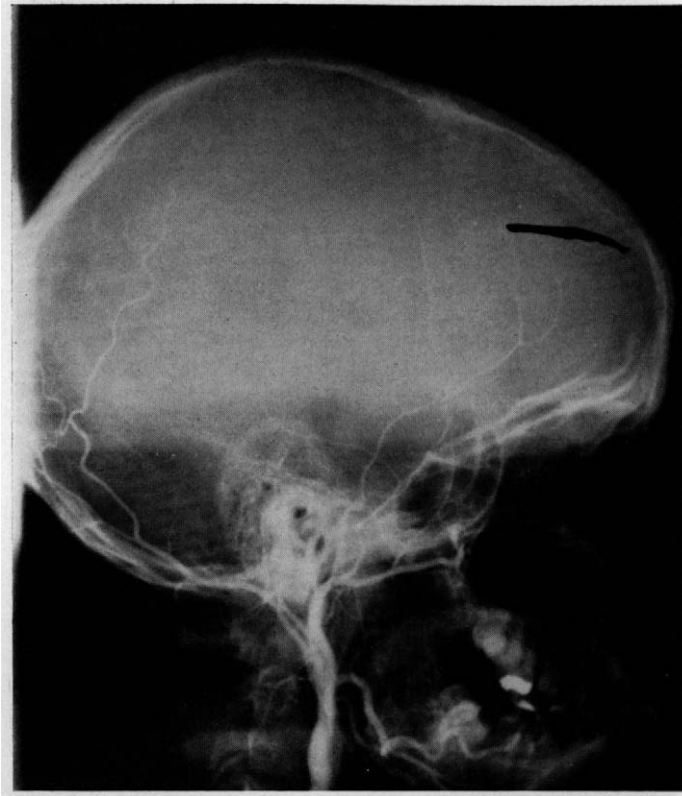


FIG. 2. Lateral view of left carotid arteriogram demonstrating filling of the external carotid.

taken at a later date revealed the presence of some abnormal electrical activity in the left parietal area (epileptogenic foci).

A left carotid angiogram was performed on 2-19-70 and revealed normal cervical position of the vessel. The intraclinoid portion was irregular and at the level of the supraclinoid portio, there was a *total occlusion* of the artery with a concave shaped defect noted at the arterial end of this region. The external carotid filled completely with no evidence of an external or internal anastomosis through the dura. There was some evidence of back flow into the right carotid artery with subsequent filling of the circulation and crossing over from one side to the other. (Permeating to the left as a main source of collateral circulation?) The ophthalmic artery, while somewhat dilated, did not demonstrate retrograde flow. (Occlusion at supraclinoid level.) (See figures 1, 2, 3, 4).

By the third hospital day, patient had improved considerably in that his right sided weakness had all but disappeared. His seventh nerve palsy persisted. He was awake, alert, and oriented. His daily fundoscopic examinations remained normal. His vital signs were within satisfactory limits. There was no further clinical evidence of seizure activity.

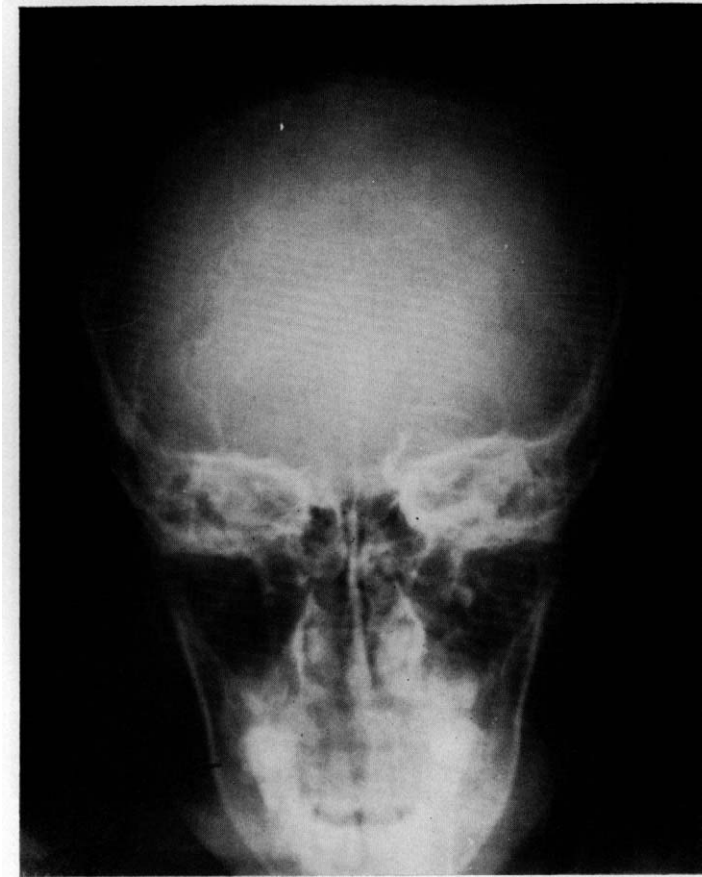

FIG. 3. Antero-Posterior View of left Carotid Angiogram demonstrating supra-clinoid occlusion.

On the eight hospital day he was out of bed and playing ball on the ward, and with no focal deficit except for residual seventh nerve palsy. He was being followed conjointly by a Physical Medicine and Rehabilitation team. He was discharged on anti-convulsants the next day.

He is being followed closely in our out-patient clinics.

DISCUSSION

It has been shown that narrowing or occlusion of the supraclinoid segment of the internal carotid artery without telangiectasia is almost always unilateral.^{1, 4, 6, 8}

In Taveras⁷ report on multiple arterial occlusions, he postulated an autoimmune reaction as a possible etiology. He also stated that the condition described by him is a different entity than the carotid occlusion in hemiplegia of childhood.

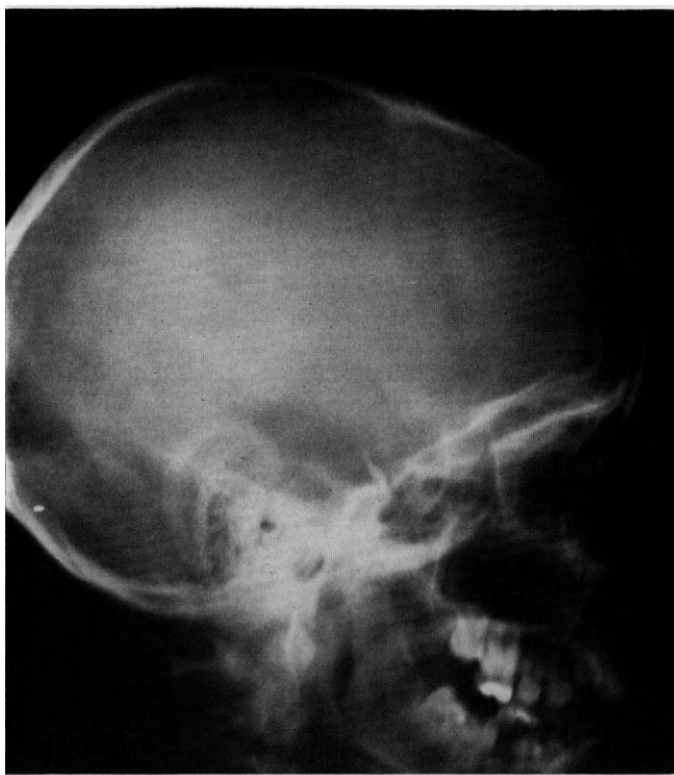


FIG. 4. Lateral view of left carotid angiogram demonstrating supra-clinoid occlusion.

In the large number of cases reported, the arteriographic findings progress initially, but examination several months later shows evidence of regression. This had prompted some authors to suggest arterial spasm as a possible etiology, however, present day knowledge of intracranial vascular dynamics makes this unlikely.

Ivan and Marian² reported a discrepancy between Angiographic and post-mortem findings in carotid occlusions (internal carotid) in adults. They classified occlusive patterns (three types) according to the shape of the contrast column. Their conclusion that intracranial carotid occlusions are frequently missed, however, should be further studied.

Soloman et al⁵ in their study of 86 children with acute hemiplegia divided their patients into eight categories. Their purpose was to find criteria by which prognosis for seizures, residual hemiparesis, intellectual capacity, and behavioral disorders could be offered. The groups were formulated on an etiological basis and defined as documented occlusive vascular disease, injury, C.N.S. infections, cardiac disease, sickle cell anemia, vascular malformations, unknown origin and miscellaneous. If we were to attempt to fit our case into one of their categories, it would have to fall into one of the last two types mentioned, since

none of the other conditions apply. However, as pointed out in Taveras' paper, our patient could have suffered the first of multiple episodes, and could possibly be classified specifically. Certainly he doesn't belong in the hemiplegia of infancy group, as his age and rapid recovery disqualify him. His clinical history, after minute on going analysis doesn't reveal any other possible etiology.

The time since onset of the episode is still short and we are hopeful of obtaining permission in 8-12 months for a repeat angiography study. We believe that this case presents an interesting challenge and that increased awareness of the different possibilities in such cases is necessary.

SUMMARY

A case of spontaneous intracranial carotid occlusion has been reported. A short discussion of its possible etiology is made. Review of the most pertinent literature is included.

*Boston F. Martin, M.D., F.A.C.A.
University of Puerto Rico
School of Tropical Med.
San Juan, Puerto Rico 00905*

ACKNOWLEDGMENTS

The authors wish to thank Doctors Roberto Negrón-Crespo and Nathan Rifkinson for their comments and critical appraisal of this case report.

REFERENCES

1. Bickerstaff, E. R. *Aetiology of Acute hemiplegia in Childhood*. British Med. Jour., 1964, Vol. 2, Pgs. 82-87.
2. Ivan, L. P., Marian, J. J. *Angiographic Occlusive Patterns of the Internal Carotid Artery*. Jour. of Neurosurgery, 1969, Vol. 30, pgs. 233-237.
3. Murphey, F., and Shillito, J. *Avoidance of False Angiographic localization of the site of the internal Carotid Occlusion*. Journ. Neurosurgery., 1959, Vol. 16, pgs. 24-31.
4. Shillito, J., Jr., *Carotid Arteritis: A Cause of Hemiplegia in Childhood*. Jour. Neurosurgery, 1964, Vol. 21, pgs. 540-551.
5. Solomon, G. E., Hilal, S. K., Gold, A. P., and Carter, S. *Natural History of Acute Hemiplegia of Childhood*. Brain, 1970, Vol. 93, pgs. 107-120.
6. Stevens, H. *Carotid Artery Occlusion in Childhood*. Pediatrics, 1959, Vol. 23, pgs. 699-709.
7. Taveras, Juan M. *Multiple Progressive Intracranial Arterial Occlusions: A Syndrome of Children and Young Adults*. The American Journal of Roentgenology, Rad. Therapy and Nuclear Med., 1969, Vol. 106, pgs. 235-268.
8. Wisoff, H. S., and Rothballe, A. B. *Cerebral Arterial thrombosis in children; review of literature and addition of two cases in apparently healthy children*. A.M.A. Arch. Neurol., 1961, Vol. 4, pgs. 258-267.