

# Vein of Galen Malformation with Atypical Manifestations: a Case Report

***K. Kalyanaraman\* K. Jagannathan B. Ramamurthi***

---

## **Introduction**

Aneurysms of the vein of Galen are midline arteriovenous malformations of congenital origin and are also referred to as aneurysmal dilatation or arteriovenous malformation of the vein of Galen. Pool and Potts (1965) credit Steinheil with the first description of such a lesion in 1895.

The most recent and lucid account of the clinical manifestations, and a review of the various aspects of this congenital arteriovenous malformation, can be found in the monographs of Gold *et al.* (1964) and Pool and Potts (1965). A recent report from India has pointed to the familial occurrence of this condition (Gowriedevi and Raja Reddy 1971).

The purpose of this communication is to present a case of aneurysm of the vein of Galen diagnosed during life by angiography and manifesting as alternate hemiparesis and progressive mental retardation.

## **Case Report**

The child was 3 years old when he was first seen at the Neurology Department of the Government General Hospital, Madras, in June 1967. The chief complaints were

weakness of right upper and lower limbs of 25 days duration and altered sensorium with drowsiness of 2 days duration. He was born of non-consanguineous parents and was a full-term normal infant. The delivery was normal and no abnormalities were noted in the neonatal period. However, his development was poor with retardation of both motor and mental milestones. He gained head control at the age of 12 months and could sit up at the age of 18 months. By the age of 2 years he was able to walk unsteadily with support. He was just walking without support at the time of onset of his present complaints. He spoke in monosyllables by 18 months and had acquired only a few more words when he was referred to us at 3 years of age.

At the age of 10 months, after a routine check-up, he was found to have a primary tuberculous focus and was given INAH for one month. He had had a smallpox vaccination at the age of 6 months, which was uneventful. At the age of 18 months he had an attack of high fever, without alteration of sensorium, which lasted for 24 hours, followed by a left hemiparesis. He is said to have slowly recovered from

---

Institute of Neurology, Madras Medical College and Government General Hospital, Madras 3, India.

\* Present address: Department of Neurology, E. J. Meyer Memorial Hospital, 462 Grider Street, Buffalo, New York 14215. (*Reprint requests to this address.*)

this episode enough to walk at 2. However, he experienced transient episodes of stiffness of the left upper and lower limbs, without disturbances of consciousness.

The present illness started when he was given an ATS injection for a nail prick in the leg. About 20 minutes after the injection he had urticarial rashes and suffered an anaphylactic shock. He was admitted to the Children's Ward of the Government General Hospital and given injections and artificial respiration. He was unconscious for the whole of that day. On the following morning he was conscious, probably dysphasic, and had a right hemiparesis. He had no convulsions at any time. He was slowly recovering his power of speech and the weakness of the right side was improving when he became drowsy and was referred to the Neurology Department, two days after the onset of drowsiness.

#### *Physical Examination*

He was drowsy with good peripheral and carotid pulses and there were no cervical or cranial bruits. He was normotensive. His pupils were equal and reacting. There were no other physical findings of significance. Head circumference was 48 cm.

#### *Neurological Examination*

The child was slightly drowsy, but awakened easily and obeyed simple commands. He had dysphasia which was predominantly motor and probably global. He had a spastic right motor hemiparesis.

He was considered to have had a cerebrovascular accident involving the left carotid system. A left carotid angiogram was unsuccessful. Lumbar puncture showed clear CSF under normal pressure, with no block: there were no cells; protein 43 mg; globulin negative; chlorides 690 mg; sugar 62 mg. He was considered to have had a postictal paralysis and was discharged on phenytoin sodium 50 mg b.i.d.

He was lost to follow-up and was seen 3 years later in April 1970, with the complaints of progressive loss of vision and abnormal behaviour (both of 1½ years' duration) and worsening mental retardation.

#### *Physical Examination*

The child was disoriented in all spheres, and hyperkinetic. Carotid and peripheral pulses were normal and there were no cranial or cervical bruits. Co-operation was poor for examination. Pulse was 80/m regular, blood-pressure in the right arm in recumbent posture was 98/70. There were no other significant physical findings. Head circumference was 53 cm (= + 15.0 for age 6 years).

#### *Neurological Examination*

The child was mentally retarded, hyperkinetic and aggressive. Speech was dysarthric and monosyllabic. Gait was suggestive of a left spastic hemiparesis. Cranial nerves showed gross diminution of vision bilaterally, and bilateral primary optic atrophy. Pupils were 6 mm in diameter bilaterally and reacted sluggishly to light and accommodation. There was evidence of mild bilateral lateral rectus palsy. There was a minimal right upper motor neurone type of facial weakness. He had bilateral spasticity (greater on the left side) and pyramidal type of weakness of both sides, also greater on the left side. There were bilateral Hoffman signs and symmetrically exaggerated deep reflexes with extensor plantar responses. The cremasteric and abnormal reflexes were present on both sides. Because of poor co-operation the sensory system could not be examined satisfactorily but appeared to be normal. There were no cerebellar signs or abnormalities of spine and cranium.

Investigations revealed a normal haemogram and urinalysis. Mantoux was positive. CSF was colourless and under

normal pressure: there were no cells; protein 80 mg; globulin negative. X-ray of skull (antero-posterior and lateral views), and X-ray of chest were normal. ECG was within normal limits for age. Only a sleeping EEG record was possible, which showed mild diffuse disorganisation. A right carotid angiogram (antero-posterior and lateral views) showed a vein of Galen malformation (Fig. 1).

### Comment

Arteriovenous malformations of the vein of Galen have different signs and symptoms at different ages. Gold *et al.* (1964) described three types, according to the age of onset, each with a characteristic but different symptomatology. According to them, in the neonatal period aneurysms of the vein of Galen present with cardiomegaly and cardiac decompensation with or without enlargement of the head. In infancy, it usually presents with hydrocephalus, bruits over skull and convulsive seizures (though cardiomegaly is also frequent and occasionally cardiac decompensation may occur). In childhood and

later, the presenting features are headaches, mental retardation and subarachnoid haemorrhage. Poppen and Avman (1960) have reported two patients aged 16 years and 42 years, with episodes of unconsciousness, vertigo, visual disturbances and weakness of the extremities. According to Gold *et al.* (1964) neurological signs are common in the older age-group and a bruit over neck or skull is seldom found. Agee *et al.* (1969) reported two patients presenting as a cosmetic problem due to facial varicosities which were the result of development of collaterals secondary to spontaneous thrombosis of the malformation and draining venous channels.

From the reports in the literature, we would have expected our case to have shown the signs and symptoms associated with arteriovenous malformation of vein of Galen in childhood. Our patient certainly had mental deterioration, and probably seizures which were ill-described. The unusual feature of our case was the occurrence of hemiparesis on two occasions, first on the left side and then on the right. Both the attacks were of sudden onset. The first was associated with an

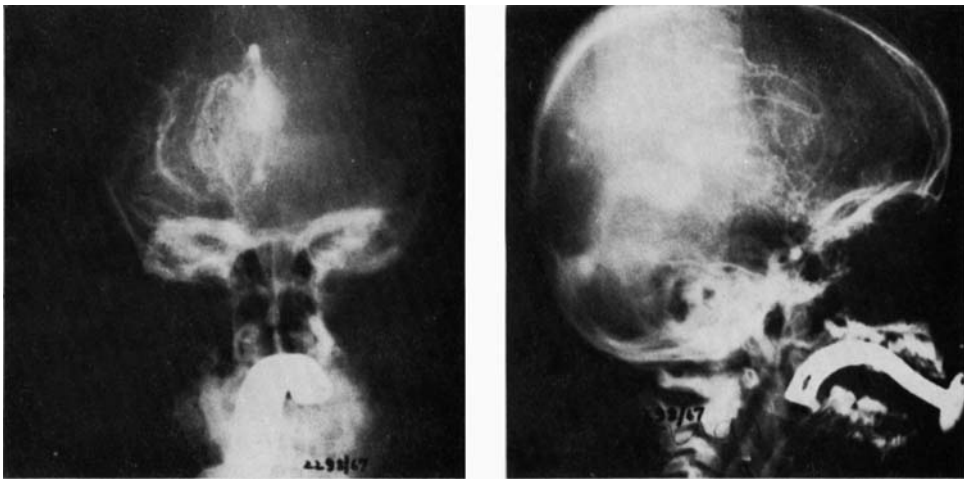


Fig. 1. Right carotid angiograms showing the vein of Galen malformation. Left—antero-posterior view; right—lateral view.

attack of high fever and the second was after an anaphylactic reaction.

With regard to the first attack of left hemiparesis, it is a well-known phenomenon that induced hyperthermia can precipitate or worsen symptoms in patients with diverse neurological disorders (Nelson *et al.* 1958), especially in demyelinating disorders like multiple sclerosis (Nelson and McDowell 1959). We postulate that, in the presence of a large midline arteriovenous malformation, our patient had a chronic cerebral steal syndrome with shunting-off of blood from the hemispheres into the systemic circulation, resulting in a slow sclerosis of grey and white matter with demyelination. During the attack of high fever, the hyperthermia could have precipitated neurological signs, much in the same way as an induced hyperthermia does in other neurological disorders, especially in multiple sclerosis with a pre-existing demyelination. The alternative explanation would be that, secondary to the metabolic changes in pyrexia, more blood was shunted to the periphery, thus enhancing the already existing steal of cerebral blood flow, and infarction of the hemisphere occurred. This is very unlikely, as the recovery of the patient's hemiparesis was dramatic, suggesting that there was no

sizeable infarction of the hemisphere.

With regard to the second attack of hemiparesis, it is well-known that, in the presence of cerebrovascular disease, transient ischemic attacks can be precipitated by systemic hypotensive episodes in some cases, if not in all (Denny-Brown 1951, Denny-Brown and Meyer 1957, Marshall 1965). It is possible that during the anaphylactic shock following ATS injection (probably associated with hypotension), decompensation in blood-flow to the left hemisphere occurred with right hemiparesis.

We performed an angiogram in this patient as we were intrigued by the occurrence of alternate hemiparesis, both sudden and seemingly vascular in origin. With the introduction of more frequent angiography in children, vascular lesions like arterial occlusions, and arteriovenous malformations, are being more frequently recognised (Solomon *et al.* 1970). This case demonstrates the fact that angiography is a 'must' in all suspected vascular lesions of CNS in children and will help in timely diagnosis of lesions otherwise unsuspected.

*Acknowledgement:* Our thanks are due to the Dean, Madras Medical College and Government General Hospital, for permitting us to publish this case report.

#### SUMMARY

A 6-year-old child is described with an aneurysm of the vein of Galen, diagnosed by carotid angiography. The unusual manifestation of alternating hemiparesis was associated with fever on one occasion and with anaphylactic reaction to ATS injection on the other.

The probable pathogenesis of the atypical manifestations is discussed, and a plea is made for more frequent angiography in children so that uncommon vascular lesions can be diagnosed early.

#### RÉSUMÉ

*Malformation de la veine de Galien avec manifestations atypiques: Etude d'un cas*

Les auteurs décrivent le cas d'un enfant de 6 ans, porteur d'un avérisme de la veine de Galien, diagnostiqué par angiographie carotidienne. Une manifestation inhabituelle d'hémi-parésie alternante associée à de la fièvre en une occasion et à une réaction anaphylactique à l'injection d'A.T.S. à un autre moment est soulignée.

La pathogénie probable de ces manifestations atypiques est discutée et il est demandé de pratiquer plus souvent une angiographie chez l'enfant pour le diagnostic précoce de lésions vasculaires inhabituelles.

#### ZUSAMMENFASSUNG

*Mißbildung der Galen'schen Vene mit atypischen Manifestationen: Bericht über einen Fall*

Es wird über ein 6 Jahre altes Kind mit einem Aneurysma der Galen'schen Vene berichtet, das durch eine Carotisangiographie diagnostiziert wurde. Die ungewöhnliche Symptomatik einer alternierenden Hemiparese, in einem Falle nach ATS-Injektion mit Fieber, in einem anderen Falle mit einer anaphylaktischen Reaktion wird dargelegt.

Die wahrscheinliche Pathogenese dieser atypischen Manifestationen wird diskutiert und häufigere Angiographien bei Kindern werden empfohlen, um ungewöhnliche Gefäßmißbildungen früh zu erkennen.

#### RESUMEN

*Malformación de la vena de Galeno con manifestaciones atípicas: Aportación de un caso*

Se describe un niño de 6 años con aneurisma de la vena de Galeno diagnosticado por angiografía carotídea. Se indica la manifestación no usual de hemiparesia alternante asociada a fiebre en una ocasión y con reacción anafiláctica a la inyección de ATS en otra.

Se discute la probable patogenia de las manifestaciones típicas y se insiste en que deben hacerse angiografías más frecuentes en niños de forma que las lesiones vasculares no corrientes puedan ser diagnosticadas prontamente.

#### REFERENCES

- Agee, O. F., Musella, R., Tweed, C. G. (1969) 'Aneurysm of the great vein of Galen: report of two cases.' *J. Neurosurg.*, **31**, 346.
- Denny-Brown, D. (1951) 'The treatment of recurrent cerebro-vascular symptoms and the question of vasospasm.' *Med. Clin. N. Amer.*, **35**, 1457.
- Meyer, J. S. (1957) 'The cerebral collateral circulation. 2. Production of cerebral infarction by ischemic anoxia and its reversibility in the early stages.' *Neurology (Minneapolis)*, **7**, 567.
- Gold, A. P., Ransohoff, J., Carter, S. (1964) 'Vein of Galen malformation.' *Acta neurol. scand.*, Suppl. 11.
- Gowriedevi, M., Raja Reddy, D. (1971) 'Arteriovenous malformation involving the vein of Galen: a case report.' *Neurology (India)*, **19**, 48.
- Marshall, J. (1965) *The Management of Cerebrovascular Disease*. Boston: Little, Brown & Co. p. 121.
- Nelson, D. A., Jeffreys, W. H., McDowell, F. (1958) 'Effects of induced hyperthermia on some neurological disease.' *Arch. Neurol. Psychiat. (Chic.)*, **79**, 31.
- McDowell, F. (1959) 'The effects of induced hyperthermia on patients with multiple sclerosis.' *J. Neurol. Neurosurg. Psychiat.*, **22**, 113.
- Pool, J. L., Potts, D. G. (1965) 'Vein of Galen malformations.' In: *Aneurysms and Arteriovenous Anomalies of the Brain: Diagnosis and Treatment*. New York: Hoeber-Harper, p. 374.
- Poppen, J. L., Avman, N. (1960) 'Aneurysms of the great vein of Galen.' *J. Neurosurg.*, **17**, 238.
- Solomon, G. E., Hilal, S. K., Gold, A. P., Carter, S. (1970) 'Natural history of acute hemiplegia of childhood.' *Brain*, **93**, 107.