

*From the Department of Ophthalmology,
University of Göteborg, S-413 45 Göteborg, Sweden*

GENUINE, RELATIVE, BINASAL HEMIANOPIA
Report of a case

BY

L. FRISÉN

Binasal hemianopia signifies bilateral lesions of non-crossing visual pathway nerve fibers. Tönnis (1956) observed this sign three times in a series of 3,033 intracranial tumours. Binasal hemianopia is thus a very rarely encountered visual field defect. It is usually associated with intracranial tumours causing an increased intracranial pressure, or optochiasmatic arachnoiditis (Cushing & Walker 1912, Lutz 1928, François 1947, Staub 1952, Thierry et al. 1970).

Binasal hemianopia usually starts as unequal, binasal lower quadrant defects, which progress to unsymmetrical, commonly irreversible hemianopias. Internal isopters are less affected than peripheral ones. The temporal fields are often involved as well. The defect pays little, if any, respect to the vertical meridian. Hence, this is not a genuine hemianopia. Binasal hemianopia thus in many ways differs from bitemporal hemianopia seen in selective interference with crossing nerve fibers. This indicates not only that the non-crossing nerve fiber sets nowhere run as exposed as the crossing ones do in the middle of the optic chiasm, but also that the pathophysiological processes behind the two types of field defect are dissimilar.

The following case report shows that there also exists another kind of binasal hemianopia. viz. a reversible, relative, genuinely hemianopic type. Being analogous to relative bitemporal hemianopia, it is considered explicable in similar terms.

Received June 21, 1971.

Case Report

Except for a mild meningitis in infancy and a proneness towards stumbling, Stefania B. (journal No. 59 11 20) had always been in good health. At the age of eleven, she began to suffer from diffuse headaches. Spells of nausea appeared a few months later and her general condition began to deteriorate. She also began to complain of periodic dimness of vision and diplopia and she was observed to favour a tilted position of her head. A few weeks later she was found to have bilateral papilledema. Echo-encephalography suggested internal hydrocephalus. She was then referred from her South-European home to the Department of Neurosurgery at Sahlgrenska Sjukhuset in Göteborg, Sweden.

On arrival, the neurological examination disclosed nothing abnormal besides a failing attention, torticollis and papilledema.

The neuro-ophthalmological examination met with very good cooperation in spite of the patient's low age and her impaired general condition. There were no gross disturbances of the ocular motility. Diplopia glasses uncovered a weakness of the right superior rectus muscle, accounting for an unobtrusive torticollis. The pupils were equally large and reacted normally to light, including the swinging flash-light. The corneal sensitivity was normal.

There was bilateral papilledema. The right optic disc was hyperemic and poorly demarcated, protruding one to two diopters. There were several splinter hemorrhages around the disc but no white spots or signs of gliosis. The veins were wide. The fundus was otherwise normal. The left optic disc showed similar but less pronounced changes; the protrusion was hardly measurable.

The visual acuity was 6/6 O.U. unaided. The visual field periphery was normal to the confrontation test but two-hand confrontation, presenting one hand in each half of the monocular visual field, disclosed a notably impaired perception in the nasal half-field with a clear-cut and abrupt transition in the vertical plane through the visual axis. The perception of the colour of a red pen cap was similarly disturbed.

The visual fields were then examined in the Haag-Streit Goldmann perimeter. This examination confirmed the relative, binasal hemianopia respecting the vertical meridian (Fig. 1, open symbols). The apparently contracted periphery of the left visual field was believed to be due to fatigue, this being the last isopter explored. As was mentioned above, the confrontation periphery was full and the swinging flash-light test negative.

The neuro-ophthalmological findings were considered to indicate an expansive process in the chiasmal area. The following examinations showed, however, that the primary lesion occupied the posterior cranial fossa.

Echo-encephalography indicated a low-degree dilation of the ventricular system and a possible dislocation to the right. There were no convincing localizing signs in the electroencephalogram. Skull X-rays disclosed an unusually large posterior fossa. There were no signs of decalcification in the sellar region or elsewhere. Pneumo-encephalography revealed a downward dislocation of the cerebellar tonsils to the level of C_{ii} and compressed pontine and interpenduncular cisterns. Very little gas passed into the ventricular system, necessitating ventriculography. This showed a moderate, symmetrical dilation of the third and lateral ventricles. The aqueduct was kinked and very little gas passed into the fourth ventricle.

With a tentative diagnosis of a vermis tumour, the patient was then subjected to surgery. The preparatory ventricular puncture revealed a high intraventricular pressure. The posterior fossa was then entered through the midline neck route and a partly cystic

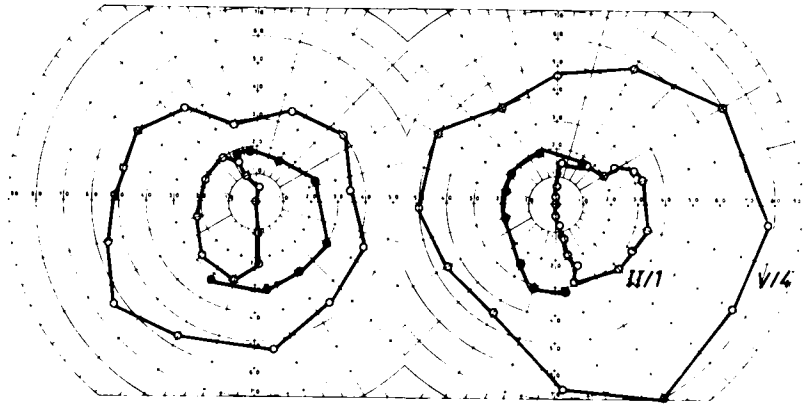


Fig. 1.

Perimetric findings. The pre-operative observations are drawn with open symbols and the postoperative central changes are inlaid with filled symbols. The stimuli characteristics are indicated in the figure (Haag-Streit Goldmann perimeter).

vermis tumour of mandarine size was immediately encountered. The tumour, a spongioblastoma, was removed *in toto*.

On the following night, there was a respiratory arrest, necessitating ventricular puncture and re-exploration. An extradural hematoma was evacuated. Thereafter, recovery was largely uneventful.

The neuro-ophthalmological examination was repeated two weeks later. The papilledema was then slightly less prominent and the visual fields were normal to confrontation. Perimetry now showed normal isopters (Fig. 1, filled symbols). There was no diplopia.

The papilledema decreased slowly during the following weeks. The optic discs were considered normal five weeks following surgery. The visual fields then showed no signs of abnormality (these latter examinations were performed by Dr. Guiseppe Schisano, who kindly communicated the results).

This, then, is a case of relative, genuine, binasal hemianopia in a child with internal hydrocephalus due to a giant vermis tumour. Removal of the tumour restored the visual fields to normal. The limited ventricular dilation, and the quite moderate papilledema are noteworthy features as concerns the production of the visual field defects, as will be discussed in the following.

Discussion

Binasal hemianopias of the classical irregular type have been attributed to retinal diseases, glaucoma, retrobulbar neuritis, intracranial gummata, intoxica-

tions, arteriosclerosis, hysteria, etc. (Lutz 1928, Harrington 1964). Among the 52 cases with an anatomically verified diagnosis culled from the literature by François (1947), 17 presented optochiasmatic arachnoiditis as an acceptable explanation of their visual field defect. This will not be further discussed here. The remaining 35 cases suffered from intracranial hypertension secondary to tumour (mostly cerebellar, ponto-cerebellar and intraventricular tumours). About one half (18) of these tumours were supratentorial.

The direct cause of classical binasal hemianopia in cases of intracranial tumours is not obvious. Earlier notions that it is due to interference with the lateral parts of the optic chiasm, for instance by pressure against the internal carotid arteries, are refuted by the fact that non-crossing nerve fibers intermingle with crossing ones in the lateral parts of the chiasm. A lateral chiasmal lesion actually produces a homonymous type of defect (Enoksson 1965, Hoyt 1969). Theoretically, bilateral retrochiasmatic lesions might be operative but there seems to be no evidence of such mechanisms (Traquair 1947, Dubois-Poulsen 1952). Lesions responsible for binasal hemianopia are therefore most probably related to the optic nerves.

The site and nature of the optic nerve lesions have been discussed for years. Naturally, intracranial lesions come to mind first. It may then seem significant that more than one half of previously reported cases were known to display internal hydrocephalus with a distended third ventricle. A ballooning third ventricle can be imagined to displace the *circulus arteriosus* and the intracranial optic nerves so as to produce an impaired circulation and/or mechanical deformation irregularly interfering mainly with non-crossing nerve fibers. These fibers occupy the temporal aspects of the intracranial optic nerves. Although this mechanism might be plausible in some cases (Dubois-Poulsen 1952), it does not illuminate the pathophysiology in cases of binasal hemianopia, where distension of the third ventricle was not observed. Moreover, a distended third ventricle may be associated with bitemporal or altitudinal hemianopia, although the most common finding is normal fields (Traquair 1949, Hughes 1954, Ruf 1956, Huber 1961). This variability does not disprove a possible etiological role of a distended median ventricle, since a variability in signs may equally well reflect the occurrence of morphological whims. The irregular, absolute type of field defect of classical binasal hemianopia indicates that large-caliber axons, serving the visual field periphery, are more disturbed than small-caliber ones, serving the center of the field. Such signs are not commonly observed in compression of an intracranial optic nerve (Traquair 1949, Hughes 1954). A search for more likely loci of interference is thus appropriate. The extremely frequent association between binasal hemianopia and bilateral papilledema might be significant. Although papilledema *per se* is unable to explain visual field defects of this kind (Lutz 1928), secondary atrophy of the optic nerve head is well known to produce a seemingly equivalent, predominantly nasal defect with a

similar natural history. As the overwhelming majority of previously reported tumour cases presented bilateral papilledema, mostly of long duration, it appears very likely that atrophic papillary changes are causally related to the visual field defect (Cushing & Walker 1912). The view that binasal hemianopias encountered in neurosurgical practice are caused by secondary optic atrophy or chronic atrophic papilledema, seems both well grounded and widely accepted (Traquair 1947, Hughes 1954, Hoyt 1969).

Whereas secondary optic atrophy may thus explain the absolute and irregular binasal field defects of a majority of cases with increased intracranial pressure, this mechanism appears improbable in the present case because signs of atrophy were lacking. The relative and regular binasal hemianopia observed here also obviously differs from the classical type. The relative field defect seems to be explicable only as the sign of a mild and diffuse conduction defect affecting mainly small-caliber axons of the two sets of non-crossing nerve fibers. Such a conduction disturbance is held responsible for the relative bitemporal hemianopia often encountered in chiasmatic interference with crossing fibers (Hoyt 1969).

Hughes (1954) states, presumably on theoretical grounds, that a *relative* binasal hemianopia indicates lateral chiasmal compression. As was mentioned above, lateral chiasmal compression would rather be expected to produce a homonymous type of defect. Bilateral intracranial optic nerve lesions, related to the distended third ventricle, seem much more probable. Lateral kinking of the nerves against more rigid structures, lateral grooving by the internal carotids or the anterior cerebral arteries, or localized circulatory impairment might be operative, singly or in combination. Anatomical features suggest a particularly fragile vascular supply of the temporal aspect of the intracranial optic nerve, i. e. that part of the nerve carrying non-crossing fibers (François, Neetens & Colette 1958). Although clinical evidence of such a particular vulnerability seems to be lacking, the lower uncrossed fibers actually often being considered the least vulnerable of all fibers, this might be a case in point. Of course, a peculiar vascular and/or neuronal arrangement cannot be excluded; in fact, the operation of highly unusual factors, e. g. optic nerve diastasis, would seem likely in view of the exceptional rarity of this kind of binasal hemianopia. The literature seems to mention only a few possibly equivalent cases, e. g. the cases of binasal hemiachromatopia or hemiambyopia reviewed by Lutz (1928). None of these had an anatomically verified diagnosis.

Although the exact mechanism behind the visual field defect observed here remains open to speculation, this case shows that the selective interference with the two sets of non-crossing visual pathway neurons is possible and that the ensuing signs then may be analogous to those classically seen in a minimal disturbance of the crossing ones.

Summary

A case of genuine, relative, binasal hemianopia, relieved by the surgical removal of a midline cerebellar tumour, is described. The visual field findings are compatible with an intracranial, mild and selective conduction disturbance of non-crossing optic nerve fibers. The pathogenetic mechanism therefore differs from that of classical binasal hemianopia, which is usually attributed to bilateral secondary optic atrophy.

Acknowledgement

Professor Gösta Norlén, M.D. and Luigi Pellettieri, M.D., at the Department of Neurosurgery, kindly allowed me to have access to their records in preparing the case report.

References

- Cushing, H. & Walker, C. B. (1912) Distortions of the visual fields in cases of brain tumour: binasal hemianopia. *Arch. Ophthalm.* 41, 559-598.
- Dubois-Poulsen, A. (1952) *Le Champ Visuel. Topographie Normale et Pathologique des Sensibilités*. Masson et Cie, Paris.
- Enoksson, P. (1965) Perimetry in neuro-ophthalmological diagnosis. *Acta ophthalm.* (Kbh.), Suppl. 82.
- François, J. (1947) L'hémianopsie binasale. *Ophthalmologica* 113, 321-343.
- François, J., Nectens, A. & Colette, J. M. (1958) Vascularization of the primary optic pathways. *Brit. J. Ophthalm.* 42, 65-80.
- Harrington, D. O. (1964) *The Visual Fields. A Textbook and Atlas of Clinical Perimetry*. 2. ed. C. V. Mosby Co., St. Louis.
- Hoyt, W. F. (1969) Correlative functional anatomy of the optic chiasm. *Clin. Neurosurg.* 17, 189-208.
- Huber, A. (1961) *Eye Symptoms in Brain Tumours*. C. V. Mosby Co., St. Louis.
- Hughes, B. (1954) *The Visual Fields. A Study of the Applications of Quantitative Perimetry to the Anatomy and Pathology of the Visual Pathways*. Blackwell Scientific Publications, Oxford.
- Lutz, A. (1928) Über binasale Hemianopsie. Eine vergleichende Zusammenstellung von 84 Mitteilungen in der Literatur und Beschreibung zweier eigener Beobachtungen. *Albrecht v. Graefes Arch. Ophthalm.* 119, 423-487.
- Ruf, H. (1956) Atypischer Gesichtsfeldausfall bei einem Acusticusneurinom. *Ber. dtsh. ophthalm. Ges.* 59, 52.
- Staub, W. (1952) Über die binasale Hémianopsie. *Acta ophthalm.* (Kbh.) 30, 229-252.
- Thierry, A., Hanard, P., Leconte des Floris, R., Steimle, R., Rollin, J. & Jacquet, G. (1970) A propos d'une observation d'hémianopsie binasale par arachnoidite post-infectieuse. *Rev. Oto-neuro-ophthal.* 42, 116-120.

- Traquair, H. M.* (1949) *An Introduction to Clinical Perimetry*. 6. ed. II. Kimpton, London.
- Tönnis, W.* (1956) Augensymptome bei 3033 Hirngeschwülsten. *Ber. dtsh. ophthal. Ges.* 59, 6-27.