

Carotid Aneurysm and Contralateral Carotid Stenosis with Successful Surgical Treatment of Both Lesions

Case Report

HAROLD D. PORTNOY, M.D., AND ANTHONY AVELLANOSA, M.D.

Department of Surgery (Neurosurgery), Pontiac General Hospital, Pontiac, Michigan, and the Department of Neurosurgery, Wayne State University School of Medicine, Detroit, Michigan

IN the geriatric population the occurrence of carotid stenosis or occlusion is relatively common, as is that of intracranial saccula aneurysm. The combination of extracranial carotid stenosis or occlusion and intracranial aneurysm, however, appears to be rare. In review of the English literature, we could find only nine previously recorded cases.^{9,15,25,31} In only two cases were both lesions symptomatic. In one case the patient died following rupture of the aneurysm, no surgical treatment having been instituted for either lesion.¹⁵ In the other instance, the patient died after a successful endarterectomy, because of recurrent hemorrhage from the aneurysm.²⁵

The following case report is of an elderly woman who had a right internal carotid artery aneurysm and a left internal carotid artery stenosis, both lesions producing symptoms and both lesions successfully treated surgically. The association in this patient of atherosclerosis, the "hydraulic" effect of a contralateral "tight" carotid stenosis, and congenitally anomalous circle of Willis introduces the question of the relative significance of these factors in the formation of saccular aneurysm.

Case Report

A 69-year-old white woman was in good health until mid-October, 1968, when she experienced fever, generalized weakness, shortness of breath, right-sided neck stiffness, anorexia, epigastric distress, and repeated episodes of vomiting. She was admitted to another hospital on October 21, where no abnormality of the nervous system was noted. Three days later she had a temperature of 101°F, meningismus, positive Kernig's sign, and clinical evidence of con-

solidation in both lungs. The diagnosis was viral pneumonia with meningitis; she was treated with wide spectrum antibiotics, improved, and was discharged on November 6.

The patient was admitted to another local hospital on November 17, with headache, meningismus, slight paresis of the right medial rectus, paresis of upward gaze, slight bilateral deafness, right ptosis, and a right pupil larger than the left but reactive to light and accommodation. Grossly bloody cerebrospinal fluid obtained at lumbar puncture was xanthochromic on centrifugation; it contained 16,100 red blood cells (RBC) and 79 white blood cells (WBC) per cu mm (64 lymphocytes and 15 polymorphonuclear cells); the protein content was 161 mg% and sugar content, 63 mg%. Electroencephalography on November 20 indicated "the presence of a deep level or subcortical disturbance with right-sided preponderance." Blood pressures at this time varied from 140 to 180 systolic, and the patient was placed on reserpine and phenobarbital. Bilateral carotid angiography on November 21 demonstrated a right internal carotid artery aneurysm (Fig. 1 *left*) and a left internal carotid artery stenosis of 90% (Fig. 1 *right*). In addition, there was partial stenosis of the right internal carotid artery best seen on a subsequent brachial angiogram (Fig. 2 *left*), hypoplasia of the left anterior cerebral artery, and evidence that the right posterior cerebral artery originated from the internal carotid artery (Fig. 1 *left*). The following day the patient suddenly developed right-sided weakness and dysphasia while walking. The blood pressure was 130 systolic when she was returned to bed but prior to this, the blood pressure had not been recorded lower than 140 systolic. She improved following discontinuation of the reserpine and phenobarbital

Received for publication April 15, 1969.

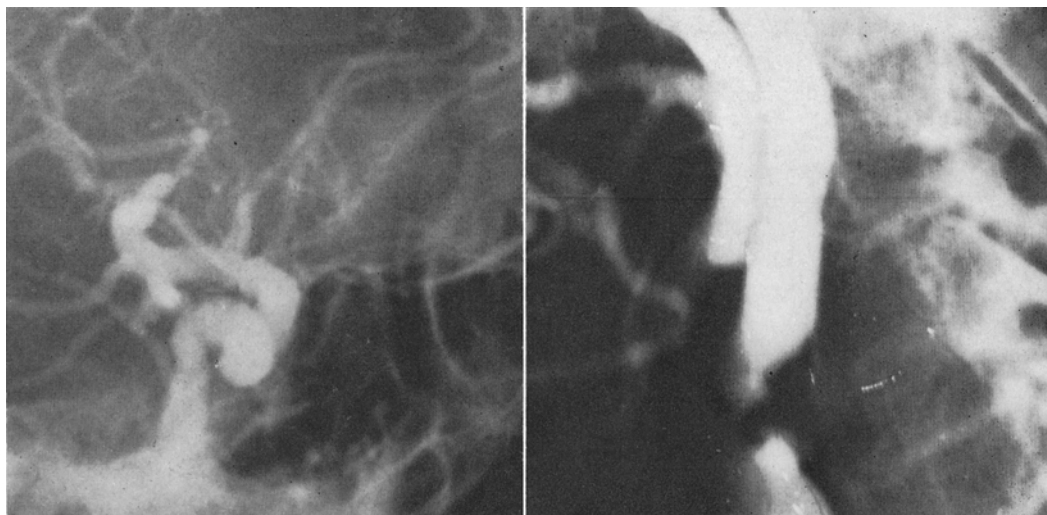


FIG. 1. *Left:* Right lateral carotid angiogram showing a bilobed aneurysm of the internal carotid artery at the origin of the posterior cerebral artery. The posterior communicating artery takes origin from the internal carotid artery. *Right:* Left lateral carotid angiogram showing the 90% stenosis at the origin of the internal carotid artery.

and restoration of blood pressure, but had a residual nocturnal confusion and disorientation.

Examination. On November 27, the patient was transferred to Pontiac General Hospital for definitive therapy. Normal values for the following laboratory tests were noted on admission: hemoglobin, RBC, WBC, urinalysis, syphilis (VDRL), serum cholesterol, calcium, inorganic phosphorus, total bilirubin, albumin, total protein, uric acid, blood urea nitrogen (BUN), lactate dehydrogenase (LDH), alkaline phosphatase, serum glutamic oxaloacetic transaminase (SGOT), prothrombin time, and bleeding time. Fasting blood sugar was 125 mg% (slightly elevated). The electroencephalogram showed "evidence of generalized superficial and deep level disturbance without focal abnormality." The electrocardiogram revealed a normal sinus rhythm and suggested left ventricular hypertrophy. When left carotid compression was carried out for 1 minute on November 29, the patient complained only of a slight amount of giddiness.

First Operation. On December 12, bilateral brachiovertebral angiography followed by the left carotid endarterectomy was carried out under general anesthesia. Following angiography, which demonstrated a hypoplastic right divisional branch of the basilar artery, the right brachial arterial can-

nula was connected to a blood pressure transducer for continuous measurement during surgery. Technical difficulties precluded measurement of pressures above and below the stenosis. Jugular bulb venous pH and gas studies were carried out. Initial studies disclosed a pH of 7.35; a $p\text{CO}_2$ of 50 mm Hg; and a $p\text{O}_2$ of 39 mm Hg. Following occlusion of the internal carotid artery for 1 minute, the pH was 7.35; the $p\text{CO}_2$ was 55 mm Hg; and the $p\text{O}_2$ was 36 mm Hg. Since there had been no significant change in $p\text{O}_2$, it was felt that the patient could tolerate temporary occlusion of the vessel during endarterectomy. This was done. On restoration of circulation after removal of the plaque, the pH was 7.38; the $p\text{CO}_2$ was 54 mm Hg; and the $p\text{O}_2$ was 34 mm Hg.

First Postoperative Course. Immediately postoperatively the patient was fully awake and responsive with no evidence of weakness. Right carotid compression was carried out 2 days later and syncope associated with a slight cardiac slowing ensued after 15 sec. Carotid compression on subsequent days yielded similar results. Following atropine block and right carotid compression, the patient did not lose consciousness but did become confused and disoriented after 20 to 25 sec. During these several days the ptosis improved. Because of failure to tolerate right carotid compression, it was decided to

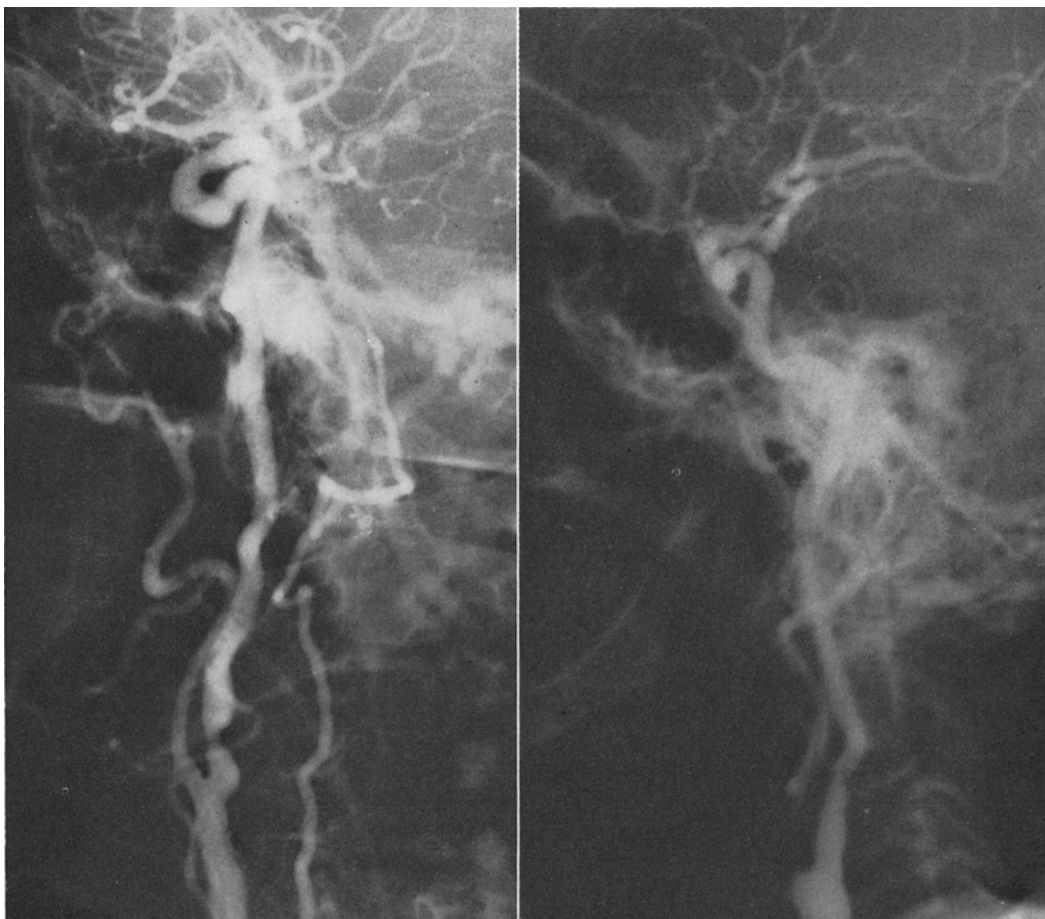


FIG. 2. *Left:* Right brachiovertebral angiogram demonstrating stenosis of the carotid bulb and adjacent internal carotid artery. A hypoplastic right vertebral artery is also present. *Right:* Left carotid angiogram obtained following left carotid endarterectomy. Note restoration of the lumen at the origin of the internal carotid artery.

reinvestigate the carotid circulation by angiography on December 12. Left carotid angiography demonstrated that the lumen had been restored (Fig. 2 *right*). In addition, on left carotid angiography with right carotid compression, the contrast medium crossed into the right anterior cerebral artery. It was felt that complete occlusion of the right internal carotid artery would probably result in hemiplegia²; therefore, following the angiogram, the blood pressure was slowly dropped to 88/66 by use of Arfonad to determine if hypotension could be tolerated. The state of consciousness and motor function of the patient was continuously determined during the hypotensive episode. The patient tolerated the procedure well. During the night of December 14 the patient became confused and developed increased

right ptosis and it was felt that the aneurysm had leaked again.

Second Operation. A right frontotemporal craniotomy was carried out on December 17 using Mannitol and hypothermia to 31.5°C. After opening the dura the frontal and temporal lobes were elevated, and the chiasmatic cistern was opened and allowed to drain. The internal carotid artery was brought into view; filaments of arachnoid and adhesions about the internal carotid artery were freed and the aneurysm identified. The fundus of the aneurysm was beneath the edge of the tentorium. An atheromatous plaque was clearly seen involving the first millimeter of the neck of the aneurysm as it emerged from the internal carotid artery. The posterior communicating artery could be easily delineated from the neck of the an-

eurysm. A Scoville clip was then eased about the neck of the aneurysm and slowly closed in such a manner as to be placed inferior to the tip of the atheromatous area. As the clip closed, the aneurysm ruptured and bled transiently. At the time of the approach and clipping of the aneurysm, the blood pressure was between 90 and 100 mm Hg systolic, but immediately after, the blood pressure jumped to 140 mm Hg systolic, but there was no further bleeding. The craniotomy was closed in the usual manner with care being taken to tent the dura and leave an adequate temporal craniectomy. An epidural drain was left in for 24 hours even though there was no unusual bleeding.

Second Postoperative Course. On the following day the patient was quite drowsy and confused. No weakness was noted, but there was a complete right third nerve palsy. The next day the right pupil returned to normal as did extraocular muscle function. The ptosis persisted. During the postoperative period the patient remained quite drowsy and confused but moved both sides well. Right carotid angiogram on December 26 showed that about 1 to 2 mm of the neck of the aneurysm were still present (Fig. 3). There was also a small epidural hematoma in the temporal area limited by the tenting sutures. On December 31 the patient became stuporous. The right temporal area was slightly fluctuant. Following aspiration of 10 cc of old blood, the patient became more alert and was generally improved. Right carotid angiogram on January 8, 1969, showed the epidural hematoma was smaller.

Progress thereafter was rapid and the patient was discharged on January 15. At the time of discharge she was alert and oriented except at night, when she became slightly confused and occasionally would have nocturnal enuresis. At the time of her last outpatient visit on April 3, 1969, she was no longer confused at night and was taking care of her grandchildren. Her neurological examination was normal except that she had considerable giddiness on compression of either carotid artery for 10 to 15 sec.

Discussion

Atherosclerotic cerebrovascular disease is present in a high percentage of individuals over the age of 60,^{12,20,34} and the incidence of saccular aneurysm is certainly not rare.

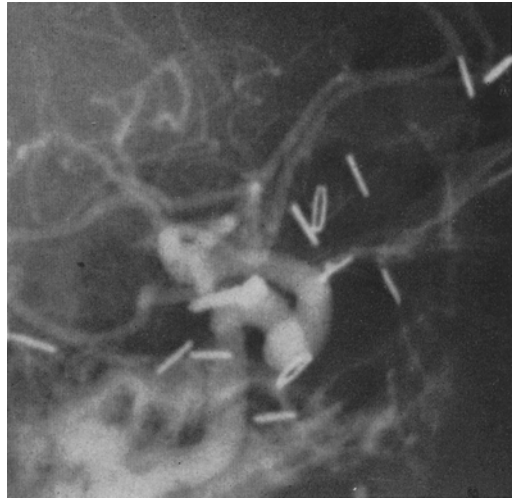


FIG. 3. Right carotid angiogram. A Scoville clip occludes all by 1 to 2 mm of the aneurysm neck.

McCormick and Nofzinger²¹ in an autopsy study of 7650 adults found that 32% of the 151 aneurysms discovered were in individuals over 60 years old. It is of particular interest, therefore, that the combination of saccular aneurysm and carotid artery stenosis is rare, especially when atherosclerosis has been suggested as one of the etiological factors in the development of saccular aneurysm.^{4, 28, 30, 32, 35}

Six of the nine previously reported cases of aneurysm associated with carotid artery stenosis or occlusion are mentioned in a paper by Gurdjian, *et al.*,⁸ in a table of concomitant angiographic findings in 205 cases of carotid artery stenosis. Follow-up¹¹ shows that five patients have done well while the sixth had a fatal rupture of the aneurysm. Gurdjian, *et al.*, also reported a 65-year-old man with a right internal carotid artery stenosis at the bifurcation, and right middle cerebral artery aneurysm; no further clinical data were presented.¹⁰

A case of Jaffe and McHenry¹⁵ was reported in detail and involved a 79-year-old Negro woman who, 10 years prior to an episode of subarachnoid hemorrhage, had developed an occlusion of the left internal carotid artery with contralateral weakness. At the time of investigation for the episode of subarachnoid hemorrhage, a right internal carotid artery aneurysm was demonstrated. No surgical intervention was carried out and the patient died from a subsequent hemorrhage.

Pool and Potts²⁵ describe a patient of Mount's with a left internal carotid artery aneurysm and contralateral internal carotid artery stenosis at the bifurcation. An endarterectomy was carried out successfully on the stenotic vessel, but the patient died subsequent to recurrent hemorrhage before planned surgical intervention for the aneurysm.

Somach and Shenkin³¹ briefly mention a patient with aneurysm who also had a concomitant narrowing of the left carotid artery. Complete angiographic studies after right carotid ligation were abandoned when introduction of a needle into the narrowed vessel produced transient aphasia and hemiplegia.

One other case of intracranial aneurysm and carotid stenosis has been seen by one of us (H.D.P.). This was a 69-year-old white man who was admitted for subarachnoid hemorrhage and left hemiparesis. Angiography demonstrated a right internal carotid artery aneurysm and 70% stenosis of the right internal carotid artery at the bifurcation. He was treated with bedrest over a period of 8 weeks, gradually improved, and at present is alive, well, and active. The neurological deficit appeared to be due to the ruptured aneurysm, although possibly the carotid stenosis was of significance.

The patient reported here is the only one to our knowledge who has been successfully treated surgically for both lesions.

While extracranial carotid artery disease is infrequently associated with aneurysm, it is not unusual for aneurysms to be grossly arteriosclerotic.¹⁴ Stehbens³² has been able to demonstrate arteriosclerotic defects in the media of cerebral arteries, primarily at bifurcations. Based on these findings and the altered dynamic flows found in patients with arteriosclerosis, he suggested that aneurysms may be formed from degenerative changes in the arterial wall. This theory could be applied to the development of the aneurysm reported in this case since an arteriosclerotic plaque was clearly seen in the neck of the aneurysm at surgery. In addition, altered flow dynamics were evident both angiographically and by the Matas (carotid compression) test.

The development of an aneurysm secondary to altered cerebral circulation due to occlusion of a carotid artery has been exper-

imentally demonstrated in rabbits by Hassler.¹³ This "hydraulic" theory has a clinical correlate in the cases reporting the development or enlargement of a second aneurysm following carotid ligation for the first ruptured aneurysm.^{7,9,16,17,22-24,27,31,33} One case of Somach and Shenkin³¹ and the case of Gurdjian, *et al.*,⁹ had carotid angiography demonstrating a previously normal vascular pattern. In all other instances, either there was no note as to whether complete angiography had been carried out at the time of the initial ligation, or it was specifically mentioned that only the vessel which had been subsequently ligated was studied. Because of the high incidence of multiple and frequently symmetrical aneurysms,^{3,5,18,19,21,26,36} it cannot be supposed that all of these cases represent the development of a new aneurysm subsequent to carotid ligation. The findings of only two verified cases of aneurysms developing subsequent to carotid ligation suggest that Hassler's experimental work on the rabbit is seen infrequently in clinical counterpart in man. This is further supported by the fact that only one case has been reported of an aneurysm developing subsequent to spontaneous contralateral carotid occlusion.¹⁵

Although the case presented here can be used as an example of the development of an acquired aneurysm on the basis of concomitant atherosclerosis and altered blood flow, support for the congenital theory of origin can likewise be raised by noting the associated congenital abnormalities of the circle of Willis.^{1,29,35,36} In this patient there was hypoplasia of the left anterior cerebral artery and right divisional branch of the basilar artery, and the right posterior cerebral artery originated from the internal carotid artery. It is not unreasonable to assume, therefore, that the aneurysm found at the junction of the right internal carotid and posterior cerebral arteries had a congenitally defective media.⁶ A possible explanation for the development and eventual rupture of the aneurysm could be as follows. The bifurcation of the internal carotid artery and posterior cerebral arteries had a congenitally defective media. With age and development of atherosclerosis the elastic fibers of the intima gradually disintegrated, allowing ballooning of the arterial wall and aneurysm formation. As the stenosis of the contralateral internal

carotid artery progressed, a compensatory increase in blood flow through the ipsilateral carotid artery occurred, causing further ballooning and rupture of the aneurysm.

As pointed out by Pool and Potts,²⁵ in this rare combination of carotid artery aneurysm associated with a contralateral carotid stenosis, the treatment of choice is first to relieve the stenotic vessel by endarterectomy, and subsequently to treat the aneurysm. In our case, carotid compression testing and angiography with carotid compression suggested that the patient would not have tolerated right carotid ligation,² thus leaving intracranial clipping of the aneurysm as the only logical alternative.

Summary

We have reported the case of a 69-year-old woman who had a subarachnoid hemorrhage associated with right third nerve involvement. Angiography demonstrated a right internal carotid artery aneurysm, left carotid stenosis, fetal origin of the right posterior cerebral artery, and hypoplastic left anterior cerebral artery. Following a hypotensive episode in the hospital, the patient developed a transient right hemiparesis. She was successfully treated by left carotid endarterectomy and subsequent intracranial clipping of the aneurysm. The contributions of coexisting atherosclerosis, congenital abnormalities of the circle of Willis, and the "hydraulic" effect of the carotid stenosis to the development of the aneurysm have been discussed.

References

- ALPERS, B. J., and BERRY, R. G. Circle of Willis in cerebral vascular disorders. The anatomical structure. *Archs Neurol., Chicago*, 1963, 8:398-402.
- BEATTY, R. A., and RICHARDSON, A. E. Predicting intolerance to common carotid artery ligation by carotid angiography. *J. Neurosurg.*, 1968, 28:9-13.
- BIGELOW, N. H. Multiple intracranial arterial aneurysms. An analysis of their significance. *Archs Neurol. Psychiat., Chicago*, 1955, 73:76-99.
- CARMICHAEL, R. The pathogenesis of non-inflammatory cerebral aneurysms. *J. Path. Bact.*, 1950, 62:1-19.
- CHASON, J. L., and HINDMAN, W. M. Berry aneurysms of the circle of Willis. Results of a planned aneurysm study. *Neurology, Minneap.*, 1958, 8:41-44.
- FORBUS, W. D. On the origin of miliary aneurysms of superficial cerebral vessels. *Bull. Johns Hopkins Hosp.*, 1930, 47:239-284.
- GERMAN, W. J., and BLACK, S. P. W. Cervical ligation for internal carotid aneurysms. An extended follow-up. *J. Neurosurg.*, 1965, 23:572-577.
- GURDJIAN, E. S., HARDY, W. G., LINDNER, D. W., and THOMAS, L. M. Diagnostic evaluation and treatment. Symposium: Occlusive cerebrovascular disease. *Trans. Am. Acad. Ophthalm. Otolaryng.*, 1962, 66:149-165.
- GURDJIAN, E. S., LINDNER, D. W., and THOMAS, L. M. Experiences with ligation of the common carotid artery for treatment of aneurysms of the internal carotid artery. With particular reference to complications. *J. Neurosurg.*, 1965, 23:311-318.
- GURDJIAN, E. S., and THOMAS, L. M. Evaluation and indications for surgery in extracranial cerebrovascular disease. *J. Neurosurg.*, 1967, 26:235-243.
- GURDJIAN, E. S. Personal communication, 1969.
- HASS, W. K., FIELDS, W. S., NORTH, R. R., KRICHEFF, I. I., CHASE, N. E., and BAUER, R. B. Joint study of extracranial arterial occlusion. II. Arteriography, techniques, sites, and complications. *J. Am. med. Ass.*, 1968, 203:961-968.
- HASSLER, O. Experimental carotid ligation followed by aneurysmal formation and other morphologic changes in the circle of Willis. *J. Neurosurg.*, 1963, 20:1-7.
- HOUSEPIAN, E. M., and POOL, J. L. Systematic analysis of intracranial aneurysm from the autopsy file of Presbyterian Hospital, 1914-1956. *J. Neuropath. exp. Neurol.*, 1958, 17:409-423.
- JAFFE, M. E., and MCHENRY, L. C. Cerebral aneurysm following spontaneous carotid occlusion. *Neurology, Minneap.*, 1968, 18:1012-1014.
- JEFFERSON, G. Discussion of Norlen's paper. *Proc. R. Soc. Med.*, 1952, 45:300-301.
- JOHNSON, R. Discussion of Norlen's paper. *Proc. R. Soc. Med.*, 1952, 45:301-302.
- KING, G., SLADE, H. W., and CAMPOY, F. Bilateral intracranial aneurysms. *Archs Neurol. Psychiat., Chicago*, 1954, 71:326-336.
- LOCKSLEY, H. B. Report of the cooperative study of intracranial aneurysms and subarachnoid hemorrhage. Section V. Part I. Natural history of subarachnoid hemorrhage, intracranial aneurysms, and arteriovenous malformations based on 6,368 cases in the cooperative study. *J. Neurosurg.*, 1966, 25:219-239.
- MARTIN, M. J., WHISNANT, J. P., and SAYRE, G. P. Occlusive vascular disease in the extracranial cerebral circulation. *Archs Neurol., Chicago*, 1960, 3:530-538.
- MCCORMICK, W. F., and NOFZINGER, J. D. Saccular intracranial aneurysms. An autopsy study. *J. Neurosurg.*, 1965, 22:155-159.
- NISHIOKA, H. Report on the cooperative study of intracranial aneurysms and subarach-

- noid hemorrhage. Section VIII, Part I. Results of the treatment of intracranial aneurysms by occlusion of the carotid artery in the neck. *J. Neurosurg.*, 1966, 25:660-682.
23. NOFZINGER, J. D., BRITT, L. G., MURPHY, F., and PATE, J. W. Unusual treatment of an intracranial aneurysm contralateral to a previous common carotid ligation. *J. Neurosurg.*, 1965, 22:182-184.
 24. NORLEN, G. The pathology, diagnosis and treatment of intracranial saccular aneurysms. *Proc. R. Soc. Med.*, 1952, 45:291-298.
 25. POOL, J. L., and POTTS, D. G. *Aneurysms and arteriovenous anomalies of the brain. Diagnosis and treatment.* New York: Harper & Row, 1965, 463 pp.
 26. POPPEN, J. L., and FAGER, C. A. Multiple intracranial aneurysms. *J. Neurosurg.*, 1959, 16:581-589.
 27. POPPEN, J. L., and FAGER, C. A. Intracranial aneurysms. Results of surgical treatment. *J. Neurosurg.*, 1960, 17:283-296.
 28. RICHARDSON, J. C., and HYLAND, H. H. Intracranial aneurysms. A clinical and pathological study of subarachnoid and intracerebral hemorrhage caused by berry aneurysm. *Medicine, Baltimore*, 1941, 20:1-83.
 29. RIGGS, H. E., and RUPP, C. Variation in form of circle of Willis. Relation of variations to collateral circulation. Anatomic analysis. *Archs Neurol., Chicago*, 1963, 8:8-14.
 30. SMITH, D. E., and WINDSOR, R. B. Embryologic and pathogenic aspects of the development of cerebral saccular aneurysms. In: *Pathogenesis and treatment of cerebrovascular disease.* Fields, W. S., Ed., Springfield, Ill.: Charles C Thomas, 1961, 562 pp. (See chapter 15.)
 31. SOMACH, F. M., and SHENKIN, H. A. Angiographic end-results of carotid ligation in the treatment of carotid aneurysms. *J. Neurosurg.*, 1966, 24:966-974.
 32. STEHBENS, W. E. Histopathology of cerebral aneurysms. *Archs Neurol., Chicago*, 1963, 8:277-285.
 33. TINDALL, G. T., GOREE, J. A., LEE, J. F., and ODOM, G. L. Effect of common carotid ligation on size of internal carotid aneurysms and distal intracarotid and retinal artery pressures. *J. Neurosurg.*, 1966, 25:503-511.
 34. TOOLE, J. F., and PATEL, A. N. *Cerebrovascular disorders.* New York: McGraw-Hill, 1967, 280 pp.
 35. WALKER, A. E., and ALLEGRE, G. W. The pathology and pathogenesis of cerebral aneurysms. *J. Neuropath. exp. Neurol.*, 1954, 13:248-259.
 36. WILSON, G., RIGGS, H. E., and RUPP, C. The pathologic anatomy of ruptured cerebral aneurysms. *J. Neurosurg.*, 1954, 11:128-134.