

*Congenital heart disease with sudden onset of  
convulsions and coma*

C. L. Witzleben, M.D., and Phillip Dodge, M.D.

ST. LOUIS, MO.

THIS CAUCASIAN male child was first seen at Cardinal Glennon Memorial Hospital at the age of 5 weeks with the chief complaint of cyanosis, initially noted at 4 weeks of age. The date of birth was April 30, 1967. He was born after an uncomplicated pregnancy to a 20-year-old gravida 2, para 2 woman. The family history was remarkable in that one maternal aunt was said to have died from Bright's disease, and both maternal and paternal grandmothers were known to have diabetes mellitus. Clinical evaluation, including cardiac catheterization, resulted in the opinion that the patient had a truncus arteriosus which gave rise to one large pulmonary vessel that divided into right and left branches.

The child subsequently had an anastomosis of the superior vena cava to the right pulmonary artery at the age of 10 weeks. He tolerated the procedure well and was discharged 3 weeks later, on Aug. 1, 1967, in good condition.

Evaluation 4 months later showed that his condition had stabilized, except for occasional severe cyanotic episodes. He weighed 16 pounds, 4 ounces, and his activity and exercise tolerance had improved. He was a well developed cyanotic infant

in no apparent distress. There was a grade I, continuous murmur over the pulmonic area. Peripheral pulses were normal. The second heart sound was single and accentuated. Electrocardiograms showed right atrial and ventricular hypertrophy. Roentgenographically, the heart size was at the upper limit of normal. There was good pulmonary vascularity, especially on the right side. Hemoglobin was 15.8 Gm. per 100 ml., and hematocrit was 51 per cent.

The patient was next seen at the age of 16 months, on June 8, 1968, because of convulsions which had occurred approximately 12 to 24 hours prior to admission. There was no history of previous seizures. It was stated that he had fallen down the stairs approximately one month prior to this episode. For 3 days prior to admission, he had an upper respiratory infection without fever, vomiting, or diarrhea. The seizure involved the right upper and possibly right lower extremities, with the eyes deviated to the right. Physical examination revealed a pulse rate of 100 per minute, respiratory rate of 30, and temperature of 101° F. He was cyanotic and had a right hemiparesis. No cardiac murmurs were heard. A grade II/VI bruit was heard over the skull and forehead. Deep tendon reflexes were present and equal, bilaterally. No clonus was noted. There was weakness of the right upper extremity, and to a lesser extent, of the right lower extrem-

*From the Cardinal Glennon Memorial Hospital  
and the St. Louis University Medical School.*

*\*Sponsored by the Pediatric Pathology Club.*

ity. Facial muscles were not weak. Sensorium was apparently intact. The patient was irritable. Admission laboratory data revealed a hemoglobin of 14.2 Gm. per cent, hematocrit of 51 per cent, white blood cell count of 16,300 per cubic millimeter with 61 neutrophils, 37 lymphocytes, 1 monocyte, and 1 eosinophil. Cerebrospinal fluid protein was 18 mg. and sugar was 108 mg. per 100 ml. No cells were seen. Spinal fluid proved to be sterile. Blood sugar was 120 mg. per 100 ml. Throat culture was positive for *Diplococcus pneumoniae*. Multiple blood cultures were negative. Chest x-rays were initially unchanged. Skull film was negative. The child's course was febrile, and on the day following admission, Polycillin was given in the dose of 250 mg. every 6 hr. The anterior fontanelle became tense by the third day. Electroencephalogram demonstrated slight atypical quality with a moderate amount of masked delta activity and multilobular distribution. There was no overt focal spike or paroxysmal abnormality.

Right and left subdural and right ventricular taps were carried out on June 14, 1968. Ventriculogram revealed no abnormalities. Ventricular fluid showed sugar of 72 mg. and protein of 8 mg. per 100 ml. There were 7 white blood cells in the ventricular fluid, all lymphocytes. Six milliliters of subdural fluid obtained on the right were slightly xanthochromic, protein was 111 mg., and sugar was 46 mg. There were 553 white blood cells and 50,000 red blood cells per cubic milliliter in the subdural fluid with 70 per cent polymorphonuclear lymphocytes and 30 per cent lymphocytes. No fluid was obtained on the left. Cultures of both ventricular fluid and subdural fluid were negative.

Because of the possibility of subacute bacterial endocarditis, the patient was treated with penicillin and streptomycin on June 14, 1968, and 4 days later, the temperature had returned to normal. On June 17, 1968, the patient had 2 left-sided seizures, each lasting approximately 90 seconds. Hemoglobin was 14.2 Gm. per cent and hematocrit was 43 per cent. The patient

was breathing with difficulty, was lethargic, and responded minimally to pain. Pupils reacted sluggishly to light, and there was marked bilateral papilledema. Head circumference (48 cm) had not changed since admission. A lumbar spinal tap on June 25, 1968, revealed xanthochromic fluid containing 105 white cells and 2,188 red cells per cubic milliliter with 52 per cent neutrophils and 48 per cent lymphocytes. The opening pressure was 230 mm. Protein was 175 mg. and glucose was 120 mg. per 100 ml. Red cells were 75 per cent crenated. Culture was negative for bacteria. On June 25, 1968, the patient was clinically worse and very unresponsive, with limp extremities and a positive Babinski sign bilaterally. On the same day, the hemoglobin was 9.2 Gm. per cent and hematocrit was 36 per cent. There were anisocytosis, poikilocytosis, and target cells. The patient continued in this condition until death on June 28, 1968.

#### DISCUSSION

DR. PHILLIP DODGE.\* The essence of today's problem is what neurologic complication of this 16-month-old boy's truncus arteriosus resulted in his death. At 10 weeks of age, a right superior vena cava-right pulmonary artery shunt was performed, and one would gather from the subsequent x-rays that this was moderately effective in increasing flow through the lungs and improving the oxygen saturation of the blood. Nonetheless, it is important to note that from time to time, severe bouts of cyanosis occurred, and apparently the patient, although much better, was still not doing very well. Growth was only minimally retarded, which speaks for the efficacy of the shunt and the relatively good status of the patient. At 16 months of age, the patient had a right-sided convulsion which heralded the onset of his terminal illness. The infant had fallen down the stairs previously, but there was nothing to make us believe that this was a serious fall. But, in light of the neurologic problem, I suppose one has to keep this historical point in mind. About the time of admission, the patient had a cold, although fever was not prominent. The convulsions, as described, were followed by a right hemiparesis; whether this per-

\*Professor and Chairman of Pediatrics, Washington University of St. Louis.

sisted or not and how it fluctuated are not stated. This dysfunction on the right side could simply have been postictal and not indicative of a large destructive lesion of the left hemisphere. One would have been guided, I think, by the clinical progress.

RESIDENT PHYSICIAN. The original impression on admission was that this could have been a febrile convulsion with residual Todd's paralysis. The parents said that he had improved just about the time we had seen him, and he did improve a little over the next few days.

DR. DODGE. When one says Todd's postictal paralysis, one is really professing ignorance. We do not really know what it is. All we can say is that it is a transient paralysis of neuronal function and a not uncommon phenomenon following focal seizures in people of any age, but one that may be more marked in infants and children. Nine days after this first seizure, 2 additional seizures occurred. These did not involve the right but rather the left side. At the time of the first seizure, the spinal fluid was normal in every respect. I think this is a point which must be noted. Although there was fever and a positive throat culture for pneumococcus, there was really very little to document a focus of infection. The blood and spinal fluid cultures showed no growth, and for the moment, at least, I would be inclined to interpret these data as not supporting a diagnosis of systemic infection. It was decided to give Polycillin, however, and I suspect that, presented with the same series of events, I might have done likewise.

The additional laboratory tests included an abnormal electroencephalogram tracing, consistent with general cerebral dysfunction. The findings on ventricular and subdural tap, 4 days after admission, are of considerable interest. Fluid from the ventricular site was normal, except for a few lymphocytes. On the other hand, the subdural tap was positive for yellow fluid that contained 500 white and 50,000 red blood cells per cubic millimeter and a protein of 111 mg. per 100 ml. The cultures of both of these fluids were negative. Was this fluid, in fact, from the subdural space? It was obtained by so-called subdural puncture, but experience teaches that it is not too difficult to get fluid from the subarachnoid space by this procedure. The relatively low protein value would lead me to the conclusion that, in all probability, the fluid came from a subarachnoid lake. It differed in appearance from the lumbar and ventricular fluids, a point of importance. You remember that normally there is an increasing protein concentration gradient between the ventricular and

lumbar fluids. What is generally not appreciated is that the protein concentration of fluid from the subarachnoid space over the surface of the cerebral hemispheres is normally about two thirds to three fourths higher than that from the lumbar space. However, in the present case, the protein concentration from fluid obtained from over the surface of the brain was greater than could be explained by this fact, yet was not as high as one would expect from a subdural effusion. Also, it was pathologically stained with bilirubin pigment, and it contained an abnormal number of cells. These findings suggest that the responsible pathologic process was close to the subarachnoid space over the convexity of the cerebrum. Ten days later the lumbar spinal fluid resembled the surface fluid, suggesting that the subarachnoid spinal fluid pathways were in continuity. Increased intracranial pressure was indicated by the tense fontanelle, papilledema, and elevated spinal fluid pressure. But there was no deformity of the head, and the circumference was within normal limits. We are also told that the ventricular system was of normal size and not distorted. This might be an appropriate time to look at the x-ray films.

DR. BRODEUR.\* The ventriculogram revealed dilatation of the lateral ventricles of a greater degree than suggested by the slight separation of the sutures. Our findings indicate early increased intracranial pressure. There is no evidence of a midline shift, and we see no calcifications. Our conclusion is hydrocephalus due to obstruction, with evidence of communication to the basal cisterns.

DR. DODGE. Was there any air seen over the surface of the brain?

DR. BRODEUR. No, not beyond the basal cisterns.

DR. DODGE. The air did apparently go through the aqueduct and escaped from the fourth ventricle.

DR. BRODEUR. Correct. As you can see here, the air outlines lateral ventricles, the interventricular foramina, and the anterior part of the third ventricle. The floor of the third ventricle is not elevated. We did not get good filling of the fourth ventricle, but we have a good outline of the basal cisterns. Indeed, there seemed to be communication all the way through.

DR. DODGE. On the other hand, although the ventricles are slightly on the large side, as you

\*Radiologist.

point out, they clearly aren't displaced laterally, and there are no other deformities of the ventricular system. Would you show the chest films?

DR. BRODEUR. We do not have the earlier radiographs. This radiograph was made in late June, 1968, at which time the heart was increasing in transverse diameter. There is a generalized ovalness with a moderately narrowed base and not a great deal of vascular increase.

DR. DODGE. Is that mediastinal shadow on the right a venous shadow or thymus?

DR. BRODEUR. It is most likely the superior vena cava and it was the area, I suspect, in which the shunt was done, so it would be more prominent because of the increased blood flow through that point.

DR. DODGE. The terminal phase of this infant's illness was characterized by gradually increasing coma, development of bilateral Babinski signs, and generalized hypertonia. This combination of neurologic signs suggests generalized dysfunction of the cerebrum. Bilateral involvement of the cortex is indicated by focal seizures, first on one and then on the other side. There were no signs to implicate the brainstem or other posterior fossa structures, and there was no evidence on the ventriculogram to make one think seriously about a mass below the tentorium which might have led to increased pressure by way of hydrocephalus. It seems reasonable to assume that the neurologic syndrome was a complication of the congenital heart lesion. There are 3 major disorders which complicate congenital, cyanotic heart disease. The first, and most common, is generalized hypoxemia. Babies with this problem may, as you know, have episodes of fainting or seizures which frequently are isolated events. In a review by Tyler and Clark,<sup>1</sup> there are 225 examples of seizures or "funny attacks" occurring in the 1,875 patients from Dr. Helen Taussig's clinic. If hypoxia is severe and recurrent, destruction of neurons may occur and mental defect result. The second disorder is infection, most often abscess; and the third is occlusive vascular disease. The pattern of neurologic deterioration with strikingly increased intracranial pressure is entirely out of keeping with simple hypoxemia. We have seen increased intracranial pressure following arteriovenous shunting. This is associated with suffusion of the vessels over the face and scalp; if the pressure persists long enough, the ventricles may enlarge. This is uncommon. There is very little in today's protocol to indicate that we are dealing with this problem. The cranial bruits suggest the

possibility of increased flow through the venous system, although we may find that the shunt was not completely open during the later stages of the illness. It may also be that increased cardiac output and increased flow through this shunt occurred as the patient developed increasing anemia. This would have accentuated the bruits.

Brain abscess must be considered whenever a patient with a right-to-left shunt develops neurologic signs. This usually occurs in the absence of bacterial endocarditis. Obviously, one cannot exclude bacterial endocarditis, particularly since we know that as many as 10 per cent of babies who have had these shunting procedures develop an endocarditis, but definite signs of this are lacking in the present case. Clark and Clark<sup>2</sup> found 27 brain abscesses in their review, but based on their findings and on other series of patients, one could almost rule out abscess on the basis of the patient's age. Brain abscess rarely complicates congenital heart disease in children below 2 years of age. Even if today's patient were older than 2 years, there are features which would be against brain abscess, in my opinion. First of all, there is no evidence of a slowly evolving focal lesion of the hemisphere with localized slowing of the electroencephalogram. Rather, we have evidence of a generalized abnormality. This could represent multiple abscesses, but the appearance of the ventricular system would be against this, particularly if there were masses of sufficient size to produce prominent evidence of increased intracranial pressure. I say this with some fear and trepidation because 4 or 5 years ago in a similar exercise at Children's Hospital in Boston, I discussed a patient with a congenital heart lesion and a right-to-left shunt in whom the ventriculogram and arteriogram were normal. At necropsy a deep cerebral abscess which had ruptured into the ventricle and evacuated most of its contents was found. Moreover, at the time when the x-ray study was done, edema, which is usually very prominent around an abscess, had subsided. Both of these tended to diminish the mass of the lesion.

All of the data in this case are much more in keeping with what I think the proper diagnosis must be—thrombosis of intracranial vessels with hemorrhagic cerebral infarction. There were 72 cerebral vascular accidents in the Hopkins' series, 74 per cent of these occurring in the first 20 months of life. The commonest congenital heart malformations were tetralogy of Fallot and transposition, which together accounted for 53 of the 72 cases. In that series there was only one case of truncus arteriosus complicated by intracranial

vascular thrombosis. The majority of patients were younger, and there was severe oxygen desaturation with polycythemia, but it is important to note that this combination of findings may be missing. Thus, anemia with associated intracranial thrombosis may be encountered. Now where did the blood go and why the drop in the patient's hemoglobin and hematocrit? I have postulated that there is going to be some intracranial thrombosis with hemorrhagic infarction of brain to explain the yellow spinal fluid with white and red cells, but hardly enough blood was found to account for the fairly dramatic drop in the hematocrit and hemoglobin. We know that significant amounts of blood can be sequestered in a subdural collection, but inasmuch as I don't think this patient had evidence of a large subdural collection, clinically or from the x-ray studies, I would doubt that this is the explanation. Babies who are this sick can develop stress ulcers and gastrointestinal bleeding, and one of the first places one looks for occult blood is in the stool. Did the stools get black? Was there a positive guaiac test?

RESIDENT PHYSICIAN. I'm not sure that the guaiac was ever done, but there was no clinical evidence of gastrointestinal bleeding.

DR. DODGE. This patient was desperately ill and malnourished, and some degree of iron deficiency anemia may have been present, but some other mechanism accounted for the rapid drop in hematocrit.

If we assume that there was bilateral cerebral infarction responsible for the terminal illness, was this caused by arterial or venous occlusion? Either or both may occur in the course of congenital cyanotic heart disease. The alternating seizures, first on one and then on the other side, are often telltale evidence of involvement of the sagittal sinus and of its draining cortical veins. I would think that in this present case, this was very likely the site of the thrombosis. The occurrence of infarction superficially would account for the subarachnoid blood, for the involvement of the cerebral cortex, and for the normal ventricular fluid early in the clinical course. I would think that there was probably extensive infarction, probably extending posteriorly into the parietal regions. One or both lateral sinuses may have been occluded.

DR. WITZLEBEN.\* Before we show the pathologic data, I'd like to ask for any comments. Dr.

Smith, would you like to make any comments about the patient or his course?

DR. SMITH.\* Thrombotic disease certainly was what we felt that he had, with the possibility of superimposed infection because of the increased number of white cells. I'd like to ask Dr. Dodge whether he thinks that there would be arterial thrombosis with increased intracranial pressure? Has he seen this occur, or is venous thrombosis more likely to be present?

DR. DODGE. I would think that if there are arterial thromboses, they are not extensive and that there had to be a major venous obstruction, at least, to produce the clinical picture.

DR. SMITH. Does one ever start off with vascular occlusion in the middle cerebral artery with extension into the veins? Is this possible, say, if an infant became sick and dehydrated?

DR. DODGE. That's an interesting concept. I have never considered that mechanism. As regards the white cells in the spinal fluid, my interpretation would be that they resulted from the venous infarction and the hemorrhage, rather than from infection, but I would have treated the patient for infection as you did and not been comfortable about my diagnostic acumen.

DR. WITZLEBEN. May I just interject a question here flowing from the pathologist's ignorance of therapy? When you consider this diagnosis, is there any role for anticoagulant therapy?

DR. DODGE. I think there are no data which support the treatment of these lesions with anticoagulants. There may even be a reason for not using them, since when you have blood in the spinal fluid and evidence of hemorrhagic infarction, people are usually concerned that anticoagulants will aggravate the problem; this has tended to make us shy away from this form of therapy. However, if one has evidence of bland intracranial sinus occlusion in the absence of evidence of infarction, as in the pseudotumor syndrome, then treatment with thrombolytic agents may be indicated. We have had occasion within the last few months to treat one such patient, we think quite successfully, with Urokinase.

STUDENT. Could the cranial bruit indicate an arteriovenous malformation?

DR. DODGE. I think that when you hear a very loud intracranial bruit, this always comes to mind. My impression is that if there is an increased incidence of arteriovenous malformations in congenital heart disease, it is not very great.

\*Associate Professor of Pathology and Pediatrics, St. Louis University Medical School.

\*Associate Professor of Neurosurgery, St. Louis University.

Maybe Dr. Fagan has some contrary evidence.

DR. FAGAN.\* The only figure I know is that 5 per cent of the people who have ruptured arteriovenous fistulae have coarctation of the aorta, but 5 per cent of the people with coarctation do not have such fistulae.

DR. WITZLEBEN. I assume that we are eliminating the relationship between coarctation and Berry aneurysms.

STUDENT. Can one have thromboses with as mild a polycythemia as a hematocrit of 51 per cent?

DR. DODGE. In the past, people have associated the intracranial clotting with severe degrees of polycythemia, oxygen desaturation, and sludging. But, it is perfectly clear that clotting occurs in the absence of significant polycythemia, and in fact even in the presence of a relative anemia.

*Dr. Dodge's diagnosis*

Truncus arteriosus

Cerebral infarction secondary to venous thrombosis

**PATHOLOGIC FINDINGS**

DR. WITZLEBEN. The principal pathologic changes were in the thoracic and cranial cavities. The autopsy confirmed the presence of truncus arteriosus. The superior vena cava-right pulmonary artery anastomosis was intact and patent, and the intima in the area of the anasto-

mosis was smooth, without evidence of abnormality. However, there was a thrombus occluding the left pulmonary artery near its origin. There were no mural or valvular cardiac abnormalities. Examination of the cranial contents revealed that there was, as Dr. Dodge has suggested, considerable subarachnoid hemorrhage, more prominent over the right cerebral hemisphere than over the left, and more prominent anteriorly than elsewhere. The key to the intracranial pathology was found in the presence of prominent, very firm, venous channels over the cerebral surfaces. These vessels varied in color from dark reddish-brown to pale tan, and on palpation, generally had the consistency of twine. These gross changes were essentially diagnostic of diffuse cerebral venous thrombosis. No vascular malformations were present. In addition to the evident thrombi in these veins, there was also a grossly recognizable thrombus involving the superior sagittal sinus, as Dr. Dodge has already suggested. On the cut surface of the brain, there was extensive intracerebral hemorrhage involving both gray and white matter of the anterior aspect of the right frontal lobe; similar smaller areas were found in the same regions in the left frontal lobe (Fig. 1). Scattered areas of hemorrhagic infarction, principally involving the cortex, were found involving the anterior two thirds of both cerebral hemispheres. These were considerably more prominent on the right than on the left. The brainstem and cerebellum were grossly unremarkable.

\*Cardiologist, Cardinal Glennon Hospital.

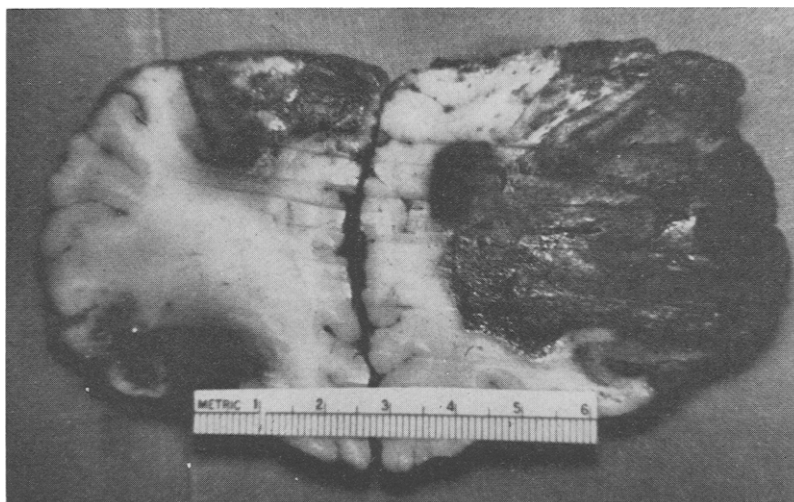
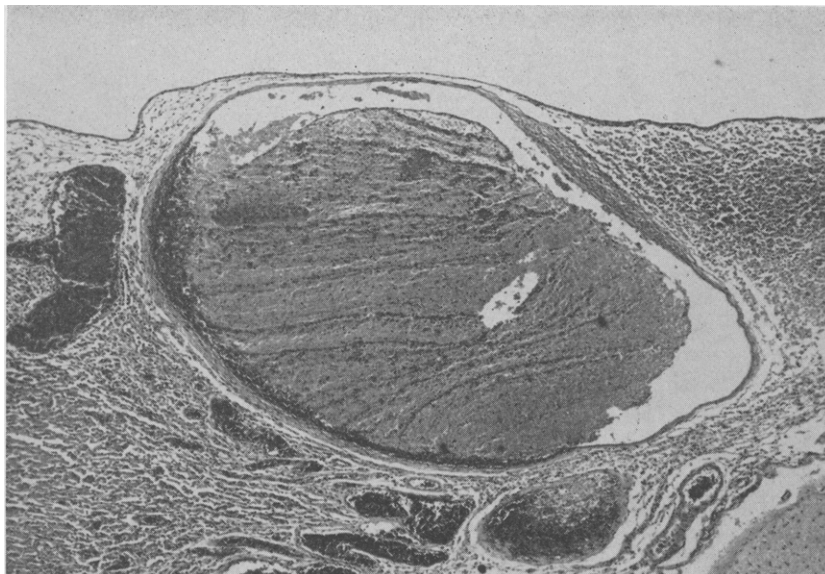
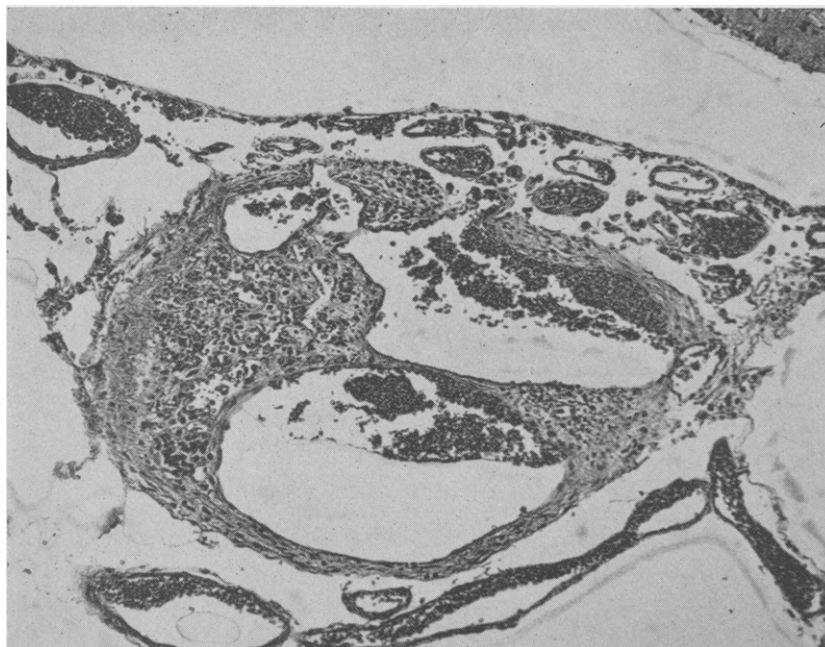


Fig. 1. Coronal section of cerebral hemispheres just anterior to the anterior tip of the lateral ventricle. Extensive bilateral hemorrhagic infarction of the hemispheres is evident.



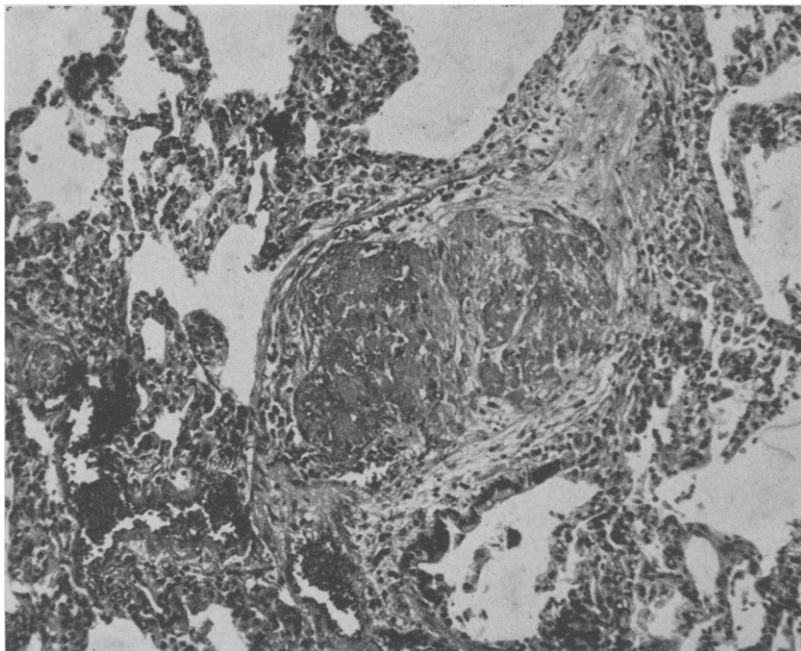
**Fig. 2.** Microsection of vein in leptomeninges showing large thrombus. Masses of red cells and leucocytes are present in the surrounding subarachnoid space. (Hematoxylin and eosin.  $\times 15$ .)



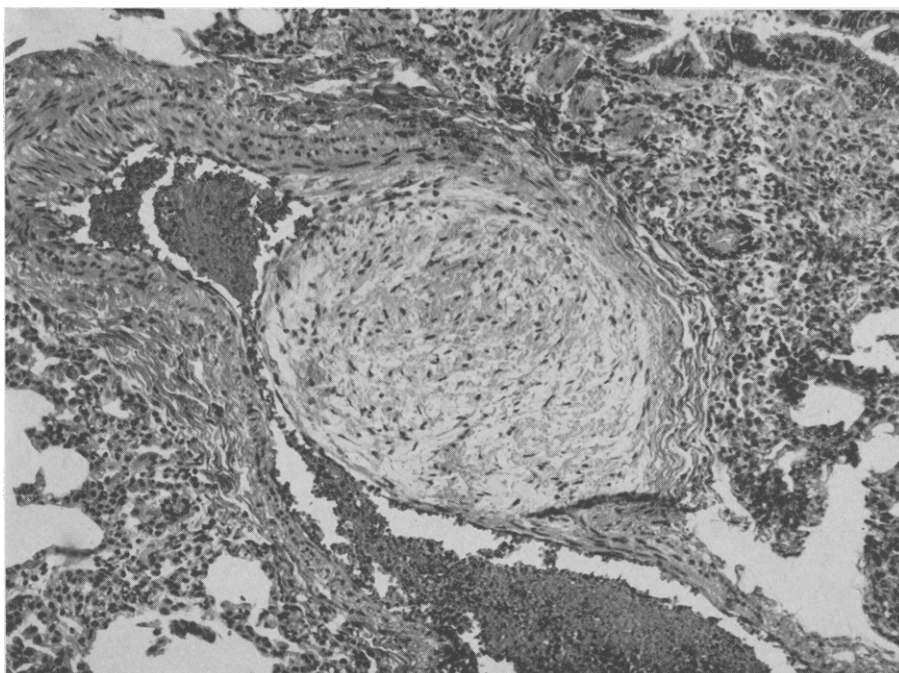
**Fig. 3.** Microsection of vein in leptomeninges showing evident recanalization, indicating previous occlusion. (Hematoxylin and eosin.  $\times 25$ .)

Microscopic examination confirmed the presence of extensive, relatively recent thrombosis involving the cerebral veins throughout and also the superior sagittal sinus (Fig. 2). The thrombi were accompanied by extensive hemorrhagic in-

farcation. In addition to these relatively acute vascular occlusions, evidence of much older previous venous occlusion with recanalization was found in scattered cerebral veins (Fig. 3). It appears probable then, that this terminal episode of ve-



**Fig. 4.** Microsection of right lung, showing small vessel completely occluded by thrombus composed predominantly of fibrin. (Hematoxylin and eosin.  $\times 65$ .)



**Fig. 5.** Microsection of left lung showing eccentric thickening of blood vessel, consistent with thrombus or embolus previously incorporated into vessel wall. (Hematoxylin and eosin.  $\times 65$ .)



nous thrombosis was not the first to occur in this patient, although it was obviously the most serious.

There were some additional interesting cardiovascular changes present. Sections from the right lung revealed the presence of numerous, relatively fresh emboli in the small arterial channels (Fig. 4). It seems quite probable that most of these originated in the cerebral vessels and their passage into the right lung specifically was facilitated by the anastomosis. A high percentage of pulmonary emboli in children arise in the cerebral veins.<sup>3</sup> It is of interest that the left lung was also the site of extensive vascular occlusion, but the vascular occlusions on this side were considerably older than those on the right, with many showing evident organization and/or incorporation into the wall of the involved vessels (Fig. 5). The thrombus grossly observed in the left pulmonary artery was similarly organized and of older vintage than the majority of the cerebral thrombi. This is consistent with the possibility that the peripheral pulmonary vascular occlusions seen in the left lung arose as emboli from the pulmonary artery thrombosis on that side. The basis for the pulmonary artery thrombosis was not evident.

DR. FAGAN. Are these old emboli?

DR. WITZLEBEN. I would think so. Probably older than the duration of the terminal course. They might also have come from the earlier cerebral venous occlusions.

DR. DODGE. How do you know these are emboli and not occlusions arising in situ?

DR. WITZLEBEN. This possibility cannot be

eliminated. To sum up then, the principal problem was, as Dr. Dodge correctly indicated, diffuse cerebral venous thrombosis. This resulted in extensive hemorrhagic infarction of the cerebral hemispheres with greater involvement on the right than on the left. The precise basis for the development of these and similar thrombi in children with congenital heart disease<sup>4</sup> has so far not been clearly elucidated.

#### *Final anatomic diagnoses*

Truncus arteriosus with surgical anastomosis of superior vena cava-right pulmonary artery 1 year earlier

Organized thrombus, left pulmonary artery, with organizing pulmonary thromboemboli, left lung

Cerebral venous thrombosis, old (minimal), and recent (extensive)

Extensive hemorrhagic cerebral infarction

Multiple emboli, right lung

#### REFERENCES

1. Tyler, H. R., and Clark, G. B.: Incidence of neurological complications in congenital heart disease, *Arch. Neurol. Psychiat.* **77**: 17, 1957.
2. Clark, G. B., and Clark, E. S.: Brain abscess as a complication of congenital cardiac malformation, *Trans. Amer. Neurol. Ass.* **77**: 73, 1952.
3. Emery, J. L.: Pulmonary embolism in children, *Arch. Dis. Child.* **37**: 591, 1962.
4. Berthrong, M., and Sabiston, D. C.: Cerebral lesions in congenital heart disease, *Bull. Hopkins Hosp.* **89**: 384, 1951.

**Erratum.** In the article, "Infantile nystagmus: A prospective study of spasmus nutans, congenital nystagmus, and unclassified nystagmus of infancy," by P. Jayalakshmi, T. F. McNair Scott, S. H. Tucker, and D. B. Schaffer, which appeared on pp. 177-187 of the August, 1970, issue of the *JOURNAL*, line 33 on p. 181 should have read ( $P = < 0.01$ ).