

Haematol 24:255-259, 1973

15. Winkelman NW, Gotten N, Scheibert D: Localized adhesive spinal arachnoiditis: A study of 25 cases with reference to etiology. *Trans Am Neurol Assoc* 78:15-18, 1953
16. Lombardi G, Passerini A: *Spinal Cord Diseases: A Radiologic and Myelographic Analysis*. Baltimore, The Williams & Wilkins Company, 1964, p 160

17. Douglas-Wilson H, Miller S, Watson GW: Spontaneous subarachnoid haemorrhage of intraspinal origin. *Br Med J* 1:554-555, 1933
18. Henson RA, Croft PB: Spontaneous spinal subarachnoid hemorrhage. *Q J Med* 25:53-66, 1956
19. Plotkin R, Ronthal M, Froman C: Spontaneous spinal subarachnoid haemorrhage. *J Neurosurg* 25:443-446, 1966

The anatomic basis of visual agnosia

Article abstract—In a patient with associative visual agnosia without alexia, there was bilateral infarction in the distribution of the posterior cerebral arteries, with corticosubcortical lesions in both occipitotemporal regions, sparing the corpus callosum. Bilateral loss of visual-limbic connections may underlie associative visual agnosia, and bilateral lesions of the inferior longitudinal fasciculi may be the necessary and sufficient lesions for this syndrome. Alexia was absent in this case, perhaps because the corpus callosum was intact.

NEUROLOGY 29: 876-879, June 1979

Martin L. Albert, M.D., Dov Soffer, M.D., Ruth Silverberg, M.D., and Avinoam Reches, M.D.

We previously described a man with associative visual agnosia without alexia.¹ He was unable to appreciate the nature of objects and meaningful nonverbal symbols presented visually, although he could see, draw, describe, and match these stimuli. His auditory recognition and tactile recognition of verbal or nonverbal stimuli were normal. He had no difficulty understanding visually presented words. He died of a heart attack 6 months after we first examined him. We now describe the interim events and neuropathologic findings.

Case report. Detailed descriptions of the original observations in this case have already been published¹; a resumé of the key features follows:

At age 55 years, this right-handed university professor had a mild transient left hemiparesis and occasional subsequent attacks of "confusion," each lasting a few hours. Repeated evaluations revealed no persistent neurologic or neuropsychologic abnormalities. At age 59, he suffered a brief loss of consciousness, followed by visual and memory defects. Two days later we found a mild left lower facial paresis and mild left hemiparesis. He was awake, alert, attentive, and socially appropriate. There was no aphasia. His immediate recall was good, his recent memory was severely impaired, and his remote memory was mildly impaired. He could carry out complex mental calculations and had no difficulty manipulating abstract concepts.

One week after onset, visual acuity was 6/7.5 (Jaeger), and Goldmann perimetry revealed an upper quadrant defect in the right visual field. Electroencephalogram (EEG) demonstrated persistent bilateral occipital slowing, with occasional sharp activity. A brain scan showed increased uptake of radioactive material in both occipital regions, posteriorly and inferiorly.

He could see, draw, describe, and match visual stimuli, yet he could not identify what he was seeing. He

could not name seen objects or describe how to use them. He had no visual neglect or defect of complex visuospatial perception. He could read letters, words, and sentences with no difficulty. He had no aphasia and no general intellectual impairment. The agnosic defect was focal and specific: he could not appreciate the meaning of visually presented, nonverbal, meaningful stimuli (objects or symbols). When nonverbal, meaningful stimuli were presented to the auditory or tactile modalities, he immediately recognized them, named them, and described their use.

Months after onset, we examined him in his home. On formal testing, there was no improvement in the visual agnosia or memory defect. He was able to get around his house, but could not walk alone, without getting lost, in a neighborhood he had lived in for 20 years. Although he could identify many objects (or so it seemed because he used them correctly), he occasionally made mistakes. For example, he mistook a toothbrush for a comb, and shaving cream for toothpaste.

He began to receive students again in his office at home. Discussion ranged over many issues, and those who had not known of his recent stroke were unaware of any problem. He attempted to lecture again, reading directly from notes that he had used the previous year. Occasionally, when he lost his place, he had difficulty remembering where he had left off. At times he reread statements he had already delivered.

During the next few months his topographic memory for his neighborhood improved, but his visual agnosia and impaired recent memory remained unchanged. He died of a myocardial infarction 6 months after the onset of his neurologic illness.

Neuropathologic findings. The brain weighed 1500 gm. The arteries at the circle of Willis showed moderate to severe arteriosclerosis, and the left posterior communicating artery was hypoplastic. On the basal surface, an old infarct involved the entire length of the right parahippocampal and

lingual gyrus, ending 1 cm proximal to the occipital pole. A similar, mirror-image lesion was found in the left parahippocampal gyrus, extending 2 cm posteriorly. A 1-cm-long infarct was found in the left fusiform (temporooccipital) gyrus, terminating 1 cm proximal to the occipital pole.

Coronal sections (figures) disclosed an infarct involving the right insular cortex, a small area of the inferior frontal gyrus, and the claustrum. More caudally, the white matter of the temporal lobe was also affected. The right parahippocampal infarct was primarily cortical, but it had also destroyed the subjacent white matter, including the right inferior longitudinal fasciculus and the white matter underneath the inferior lip of the calcarine fissure.

In the left hemisphere, four old infarcts were observed on gross examination. A left parahippocampal infarct, beginning at the hippocampal formation and running 3 cm posteriorly, was primarily cortical, but had also destroyed the adjacent white matter (inferior longitudinal fasciculus). A $1 \times 0.3 \times 0.4$ cm cortical infarct, more caudally placed, affected the collateral sulcus and left lingual gyrus. A small infarct involved the cortex and subcortical white matter of the left fusiform gyrus, 1 cm proximal to the occipital pole. A cystic infarct measured $1 \times 0.3 \times 0.2$ cm in the left pulvinar.

In addition, there was marked atrophy of the right optic nerve (related to a traumatic injury of the eye with subsequent enucleation). The corpus callosum was unremarkable. No abnormalities were found in the cerebellum or brainstem. Microscopically, several additional minute infarctions were disclosed.

By histologic criteria, the parahippocampal and occipital lesions were compatible with a duration of 6 months. The right insular infarction could be dated months or years earlier.

Discussion. The neuropathologic findings permit clinicoanatomic speculations about two issues: the anatomic basis of associative visual agnosia, and the anatomic explanation for the *absence* of alexia in this case.

Anatomy of associative visual agnosia. It has been suggested that associative visual agnosia may be a disconnection syndrome.² The disconnection theory would apply as follows: Infarction of the left medial occipital region would remove the left hemispheric visual cortex from participation in visual activities. Infarction of the splenium of the corpus callosum would prevent visual stimuli entering an intact right hemispheric visual cortex from crossing over to the left hemispheric language areas. Thus, objects that could be seen could not be named or semantically identified.

This form of disconnection theory, however, would not apply in our case for two reasons. First,

the patient did not have a complete right hemianopia. Visual stimuli could reach his left visual cortex. Second, there was no lesion of the corpus callosum. Stimuli reaching right hemispheric visual areas could be transmitted across the corpus callosum to the left hemisphere.

If the disconnection theory in its usual form does not apply, what lesions caused the agnosia? We suggest that access to memory stores in the temporal lobes and limbic system is necessary for full appreciation of the nature of an object. It has previously been proposed that visual-limbic connections must be intact to understand fully the nature of perceived visual stimuli.^{3,4} The inferior longitudinal fasciculus is the major direct pathway for transfer of visual information from cortical areas 18 and 19 to the temporal lobe and limbic system. In this patient, the inferior longitudinal fasciculi were destroyed bilaterally, which could prevent transfer of visual information from the visual association cortex to the limbic system. Visual stimuli would then be processed for perception in the visual association cortex (as evidenced in our patient by the ability to see, draw, describe, and match stimuli), but would not be processed for meaning, since visual stimuli would not excite visual memory stores in the limbic system. Bilateral interference with visual-limbic connections would produce a visual "percept stripped of its meaning," Teuber's definition of agnosia "in its purest form."⁵

In speaking of visual agnosia for faces (prosopagnosia), Meadows³ distinguished visual perception of faces and visual memory for faces. He suggested that visual memory impairment might underlie prosopagnosia, and that a lesion affecting the right inferior longitudinal fasciculus might be essential for this unique form of visual agnosia. Benson, Segarra, and Albert⁴ proposed that bilateral loss of visual-limbic connections (visual association cortex-inferior longitudinal fasciculus-hippocampus) might be necessary for visual agnosia. They attributed visual agnosia in their patient to a specific combination of lesions involving the primary visual pathways of the dominant hemisphere, the splenium of the corpus callosum, and the inferior longitudinal fasciculus of the non-dominant hemisphere. The present case supports and refines their hypothesis. Although the corpus callosum was intact in our case, there was bilateral loss of visual-limbic connections. Auditory and somesthetic connections (intra- and interhemispheric) remained intact, limiting the syndrome to vision.

Anatomy of alexia. Although our case does not support the disconnection theory in its usual form as an explanation for visual agnosia, it does support the disconnection theory as an explanation for pure alexia. According to the disconnection theory as an explanation for alexia, the lesion affects the splenium of the corpus callosum and the medial

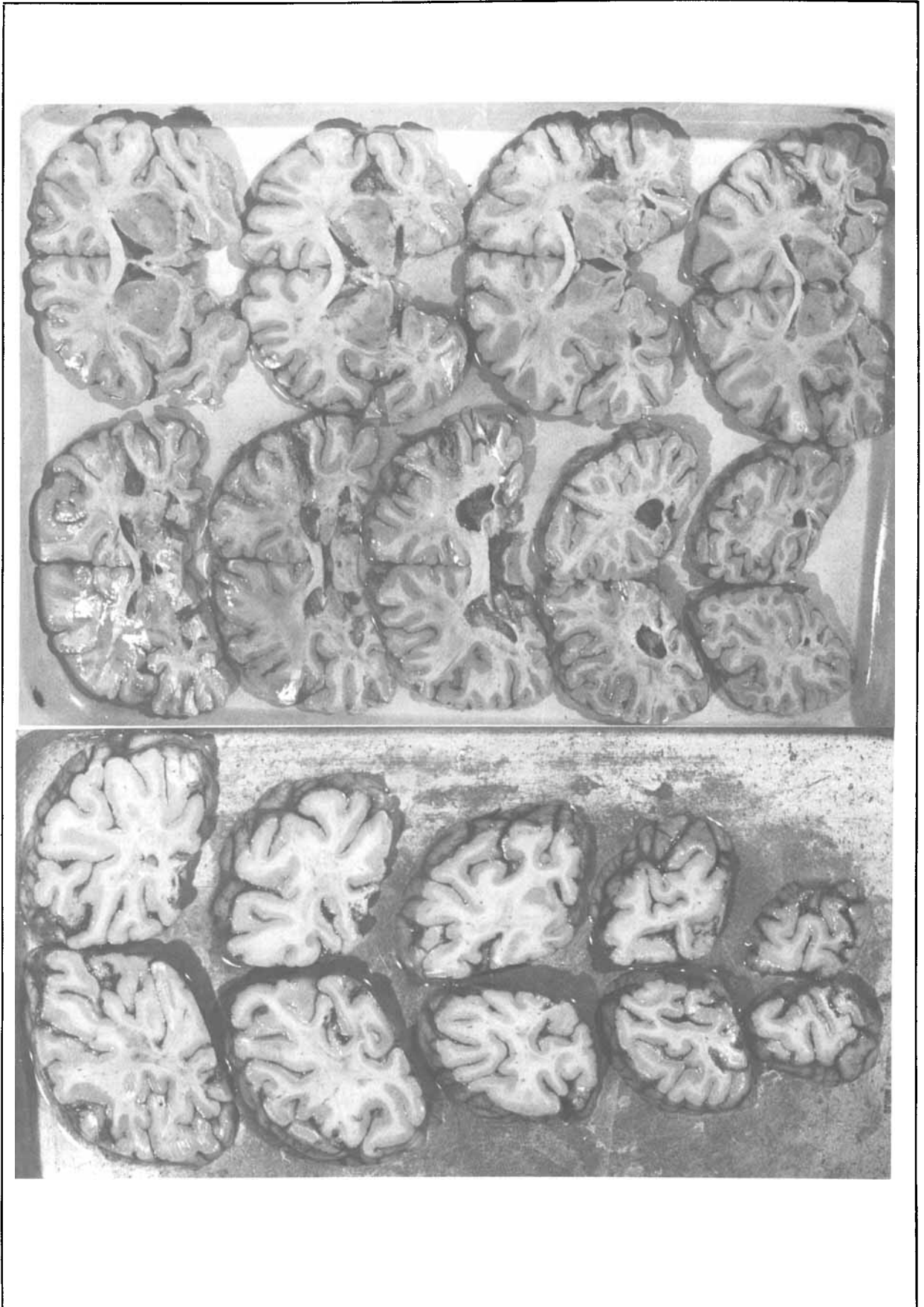


Figure. Coronal sections through brain of patient with associative visual agnosia without alexia.

occipital area of the dominant hemisphere (the calcarine region, and lingual or fusiform gyri). Pure alexia results when verbal stimuli cannot enter the left hemispheric visual areas because of the left occipital lesion, and cannot be transmitted to intact left hemispheric language areas from intact right hemispheric visual areas because of the callosal lesion.

With the exception of three cases (this one and two others),^{6,7} all reported patients with associative visual agnosia also had alexia. The anatomic explanation for the agnosia usually implicates the splenium of the corpus callosum. The explanation for the alexia is similar, also implicating the splenium of the corpus callosum. In our case, the left occipital region was damaged, but the corpus callosum was spared. Agnosia was present; alexia was absent. We suggest that alexia was absent because the splenium of the corpus callosum was intact. Pure alexia may be caused by damage to the left medial occipital region, coupled with a lesion of the corpus callosum. The lesion of the corpus callosum is not necessary, however, for visual agnosia.

There is an alternative explanation for the absence of alexia in our patient. The right hemianopia was incomplete, and visual stimuli could reach the left hemisphere. These visual stimuli may have had access to language areas in the left hemisphere.

Acknowledgments

We thank Drs. D. Frank Benson, Edith Kaplan, Loraine Obler, and Norman Geschwind for advice on the manuscript, and Ms. Judith Silverberg for many hours of technical assistance.

From the Aranne Laboratory for Human Psychophysiology and the Departments of Neurology and Pathology, Hadassah University Hospital-Hebrew University Medical School, Jerusalem, Israel, and the Department of Neurology, Boston University Medical School and Boston Veterans Administration Hospital, Boston, Massachusetts.

This paper was presented in part at the thirtieth annual meeting of the American Academy of Neurology, Los Angeles, California, April 29, 1978.

Accepted for publication September 6, 1978.

Dr. Albert's address is Department of Neurology, Boston Veterans Administration Hospital, 150 South Huntington Avenue, Boston, MA 02130.

References

1. Albert ML, Reches A, Silverberg R: Associative visual agnosia without alexia. *Neurology (Minneapolis)* 25:322-326, 1975
2. Geschwind N: Disconnexion syndromes in animals and man. *Brain* 88:237-294, 1965
3. Meadows J: The anatomical basis of prosopagnosia. *J Neurol Neurosurg Psychiatry* 37:489-501, 1974
4. Benson DF, Segarra J, Albert M: Visual agnosia-prosopagnosia. *Arch Neurol* 30:307-310, 1974
5. Milner B, Teuber H-L: Alteration of perception and memory in man. In Weiskrantz L (Editor): *Analysis of Behavioral Change*. New York, Harper & Row, Publishers, Inc, 1968, pp 268-375
6. Davidenkoff S: Impairments of higher nervous activity: Lecture 8: Visual agnosias. In *Clinical Lectures on Nervous Diseases*. Leningrad, State Publishing House of Medical Literature, 1956
7. Mack J, Boller F: Associative visual agnosia and its related deficits. *Neuropsychologia* 15:345-351, 1977

Neurology®

The anatomic basis of visual agnosia
Martin L. Albert, Dov Soffer, Ruth Silverberg, et al.
Neurology 1979;29;876
DOI 10.1212/WNL.29.6.876

This information is current as of June 1, 1979

Updated Information & Services	including high resolution figures, can be found at: http://www.neurology.org/content/29/6/876.full.html
Citations	This article has been cited by 1 HighWire-hosted articles: http://www.neurology.org/content/29/6/876.full.html#otherarticles
Permissions & Licensing	Information about reproducing this article in parts (figures, tables) or in its entirety can be found online at: http://www.neurology.org/misc/about.xhtml#permissions
Reprints	Information about ordering reprints can be found online: http://www.neurology.org/misc/addir.xhtml#reprintsus

Neurology® is the official journal of the American Academy of Neurology. Published continuously since 1951, it is now a weekly with 48 issues per year. Copyright © 1979 by the American Academy of Neurology. All rights reserved. Print ISSN: 0028-3878. Online ISSN: 1526-632X.

