



Localized Mesothelioma of the Pericardium

C. MILTON LINTHICUM, MD,† *Baltimore, Md*

MESOTHELIOMAS have been reported more frequently in the literature since Stout and Murray¹ described the successful growing of these tumors in tissue culture and properly identified their origin. The sites of origin in most of the reports are from the pleura or peritoneum. Much rarer are mesotheliomas arising from the pericardium.²⁻⁴ This is a case report of such a tumor found incidentally at autopsy.

Case Report

A 72 year old colored woman was admitted to Montebello State Hospital on Feb 21, 1966, for rehabilitation following a cerebrovascular accident 11 days previously. The patient was diabetic and had hypertension. The main physical findings on admission were related to the left hemiplegia. No abnormal cardiac findings were discerned, and an EKG showed only sinus tachycardia with left axis deviation.


The hospital course was uneventful; she was receiving physiotherapy for her disability. On March 9, she complained of discomfort in the right upper abdominal quadrant, and was dyspneic. She died suddenly despite resuscitative measures.

Autopsy. The immediate cause of death was a large coiled embolus occluding both major branches of the pulmonary artery. Other findings included fresh and recent cerebral infarcts in the right thalamus and caudate nucleus, with scarring in the adjacent portion of the internal capsule, and an organizing thrombus in the right vertebral artery. A recent hemorrhagic infarct was found in the lower lobe of the right lung. Diabetes mellitus was manifested by hyalinization of several islets of Langerhans, lipoidosis of the spleen and moderate renal arteriolosclerosis. There was slight fatty metamorphosis of the liver.

The heart weighed 384 Gm. The wall of the left ventricle was slightly hypertrophied and measured 1.6 cm in thickness. The myocardium was reddish tan in color. The valves were delicate and the coronary arteries showed severe arteriosclerosis, but the lumens were only slightly narrowed focally. Five ml of clear yellow fluid were in the pericardial sac.

†From the Department of Pathology, Montebello State Hospital, Baltimore, Md.

FIG 1

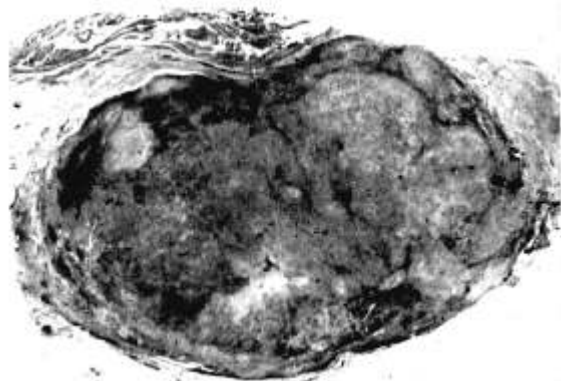


Cross section of pericardial tumor, showing apparent encapsulation. The dark areas in the tumor are hemorrhage.

A tumor, 2.5 cm in its greatest diameter, was present on the posterior wall of the left atrium (Fig 1). It appeared to be well encapsulated and severely compressed the underlying coronary sinus, obliterating the lumen in the central portion. A thrombus, 1 cm long, dilated and filled the distal portion of the sinus. The tumor cut with resistance. The cut surfaces were opaque, white and mottled with small hemorrhagic areas. The portion adjacent to the myocardium was translucent, white and resembled fibrous tissue. The overlying epicardium was grayish red discolored.

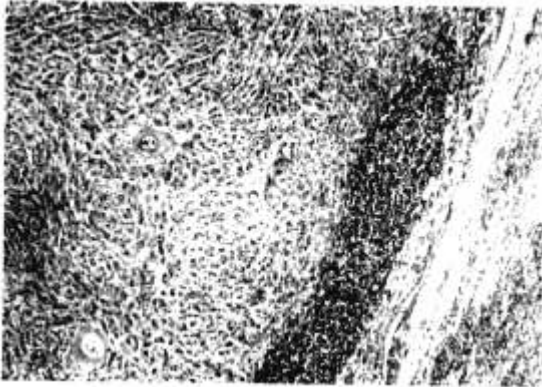
Microscopically, the tumor was not encapsulated but was surrounded by an irregular band of dense fibrous

FIG 2



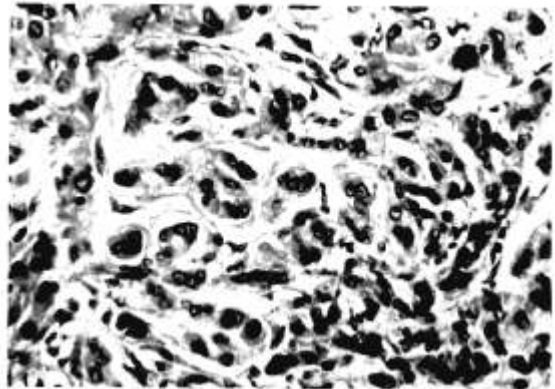
Low magnification shows the variegated appearance due to focal hemorrhages and scarring. (H & E \times 4.5)

FIG 3



Photomicrograph of edge of tumor showing the irregular fibrous border infiltrated with lymphocytes. The epithelial-like pattern of the neoplastic cells is apparent. (H & E x 28)

FIG 4



Higher power shows the syncytial pattern of neoplastic cells. Nuclei are pleomorphic but bland. (H & E x 240)

tissue. It did not invade the underlying myocardium. The architecture was variable due to degenerative changes as evidenced by focal scarring and hemorrhages (Fig 2). Some scars were dense; others myxomatous, and calcium deposits were present in a few. Deposits of brown pigment, which stained positively for iron, were also seen. Large aggregates of lymphocytes and plasma cells infiltrated the tumor here and there (Fig 3). The neoplastic cells were epithelial-like and, for the most part, appeared to be arranged in syncytia separated by collagenous tissue. Occasional single cells were seen, and a few showed a pattern reminiscent of pearl formation. Others were spindle-shaped, but this appeared to be due to compression by the surrounding scar tissue. Occasional cells had phagocytized erythrocytes and some contained brown pigment. The cytoplasm was abundant and pink. The nuclei were ovoid, bland-appearing, and contained stippled chromatin (Fig 4). No mitotic figures were seen. PAS and mucicarmine stains of the tumor were negative. A reticulum stain showed argyrophilic fibers surrounding numerous neoplastic cells, but by no means about all of them, nor was the distribution of fibers even. No other tumor was found in the body.

Comment. The histologic appearance and location of the pericardial tumor warrants the diagnosis of a localized mesothelioma. Cytologically, it appeared benign. The scar-

ring and degeneration present was the probable result of the slight, but repetitive trauma of the pulsating heart. There are those, however, who doubt that such a tumor exists and think that this type of lesion represents a metastasis from an obscure or undiscovered malignancy.⁵ Since no other neoplasm was found at autopsy, this tumor represents further evidence that such is not the case.

The small size of the tumor and the absence of pericardial effusion precluded any interference with the normal function of the heart, and thus there were no symptoms from the tumor.

2201 Argonne Drive
Baltimore, Md 21218

References

1. Stout, A. P., and Murray, M.: *Localized Pleural Mesothelioma: Investigation of its Characteristics and Histogenesis by Method of Tissue Culture*, Arch Path (Chicago) 34:951, 1942.
2. Landing, B. H., and Farber, S.: *Tumors of the Cardiovascular System*. Washington, Armed Forces Institute of Pathology, 1956.
3. Hudson, R. E. B.: *Cardiovascular Pathology*. Baltimore, The Williams and Wilkins Co., 1965.
4. Dawe, C. J., Wood, D. A., and Mitchell, S.: Diffuse Fibrous Mesothelioma of the Pericardium, *Cancer* 6:794, 1953.
5. Willis, R. A.: *Pathology of Tumours*. Third ed., Washington, Butterworth and Co., 1960.