

## Case Reports and Technical Notes

### Basilar Aneurysm Associated with Agenesis of the Left Internal Carotid Artery

#### Case Report

PETER D. MOYES, M.D., F.R.C.S. (CAN)

Department of Surgery (Neurosurgery), University of British Columbia, Vancouver, Canada

A SIGNIFICANT tendency for intracranial aneurysms to occur in the presence of other anomalies of the intracranial circulation has been reported.<sup>4,8</sup> The most common association in my experience has been the finding of an anterior communicating aneurysm with absence or hypoplasia of one proximal anterior cerebral artery. Of 47 anterior communicating aneurysms demonstrated angiographically, 12 had absence or hypoplasia of one proximal anterior cerebral artery. In five cases the left anterior cerebral artery was hypoplastic or absent and in seven cases the right was involved. Five cases were men and seven were women.

Lhermitte, *et al.*,<sup>10</sup> have reported the case of a 63-year-old woman with hypoplasia of the left internal carotid artery, demonstrated angiographically on more than one occasion. However, the patient had had a subarach-

noid hemorrhage, and, at postmortem examination, an aneurysm at the junction between the anterior communicating and right internal carotid arteries was found to have been the source of her hemorrhage. Others<sup>1,9,13</sup> have reported cases of agenesis or hypoplasia of one or the other internal carotid artery, in several of which anterior communicating aneurysms were found; in fact, subarachnoid hemorrhage had been the reason for cerebral angiography.

Wissinger, *et al.*,<sup>14</sup> reported the absence of a vertebral artery in association with a basilar aneurysm. Jamieson<sup>6,7</sup> reported 28 patients with aneurysms of the vertebrobasilar system, and Drake<sup>2,3</sup> reported 14 cases of basilar aneurysm. Neither in theirs or other reports<sup>11-14</sup> of basilar aneurysms have I found any reference to the association of a basilar aneurysm with agenesis of a carotid artery.

Received for publication August 27, 1968.

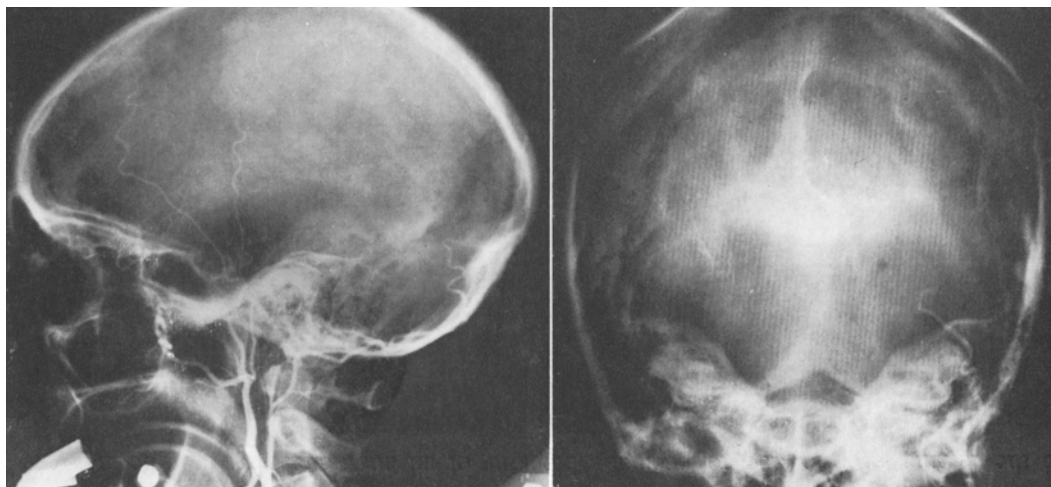


FIG. 1. Left carotid angiogram, lateral (*left*) and anteroposterior (*right*) views, showing filling of the external carotid but not the internal carotid.

### Case Report

This 37-year-old housewife had been in good general health until March 25, 1965, when she suddenly collapsed and became unconscious. She seemed to have a left hemiplegia, and when she was conscious the next day she complained of severe headache. She continued to improve and was transferred to Vancouver General Hospital on March 28, 1965. Her past and family histories were non-contributory.

*Examination.* On admission she was alert and oriented, complained of headache, had a stiff neck and a mild left hemiparesis. Her blood pressure was 100/70. On March 29, angiograms showed good filling of the left external carotid artery but no filling of the internal carotid (Fig. 1). Right carotid injection showed opacification of the right internal carotid and middle cerebral arteries and both anterior cerebral arteries, with long lateral extensions of branches of the left anterior cerebral artery reaching part of the area normally supplied by the left middle cerebral artery (Fig. 2). In these studies no aneurysm was seen. On March 31, the left common carotid angiogram was repeated with results similar to those of the previous study. A left cut-down retrograde brachial arteriogram was then carried out, which showed a midline aneurysm,  $2 \times 1.5$  cm, that appeared to arise from the basilar artery

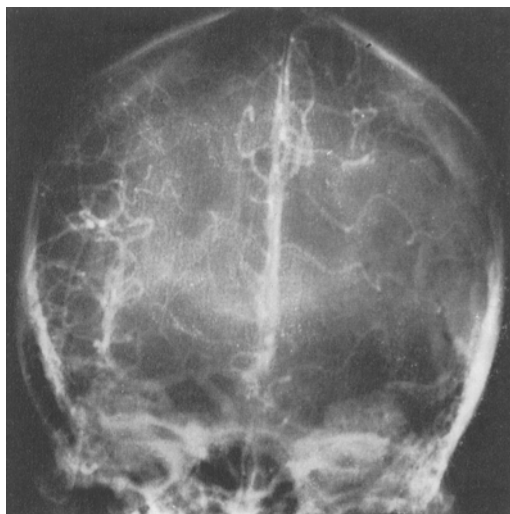


FIG. 2. Right carotid angiogram, anteroposterior view, showing lateral extension of branches of the left anterior cerebral artery.

by a neck or artery 5 mm long. Branches of the left posterior cerebral artery were seen to extend laterally to the remaining area normally supplied by the left middle cerebral artery (Fig. 3).

*Operation.* On April 2, 1965, the patient was anesthetized and cooled to a temperature of  $28.5^{\circ}\text{C}$ ; the carotid and vertebral arteries were exposed in the neck. Because it was felt that patency of the right carotid artery was of such importance, an approach

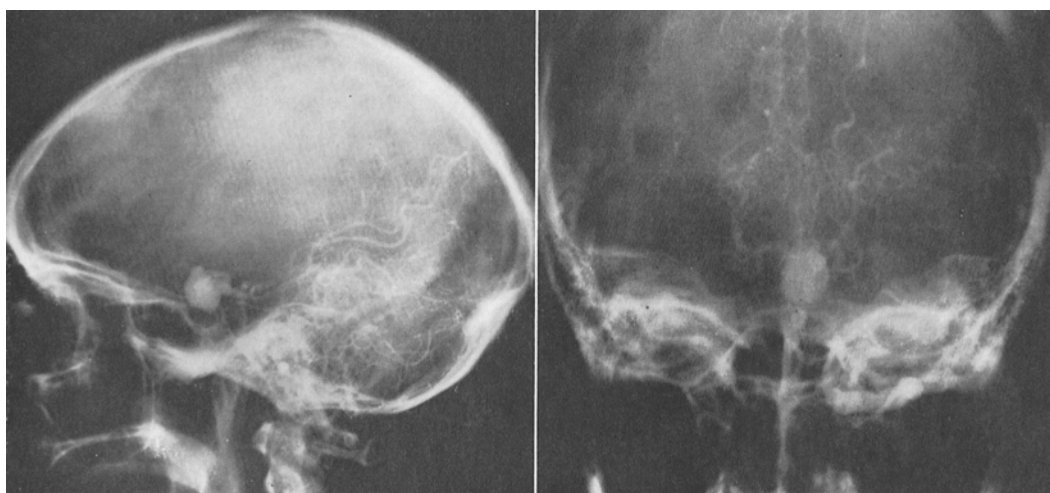


FIG. 3. Left vertebral angiogram (retrograde brachial), lateral (*left*) and anteroposterior (*right*) views, showing a large aneurysm arising from the basilar artery. Faint opacification of one anterior cerebral artery can be seen and some lateral extension of branches of the left posterior cerebral artery.

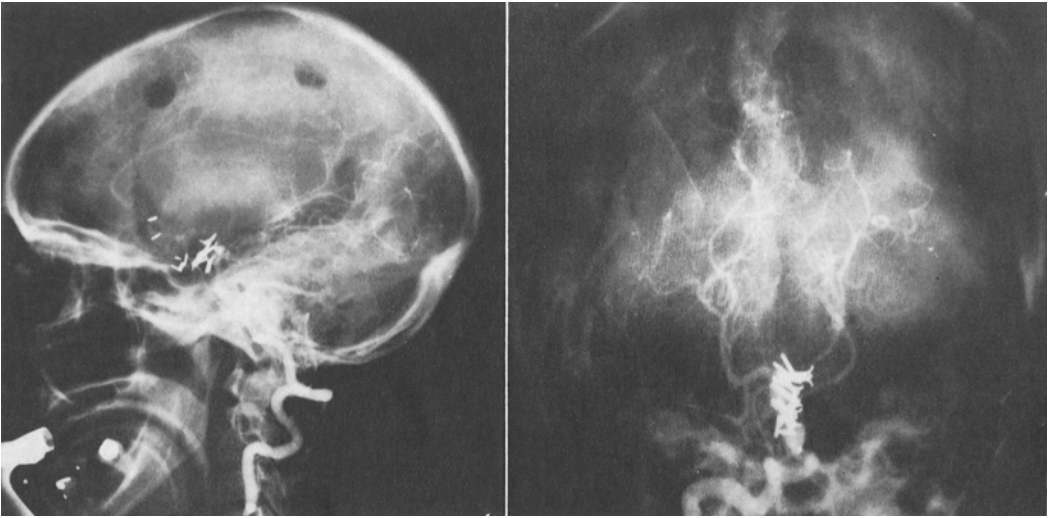


FIG. 4. Postoperative right vertebral (percutaneous) angiogram, lateral (*left*) and anteroposterior (*right*) views, showing obliteration of the aneurysm and patency of the major vessels and, again, faint opacification of one anterior cerebral artery.

under the left temporal lobe was carried out. Despite occlusion of all four vessels in the neck for 36 minutes, obliteration of the aneurysm was accomplished by means of Olivecrona and McKenzie clips.

**Postoperative Course.** In view of the long period of occlusion of the vessels in the neck and of a short period when her systolic blood pressure was only 60 mm Hg, grave concern was felt about the patient. In the immediate postoperative period she was aphasic and had a right hemiplegia as well as a complete left third nerve palsy and a right homonymous field defect. The third nerve palsy and aphasia cleared over a period of 1 to 2 weeks but the hemiplegia was slower to disappear and she required a period on an activation unit. Postoperative angiograms confirmed obliteration of the aneurysm (Fig. 4). She returned home in mid-June and was undertaking full household duties within 6 months from the time of the hemorrhage although she still had a mild spastic hemiparesis and a quadrantic homonymous field defect. She has continued to feel well and to participate in all family activities; she has been aided by a minor orthopedic procedure to the right foot.

#### Summary

We have presented the case of a 37-year-old woman who suffered a subarachnoid hemorrhage and who was found to have an

aneurysm arising from the basilar artery as well as agenesis of the left internal carotid artery. Obliteration of the aneurysm was effected with minimal residual deficit.

#### Acknowledgments

I would like to thank Drs. G. E. Trueman, W. B. Chung, and J. W. Cluff for their help.

#### References

1. BURMESTER, K., and STENDER, A. Zwei Fälle von einseitiger Aplasie der Arteria carotis interna bei gleichzeitiger Aneurysmabildung im vorderen Anteil des Circulus arteriosus Willisii. (Zur Frage Der Kombination von sackförmigen Aneurysmen der Hirnarterien mit anderen Fehlbildungen.) *Acta neurochir.*, 1961, 9: 367-378.
2. DRAKE, C. G. Bleeding aneurysms of the basilar artery. Direct surgical management in four cases. *J. Neurosurg.*, 1961, 18:230-238.
3. DRAKE, C. G. Surgical treatment of ruptured aneurysms of the basilar artery. Experience with 14 cases. *J. Neurosurg.*, 1965, 23:457-473.
4. DUKES, H. T., ODOM, G. L., and WOODHALL, B. The unilateral anterior cerebral circulation. Its importance in the management of aneurysms of the anterior communicating artery. *J. Neurosurg.*, 1965, 22:40-46.
5. HÖÖK, O., NORLÉN, G., and GUZMÁN, J. Saccular aneurysms of the vertebral-basilar arterial system. A report of 28 cases. *Acta neurol. scand.*, 1963, 39:271-304.
6. JAMIESON, K. G. Aneurysms of the vertebrobasilar system. Surgery intervention in 19 cases. *J. Neurosurg.*, 1964, 21:781-797.
7. JAMIESON, K. G. Aneurysms of the vertebro-

- basilar system: further experience with nine cases. *J. Neurosurg.*, 1968, 28:544-555.
8. KIRGIS, H. D., FISHER, W. L., LLEWELLYN, R. C., and PEEBLES, E. MCC. Aneurysms of the anterior communicating artery and gross anomalies of the circle of Willis. *J. Neurosurg.*, 1966, 25:73-78.
  9. LAGARDE, C., VIGOUROUX, R., and PERROUTY, P. Agénésie terminale de la carotide interne anévrysme de la communicante antérieure; documents radiologiques. *J. Radiol. Electrol.*, 1957, 38:939-941.
  10. LHERMITTE, F., GAUTIER, J. C., POIRIER, J., and TYRER, J. H. Hypoplasia of the internal carotid artery. *Neurology, Minneap.*, 1968, 18:439-446.
  11. MOUNT, L. A., and TAVERAS, J. M. Ligation of basilar artery in treatment of an aneurysm at the basilar-artery bifurcation. *J. Neurosurg.*, 1962, 19:167-170.
  12. RAND, R. W., JANNETTA, P. J. Micro-neurosurgery for aneurysms of the vertebralbasilar artery system. *J. Neurosurg.*, 1967, 27:330-335.
  13. TURNBULL, I. Agenesis of the internal carotid artery. *Neurology, Minneap.*, 1962, 12: 588-590.
  14. WISSINGER, J. P., DANOFF, D., WISIOL, E. S., and FRENCH, L. A. Repair of an aneurysm of the basilar artery by a transclival approach. Case report. *J. Neurosurg.*, 1967, 26:417-419.