

Extradural Hematoma Complicating Middle-Ear Infection

Report of a Case

VIRGILIO NOVAES, M.D. AND CARLOS GORBITZ M., M.D.*

Department of Neurosurgery, † Hospital Estadual Souza Aguiar, Guanabara, Brazil

Case Report

M.C.S., a 26-year-old white man, was admitted on September 8, 1963. He was very drowsy and the family gave a history of left middle-ear suppuration. For 2 days he had complained of severe headache and vomited several times. The secretion from his ear "became darker." One day before admission the patient had a convulsion beginning on the right side and then becoming generalized. After the seizure he was drowsy and apathetic.

Examination revealed a right hemiparesis and anisocoria with left midriasis, reaction to light being preserved. The fundus was normal. The patient was afebrile. X-rays of the skull and blood and urine analysis were normal. With a presumptive diagnosis of otitic temporal abscess, left carotid angiography was performed on the day of admission. There was a deviation of the anterior cerebral artery toward the right side, elevation of the Sylvian group and depression of the posterior cerebral artery, probably by a temporal lobe herniation (Fig. 1).

Operation. A subtemporal burr hole revealed the presence of an extradural hematoma. At craniotomy a huge hematoma, weighing 80 gm., mainly basal, was exposed and drained (see Fig. 2). There was diffuse

Received for publication June 22, 1964.

* Present address: University of Trujillo, Trujillo, Peru.

† Surgeon in chief: J. G. Silva Neves, M.D.

meningeal bleeding. The undamaged middle meningeal artery was occluded in the orifice of entry. Damage to the upper face of the petrous bone was found with a corresponding zone of pachymeningitis and venous bleeding. After hemostasis and fixation of the dura mater had been accomplished, the wound was closed in the usual manner.

Postoperative course was uneventful and the patient was discharged after 15 days. He is now working full time and is normal neurologically.

Discussion

Extradural bleeding as a complication of middle-ear infection is very rare. The literature contains only one report, by Schneider and Hegarty,⁵ of a patient with recurring suppurative infection of the middle ear with signs of a homolateral extradural mass. A diagnosis of otitic abscess of the temporal lobe was made and the patient died suddenly before operation could be performed. At necropsy a huge hematoma was found probably caused by rupture of the middle meningeal artery resulting from a necrotizing process extending to the foramen spinosum.

In the case we are reporting development of the hematoma was presumably secondary to recurrent bleeding from progressive detachment of the dura mater, a common occurrence in traumatic

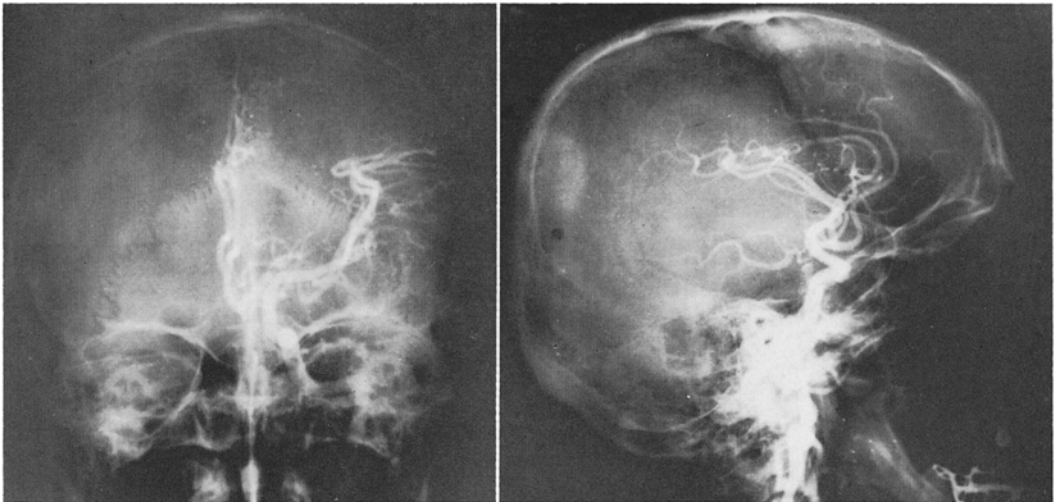


FIG. 1. Left anteroposterior (*left*) and lateral (*right*) angiogram showing the shift of the anterior cerebral artery toward the right side and medial displacement of the Sylvian arteries. Note in the lateral view the depression of the posterior cerebral artery indicating transtentorial herniation.

venous hematoma. The rarity of this complication in suppurative infection of the middle ear is probably attributable to the usual formation of a zone of pachymeningitis and bony-dural adhesions, with a consequent restraint of hemorrhagic oozing. The presumptive diagnosis of otitic abscess of the temporal lobe, could be modified only after surgical exposition of the hematoma. The same was true of the case reported previously.^{5,6} In our case, we decided to operate at once because angiographic findings indicated a tentorial pressure cone and the clinical signs (anisocoria) confirmed the existence of pressure.

Summary

A case of extradural hemorrhage following a middle-ear infection, apparently only the second in neurosurgical literature, is described. A review of the classical textbooks of surgical diseases has failed to reveal any references to this rare entity.¹⁻⁴

In the case of Schneider and Hegarty⁵ the course was acute and the bleeding proved to be arterial; the slow course in the present case is probably explained by the venous origin of the oozing. In both cases an incorrect initial diagnosis of otitic abscess of the temporal lobe was made.

References

1. BRUNNER, H. *Intracranial complications of ear, nose and throat infections*. Chicago: Year Book Publishers, Inc., 1946, xii, 444 pp.
2. COURVILLE, C. B., and ROSENVOLD, L. K. Intracranial complications of infections of nasal cavities

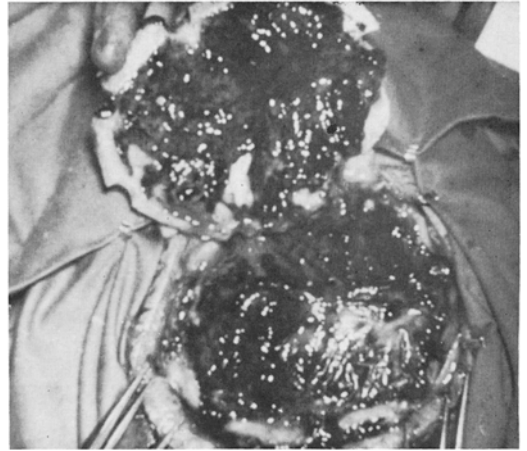


FIG. 2. Operative exposure of the extradural hematoma.

- and accessory sinuses. A survey of lesions observed in a series of fifteen thousand autopsies. *Arch. Otolaryng.*, Chicago, 1938, 27:692-731.
3. JACKSON, C., and JACKSON, C. L. [Ed.] *Diseases of the nose, throat, and ear. Including bronchoscopy and esophagoscopy*. Philadelphia: W. B. Saunders Co., 1945, xiv, 844 pp.
 4. MORRISON, W. W. *Diseases of ear, nose and throat*. New York: Appleton-Century-Crofts, Inc., 1948, xviii, 772 pp.
 5. SCHNEIDER, R. C., and HEGARTY, W. M. Extradural hemorrhage as a complication of otological and rhinological infections. *Ann. otol., etc., St. Louis*, 1951, 60:197-206.
 6. SCHNEIDER, R. C., and TYTUS, J. S. Extradural hemorrhage: factors responsible for the high mortality rate. *Ann. Surg.*, 1955, 142:938-948.