

THE RELATION OF ARTERIAL TRAUMA TO COMPLICATIONS OF CEREBRAL ANGIOGRAPHY*

By JOSEPH H. ALLEN, M.D.,† CARLOS PARERA, M.D.,‡ and D. GORDON POTTS, M.D.

THE complications of cerebral angiography have been investigated by many workers.²⁻⁷ Most of the studies reported in the literature have been retrospective and this has made it impossible to determine the causes of many of the complications. Nearly all of the authors suggest that some of the complications were associated with a difficult arterial puncture or the injection of some or all of the contrast material outside the lumen of the vessel, but the frequency with which extraluminal injections or difficult needle punctures are followed by serious complications has not been determined. Crawford¹ has demonstrated that postmortem examinations may show extensive damage to the artery when death occurs 2 hours to 8 months after angiography and some of the cases were apparently associated with complications during or following angiography.

A great number of angiographic complications have been described. These include the following:

1. Death.
2. Neurologic complications. Clinical symptoms and signs indicating involvement of almost any part of the brain may be seen on occasions. These are: (a) confusion or coma; (b) motor—hemiplegia, weakness, focal or generalized seizures; (c) sensory—numbness or paresthesias; (d) visual scotomata, field defects or blindness; (e) brachial neuritis (caused by needle damage to the brachial plexus); (f) damage to the recurrent laryngeal nerve causing hoarseness.

3. Evidence of ischemia in the arm (where the brachial, axillary, or subclavian artery is punctured).
4. Tracheal compression by a neck hematoma.
5. General or local allergic reactions to the contrast medium or the local or general anesthetic agents.
6. Cardiac complications: Hypertension (due to anxiety), hypotension, disorders of rhythm, heart failure.
7. Arteriovenous fistula.

To this list one may add some less significant or very rare complications, such as drug sensitivity to minimal doses, partial or complete occlusion of the vessel by subintimal hemorrhage, thrombosis at the site of puncture, stimulation of the carotid sinus by palpation or needling, air embolism, increase of intra-arterial pressure causing rupture of aneurysm, etc.

In order to be reasonably certain of the causes of most complications, a careful prospective study is required, with testing of the patient for sensitivity to the drugs used. Records should also be kept of the pulse and blood pressure, needling difficulties, evidence of arterial damage or extravascular injection of contrast material, the quantity of saline solution and contrast medium injected (and over what period). The roentgenograms taken should be carefully examined (in cases where there are complications) for evidence of air in the vessels or rupture of an aneurysm during the injection of contrast material.

The clinical status of the patient is likewise important since serious brain disease

* From the Department of Radiology, Columbia University, College of Physicians and Surgeons, and the Radiological Service of the Neurological Institute, Columbia-Presbyterian Medical Center, New York, New York.

† Special Training Fellowship, NIH, National Institute of Neurological Diseases and Blindness, 1F11 NB1167-01. Now at Department of Radiology, Vanderbilt University, School of Medicine, Nashville, Tennessee.

‡ Visiting Fellow in Radiology, NIH, National Institute of Neurological Diseases and Blindness, Neuroradiology Training Grant 5T1 NB5298-05. Now at Department of Neuroradiology, Institute of Neurological Sciences, Madrid, Spain.

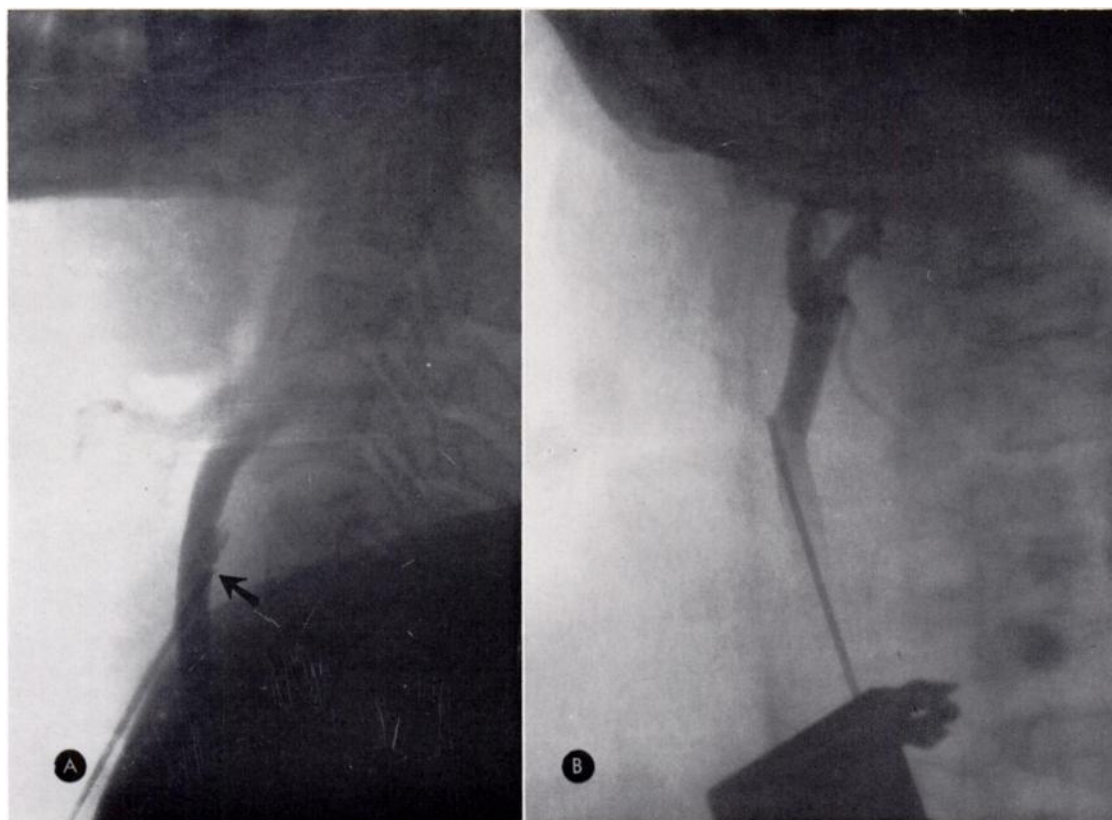


FIG. 1. Polaroid roentgenograms of the neck after injection of 2 cc. of contrast medium. (A) Lateral roentgenogram showing that the point of the needle lies against the posterior wall of the common carotid artery (arrow). There is a small quantity of subintimal contrast medium. (B) Anteroposterior roentgenogram of another case showing that the needle is pressing against the lateral wall of the artery. The point of the needle was positioned more medially before the main injection was made.

may make the patient unusually vulnerable to the risks of angiography.

PRESENT STUDY

The object of the present study was to determine how frequently difficult or traumatic punctures of the vessel or extraluminal injection of contrast material were associated with angiographic complications. The incidence of complications in cases where the needling of the vessels was difficult or the injection partly or completely outside the lumen of the vessel was compared with the incidence of complications in cases where the puncture was simple and the injection "clean".

The study includes carotid, retrograde brachial, and vertebral angiograms obtained under local anesthesia and with

moderate sedation. Renografin 60 per cent was used for the carotid and vertebral angiographies and hypaque 50 per cent for the brachial angiography.

An intravenous test dose of the contrast medium was given shortly before the angiography to detect any unusual drug sensitivity. After puncturing the vessel with a Cournand type of needle, a 2 cc. injection of contrast medium was made and simultaneous anteroposterior and lateral Polaroid roentgenograms were taken to prove that the needle was correctly positioned within the vessel (Fig. 1, A and B). If found necessary, the position of the point of the needle was altered to place it near the center of the vessel. A simultaneous biplane technique was employed so that the anteroposterior and lateral roentgenograms

could be obtained with a single injection of contrast medium. Ten cc. was used for carotid angiography in adults and 6 cc. for vertebral angiography; 35-45 cc. was usually injected for brachial angiography. The lateral roentgenograms included the neck vessels permitting, in carotid and vertebral angiography, the ready recognition of imperfect injections. It is important to note that only the grossest errors of needle placement may be recognized by the way the blood flows back from the needle. During many of the injections the angiographer felt confident that he had performed a "clean" puncture because of the free back flow of blood; however, the Polaroid films revealed that the contrast material was partially subintimal. Almost all injections were made with a Taveras mechanical injector and between injections the tubing and needle were kept clear of clots by intermittent manual injection of saline solution.

The blood pressure was recorded at intervals throughout the examination and hand strength was measured before, during, and after the examination with a dynamometer. These objective strength measurements were found helpful in the early recognition of certain complications. A weakness of the hand strength measured in this way on one side was sometimes the earliest sign of a developing hemiplegia. Gradual reduction of the strength of both hands was

TABLE I

Angiographic Diagnosis	No. of Cases
Normal	161
Vascular occlusive disease	57
Aneurysms, arteriovenous malformations or follow-up studies on these cases	55
Tumors	104
Subdural, epidural or intracerebral hematomas	9
Others (junctional dilatations, abscesses, questionable diagnosis)	14
Total	400

TABLE II

Artery	No. of Examinations	No. of Injections
Right Carotid	157	219
Left Carotid	240	341
Right Brachial	65	96
Left Brachial	38	46
Right Vertebral	14	17
Left Vertebral	24	28
Total	538	747

seen when the sedation was increased.

This series includes data compiled from 400 patient visits for angiography: 538 examinations were performed and 41 patients made more than one visit. Unsuccessful examinations are included even if no contrast material was injected, but at least an attempt was made to puncture the artery. The angiographic examinations were done between September 1963 and April 1964 and the only cases eliminated from the series were those whose records were incomplete. In 281 instances one single vessel and in 101 instances two vessels were injected. The angiographic diagnoses are shown in Table I. The number of examinations performed on each vessel and the number of injections (excluding the 2 cc. injections made before the Polaroid roentgenograms were taken) are shown in Table II.

COMPLICATIONS

In this series of 538 examinations there were 21 complications (3.9 per cent) which included 1 death, 1 permanent right hemiplegia and 19 complications from which the patient recovered after a variable period of time. The findings in the cases that showed complications are summarized in Table III. The two most serious complications are described in more detail below.

CASE 1. J.O., a female aged 59 years, presented with a hemorrhage from a right posterior communicating aneurysm which was treated by right internal carotid artery occlusion in the neck in 1955. Postoperative angiography showed no filling of the aneurysm from either

TABLE III

Case No.	Age	Complication	Vessels Injected*	Difficult Arterial Puncture	Subintimal Contrast	Angiographic Diagnosis and Comments
1	59	Patient became unresponsive after main injection of contrast medium; death 36 hours later	<i>LCA</i>	No	Yes (total extravasation of contrast medium)	Right carotid aneurysm; previous right carotid ligation
2	56	Right hemiparesis and patient became obtunded 4 hours after arteriography; permanent hemiparesis and aphasia	<i>LCA</i>	No	Yes (wall of vessel irregular due to needle trauma)	Left middle cerebral aneurysm
3	65	Transient right hemiparesis; complete recovery in 6 hours	<i>LVA</i>	No	No	Normal
4	56	Aphasia, cleared in 24 hours	<i>LCA</i>	Yes	Yes	Normal
5	68	Severe blood pressure drop during examination; recovered in a few hours	<i>LCA</i>	No	No	Cerebral atheroma
6	52	Numbness of left side; complete clearing in 2 days	<i>RBA</i>	No	No	Cerebral atheroma
7	52	Hives (lasted 2 days)	RCA RBA	No	Yes	Atherosclerotic vascular disease
8	33	Weakness of left arm after attempted left vertebral injection; complete recovery in 4 days	<i>LVA</i> LBA	Yes	Yes	Left cerebellar hemangioblastoma
9	57	Aphasia, apraxia and confusion; recovered in 2 days	RCA <i>LCA</i>	No	Yes	Left sided aneurysm and atherosclerosis
10	51	Loss of vision in both eyes; gradual recovery over 2 days	<i>LCA</i>	No	No	Arteriovenous malformation; the left vertebral artery may have been accidentally punctured
11	69	Aphasia and confusion; recovered in 2 days	<i>LCA</i>	No	Yes (roentgenograms showed irregularity of artery near needle)	Glioblastoma
12	68	Dysphasia, worse after examination; returned to pre-angiographic state in 2 days	<i>LCA</i>	No	No	Temporo-thalamic tumor
13	51	Blood pressure drop to 80/60, returning to normal in 1 hour	<i>RCA</i>	Yes	No	Normal
14	51	Confusion, dysphasia and mild right sided weakness; cleared in 6 hours	RBA LBA <i>LCA</i> (retrograde injection)	No	Yes	Atherosclerosis
15	66	Right arm weakness; complete clearing in 2 days	RCA <i>LCA</i>	No	Yes	Normal
16	55	Right arm weakness and confusion; cleared in 24 hours	<i>LCA</i>	Yes	Yes	Normal
17	47	Low blood pressure at intervals for 24 hours	<i>RCA</i>	Yes	Yes	Unsatisfactory angiogram
18	50	Intermittent fall of blood pressure for 4 hours	<i>LCA</i>	Yes	Yes	Normal
19	38	Hives (lasted 12 hours)	<i>LCA</i>	No	No	Normal
20	50	Blind spots, scotoma, nausea and vomiting lasting 4 hours	RCA <i>LCA</i>	Yes (both sides)	Yes (both sides)	Right sphenoid ridge meningioma
21	55	Loss of voice, and hoarseness due to recurrent laryngeal involvement; recovered in 12 hours	<i>LVA</i>	No	No	Normal

* LCA Left carotid artery

RCA Right carotid artery

LVA Left vertebral artery

RVA Right vertebral artery

LBA Left brachial artery

RBA Right brachial artery

The vessel italicized is presumed to be the one concerned in the complication.

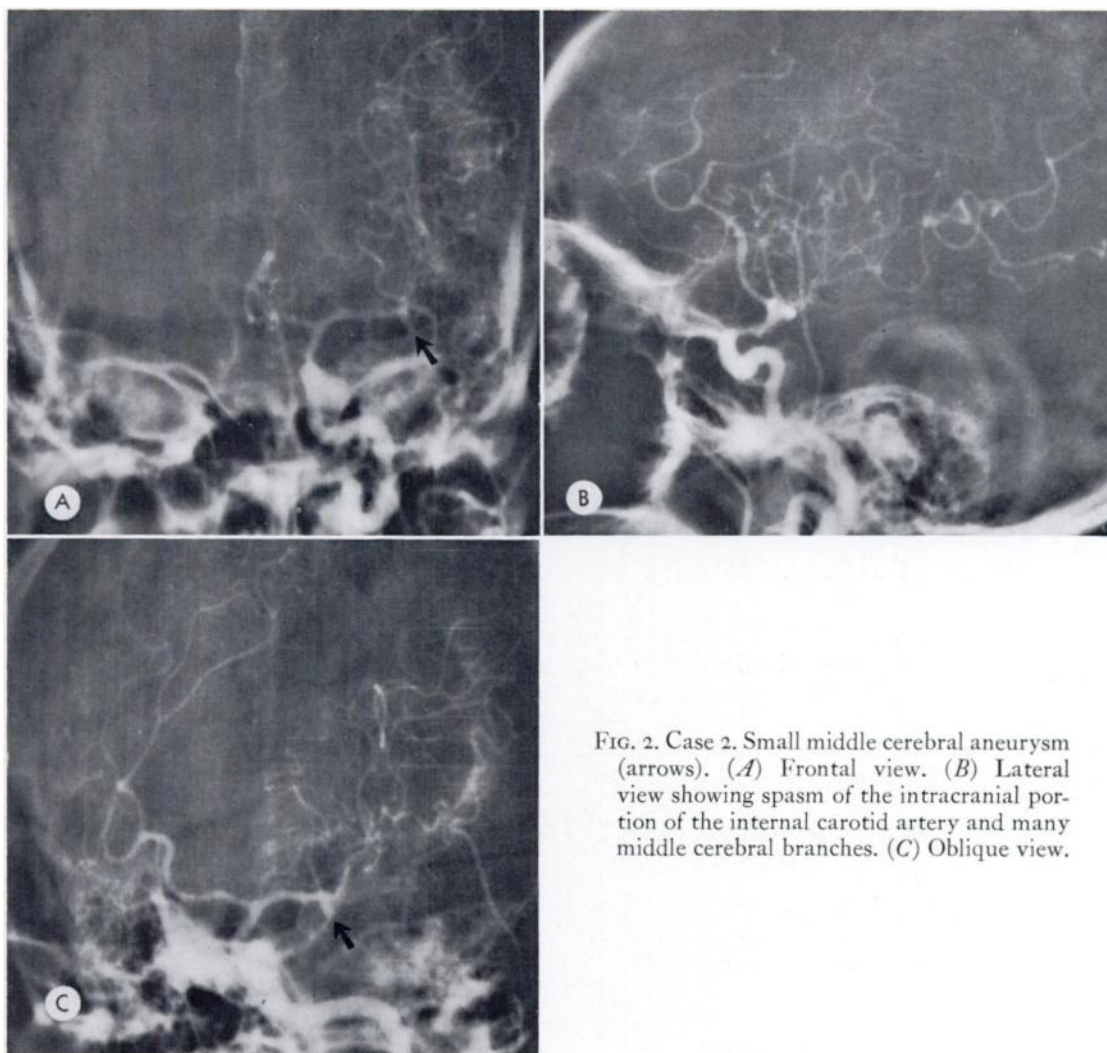


FIG. 2. Case 2. Small middle cerebral aneurysm (arrows). (A) Frontal view. (B) Lateral view showing spasm of the intracranial portion of the internal carotid artery and many middle cerebral branches. (C) Oblique view.

side and the right internal carotid artery was shown to be completely occluded. In 1959 she developed headaches and a right third cranial nerve lesion and angiography showed recanalization of the internal carotid artery. Because there was no evidence of a further subarachnoid hemorrhage on this occasion, the patient was treated conservatively.

One day before her final admission the patient had a subarachnoid hemorrhage.

Angiography. Two injections of 2 cc. of contrast material were made into the left common carotid artery in order to check the needle position with Polaroid films and then the main injection of 10 cc. was made. Most of the contrast material during this last injection was

injected subintimally. Immediately after this injection the patient became decerebrate. The right leg was more spastic than the left and the left eye was deviated to the right. Fifteen minutes later the patient was very restless but she could not move her right limbs as well as the left. The right pupil was contracted to pinpoint and she was markedly hypotensive. She gradually deteriorated and death occurred 36 hours later.

CASE 2. L.W., a male aged 56 years, was known to have had hypertension (up to 260/150) for 15 years. Seven days before admission the patient had a subarachnoid hemorrhage which was followed by aphasia and a right

hemiparesis, both of which gradually improved.

Angiography. A left common carotid angiography was performed using a total of 22 cc. of contrast medium. Frontal, lateral and oblique views showed a middle cerebral aneurysm with marked associated vascular spasm and a low convexity subdural hematoma (Fig. 2, *A, B* and *C*). Four hours after the study the patient became obtunded, there was a more dense hemiplegia and the patient was more aphasic. Sixteen months later the patient still had some left sided weakness and severe aphasia but was ambulatory.

DIFFICULT ARTERIAL PUNCTURE

Where more than 4 attempts were made with the needle before the artery was punctured, the puncture was recorded as difficult. It is recognized that what may be a difficult puncture for one operator may be easy for another, but by classifying it in this way we have a crude indication of the trauma inflicted on the artery and its adjacent tissues. One hundred fourteen (21 per cent) of the 538 vessels injected, or where puncture was attempted, were classified as difficult; of these 114 difficult punctures 10 (9.6 per cent) were associated with complications.

Of the 21 cases showing angiographic complications, 7 (33 per cent) were difficult to puncture.

SUBINTIMAL INJECTIONS

In 38 of the 538 examinations (7.1 per cent) some subintimal or extraluminal contrast medium injection occurred and of these 9 showed all of the contrast medium outside the lumen of the vessel. Of the 21 cases showing complications, 13 (62 per cent) were recorded as having some subintimal contrast medium.

DISCUSSION

Of the 21 cases with angiographic complications, 14 had either a difficult puncture or subintimal injection of contrast medium or both. It seems almost certain that, in some cases, an intimal dissection was caused by the injection of saline solu-

tion and if this damage occurred after the angiograms were taken, it would usually not be recognized. Therefore, it is probable that more complications than those recorded were associated with narrowing of the lumen by subintimal dissection. The only death in the series was associated with a subintimal injection when left common carotid angiography was performed on a patient who had previously had the right internal carotid artery ligated.

It has sometimes been suggested that damage to the vessel does not occur when catheter techniques are used. However, it seems likely that the percutaneous insertion of a catheter into a vessel causes at least as much damage to the vessel as a puncture with a Cournand type of needle but any narrowing caused by the puncture is not usually seen unless the catheter is only inserted a short distance into the vessel or the reflux is sufficient to opacify the vessel at the point where the wall is punctured.

Serious allergic complications may nearly always be avoided if the patient is asked about drug sensitivity in advance and an intravenous test dose of the contrast medium is given. Hypertension is generally caused by apprehension and may generally be controlled by increased sedation. Hypotension may be induced by painful stimuli or traumatic needling, particularly of the carotid sinus, and may be corrected with intravenous ephedrine. Most of the more serious neurologic complications in this series appear to have been associated with difficult or traumatic punctures of the vessel or subintimal or extravascular injections. Presumably most of these complications are caused by cerebral ischemia secondary to a traumatic examination. These complications should be greatly reduced by an atraumatic puncture. The direct toxic effects of the contrast medium undoubtedly cause some complications but these can be reduced by injecting the smallest possible quantity of contrast medium and by avoiding repeated injections at short intervals.

When the simultaneous biplane technique of filming is not used and each projection requires a further injection of contrast medium, larger quantities of the medium are employed and it is to be expected that the toxic effects of the medium will increase.

The findings in the series of cases suggest that, when a simultaneous biplane technique is employed for cerebral angiography with the injection of relatively small quantities of contrast medium, over one-half of the complications are caused by trauma to the vessel or subintimal injection of contrast material. Presumably, as larger quantities of contrast material are injected during angiography, the importance of the toxicity of the contrast medium increases in relation to arterial trauma.

SUMMARY

In a series of 538 angiographic studies on 400 patients there were 21 complications including 1 death and 1 permanent hemiplegia. All of the remaining complications cleared within 4 days.

The evidence suggests that when simultaneous biplane angiography is used, and small quantities of contrast medium are injected, trauma to the artery and subintimal injection of the contrast material are the most common causes of complications, and that true toxic effects of the contrast me-

dium (other than allergic reactions) are rare.

D. Gordon Potts, M.D.
Department of Radiology
Neurological Institute
Columbia—Presbyterian Medical Center
622 West 168th Street
New York, New York 10032

The authors wish to acknowledge the assistance of Dr. Juan M. Taveras in the preparation of this paper.

REFERENCES

1. CRAWFORD, T. Pathological effects of cerebral arteriography. *J. Neurol., Neurosurg., & Psychiat.*, 1956, 19, 217-221.
2. FIELD, J. R., ROBERTSON, J. T., and DE SAUSURE, R. L., Jr. Complications of cerebral angiography in 2,000 consecutive cases. *J. Neurosurg.*, 1962, 19, 775-781.
3. KAPLAN, A. D., and WALKER, A. E. Complications of cerebral angiography. *Neurology*, 1954, 4, 643-656.
4. KENDALL, B. Cerebral angiography using Conray. *Brit. J. Radiol.*, 1964, 37, 581-589.
5. LINDNER, D. W., HARDY, W. G., THOMAS, L. M., and GURDJIAN, E. S. Angiographic complications in patients with cerebrovascular disease. *J. Neurosurg.*, 1962, 19, 179-185.
6. NEWTON, T. H., and COUCH, R. S. C. Possible errors in arteriographic diagnosis of internal carotid artery occlusion. *Radiology*, 1960, 75, 766-773.
7. PATTERSON, R. H., JR., GOODELL, H., and DUNNING, H. S. Complications of carotid arteriography. *Arch. Neurol.*, 1964, 10, 513-520.

