

TRAUMATIC ANEURYSM OF THE INTRATHORACIC LEFT CAROTID ARTERY WITH CEREBRAL EMBOLIZATION

JOE A. PINKERTON, JR., M.D., EDWIN E. MACGEE, M.D., AND K.G. ROMINE, M.D.

From the Department of Surgery, Truman Medical Center and the University of Missouri at Kansas City School of Medicine, and St. Luke's Hospital of Kansas City, Kansas City, Missouri

The presentation and management of a young male patient with a traumatic aneurysm of the intrathoracic portion of the left common carotid artery from a football injury, complicated by cerebral embolization, is detailed. At operation 6 weeks afterward the aneurysm was isolated and ligated and the patient was discharged 19 days postoperation with plans for physical and speech rehabilitation. At 14 months a chronic subdural hematoma which caused some seizures was removed, and the patient's neurologic status is continuing to improve. This appears to be the first report of an isolated blunt injury to this branch of the aortic arch.

Blunt injury of the thoracic aorta and its brachiocephalic branches is a well recognized consequence of violent trauma. Acute hemorrhage is the usual result of this injury, but it may present on a delayed basis as a false aneurysm which may enlarge, rupture, or result in embolization. This paper discusses the course and management of a patient with a traumatic aneurysm of the intrathoracic portion of the left carotid artery complicated by cerebral embolization.

CASE REPORT

A 23-year-old male was examined in the emergency room of Kansas City General Hospital following blunt trauma to the left shoulder and neck incurred while playing football. Clinical and radiologic examination of this patient, including X-rays of the cervical spine and clavicle appeared normal. The symptoms were pain and soreness in the local area. The patient returned 5 days later with a 12-hour history of severe left-sided headaches and a 4-hour history of right hemiparesis, aphasia, and bladder and anal incontinence. He was found to be lethargic, with a bruit audible over the base of the neck on the left side, and right hemiplegia, with right homonymous hemianopia.

Evaluation at the time of admission included a chest X-ray which appeared normal, and arteriography which demonstrated a false aneurysm of the left carotid artery approximately 2 cm distal to its origin from the aortic arch (Fig. 1). An intimal flap was evident in the distal portion of this aneurysm, apparently the result of a traumatic tear of the left

carotid artery (Fig. 2). The left middle cerebral artery was occluded intracranially from what appeared to be an embolus from the traumatic aneurysm in the proximal left carotid artery. The aortic arch and other brachiocephalic vessels were normal, with no other evidence of injury to these vessels.

The patient was initially anticoagulated with Coumadin (Endo) for 10 days* and given Decadron (Merck, Sharpe & Dohme) for one week. Definitive surgical treatment of the traumatic aneurysm was deferred for 6 weeks because of the completed stroke which had occurred. Minimal evidence of neurologic improvement was noted during this period.

At operation a median sternotomy with proximal extension into the neck along the anterior border of the left sternocleidomastoid muscle was used for the surgical approach to this traumatic aneurysm. Initially, a ligature was passed around the proximal left carotid artery which was later to be ligated. A 10-mm preclotted knitted Dacron graft was anastomosed end-to-side to the ascending aorta. The left common carotid artery was transected distal to the traumatic aneurysm and anastomosed end-to-end to the Dacron graft. The proximal end of the transected left carotid artery was oversewn and the previously placed silk ligature tied securely proximal to the traumatic aneurysm. This isolated the aneurysm without requiring dissection or removal of the aneurysm itself. Systemic heparinization was employed during the arterial reconstruction. Prostaphlin (Bristol) was given prophylactically for 4

* The use of anticoagulants here can certainly be argued because while it is not usually indicated in acute stroke, according to many it is the treatment of choice in embolization, and one must make the decision as to whether the risk of using anticoagulants is greater or less than the risk of not using them (Eds.).

Address for reprints: Joe A. Pinkerton, Jr., M.D., 4320 Wornall Road, Kansas City, MO 64111.

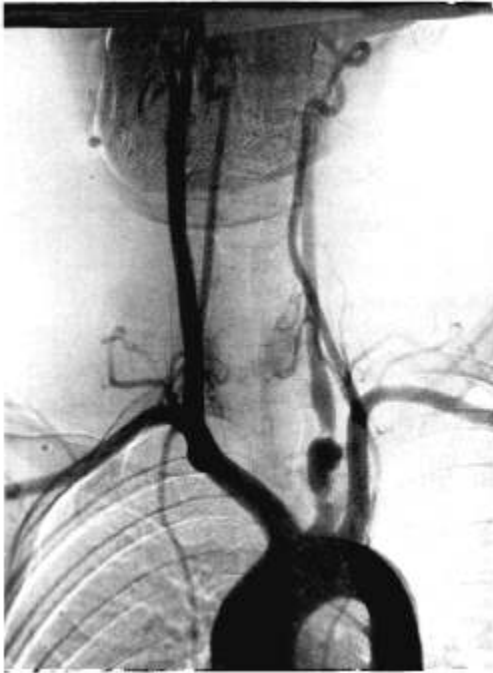


FIG. 1. Arch aortogram demonstrating the false aneurysm of the left carotid artery.

days postoperatively. Mediastinal drainage tubes were removed 48 hours postoperatively. No neurologic deterioration could be detected in the postoperative course which was uneventful and uncomplicated. The patient was discharged on the 19th postoperative day with plans for continued rehabilitation and speech therapy.

The patient's long term postoperative course has demonstrated slow, continued neurologic improvement. Approximately 14 months postoperatively, he began having seizures and was found to have an area of intracranial calcification over the frontal portion of the left cerebral hemisphere. Arteriography and computerized tomography demonstrated a chronic subdural hematoma in this area, whereas there had been no evidence of a subdural hematoma in the patient's initial clinical picture. Arteriography demonstrated patency of the arterial reconstruction. The chronic subdural hematoma was removed through a left frontal craniotomy. The patient's neurologic status continues to improve slowly.

DISCUSSION

Traumatic tear of the thoracic aorta and its major branches is associated with such a high acute mortality that the majority of the patients with this injury fail to reach the emergency room with hope of survival (6). The

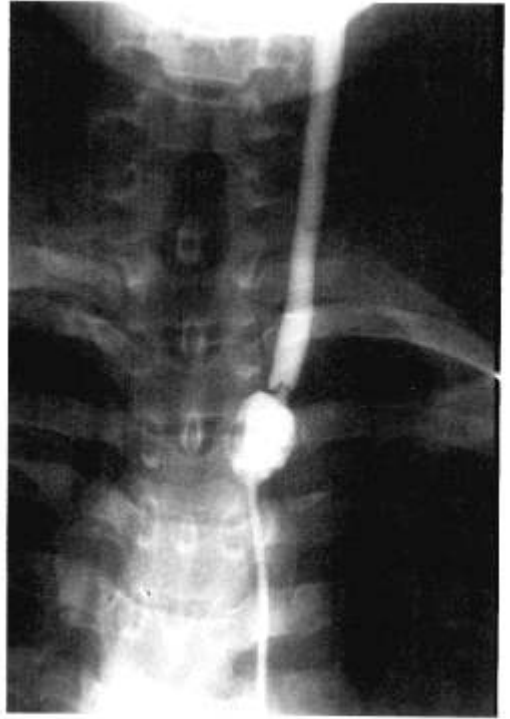

FIG. 2. Selective arteriogram of the left common carotid artery demonstrating the false aneurysm and the prolapsing torn distal edge of the vessel wall.

gravity of this injury has led to an acute awareness of its occurrence in major trauma centers. The diagnosis in a stable patient is predicated on a high degree of suspicion, widening of the mediastinum or hemothorax on chest X-ray, and abnormal brachiocephalic pulses or neurologic symptoms unrelated to head trauma. Aortography establishes the diagnosis definitively and demonstrates the location and extent of the injury. Tear of the major intrathoracic vessels without clinical or chest X-ray evidence to suggest such an injury is rare, although it has been reported (2). Isolated blunt injury to the brachiocephalic branches of the thoracic aorta occur less commonly, and the risk of exsanguination before hospital arrival is not clearly defined (2). Trauma violent enough to tear these major vessels is usually associated with injuries to other structures. The absence of any clinical or radiographic evidence of vascular injury and the absence of associated injuries resulted in a delay in the diagnosis of intrathoracic vascular injury in our patient.

This patient may represent the first case

reported with isolated blunt injury to the intrathoracic left carotid artery. Castagna and Nelson (2) in 1974 published an excellent review of blunt injuries to branches of the aortic arch. They found 36 patients with 40 vascular injuries. Their review and a review of the subsequent English-language literature did not produce a report of a similar blunt injury to this branch of the aortic arch.

Blunt injury to the cervical portion of the carotid artery has been reported by many authors (3-5, 9, 10), but this injury occurs much less frequently than carotid arterial injuries associated with penetrating trauma to the neck (9, 10). Blunt injury to the cervical portion of the carotid artery is often overlooked initially only to have the patient suddenly develop hemiplegia after a lucid interval which may be as short as a few hours or as long as 2 weeks (4). The diagnosis of blunt injury to the carotid may be obscured by the absence of any evidence of injury or by the presence of extensive associated injuries. The mechanism of injury is related to disruption of the wall of the artery, which may involve only the intima, producing a roughened focus which may be the source of emboli or complete thrombosis of the artery (3, 5). The tear may involve the media and result in either thrombosis of the artery or the formation of a false aneurysm, as occurred in our patient. Both intimal and medial tears may result in prolapse of the torn distal edge of the vessel wall, as seen in Figure 2.

Aneurysms of the extracranial carotid artery have the potential for rupture, thrombosis, and embolization. Only 42 patients had reportedly undergone surgical reconstruction after resection of a carotid artery aneurysm in an English-language literature review published in 1972 by Rittenhouse (7). Traumatic aneurysms have been reported much less frequently than true aneurysms of the carotid artery (8).

The surgical approach to blunt injury of the carotid artery varies with the time of recognition and clinical state of the patient. Injuries recognized acutely and in the absence of neurologic deficit should be repaired promptly. Acute repair of carotid artery injuries in the presence of neurologic deficit is associated with increased mortality (10). A delayed presentation associated with a major neurologic deficit and a stabilized clinical state warrants a delay

of 4 to 6 weeks, in keeping with the accepted approach to atherosclerotic occlusive disease of the carotid artery (10).

The surgical approach to the intrathoracic portion of the left carotid artery for management of traumatic injuries or aneurysmal changes may present a technical challenge. A median sternotomy with a cervical extension was chosen in our patient as the best single exposure to provide simultaneous proximal and distal control and allow reconstruction of the left carotid artery. Other surgical approaches which could be considered include reflection of a flap of the left anterior chest wall for exposure of the left carotid artery, or separate cervical and left thoracotomy incisions, as described by Brawley (10). Other methods of reconstruction of the left carotid artery which may be feasible include direct anastomosis of the left carotid artery to the left subclavian or a similar reconstruction with an interposed Dacron or vein graft.

REFERENCES

1. BRAWLEY RK, MURRAY GF, CRISLER C et al: Management of wounds of the innominate, subclavian, and axillary blood vessels. *Surg Gynecol Obstet* 131:1130, 1970
2. CASTAGNA J, NELSON RJ: Blunt injuries to branches of the aortic arch. *J Thorac Cardiovasc Surg* 69:521, 1975
3. CRISSEY MM, BERNSTEIN EF: Delayed presentation of carotid intimal tear following blunt cranio-cervical trauma. *Surgery* 75:543, 1974
4. JERNIGAN WR, GARDNER WC: Carotid artery injuries due to closed cervical trauma. *J Trauma* 11:429, 1971
5. MCGOUGH EC, HELFRICH LR, HUGHES RK: Traumatic intimal prolapse of the common carotid artery. *Am J Surg* 123:724, 1972
6. RITTENHOUSE EA, DILLARD DH, WINTERSCHIED LC et al: Traumatic rupture of the thoracic aorta: A review of the literature and a report of five cases with attention to special problems in early surgical management. *Ann Surg* 170:87, 1969
7. RITTENHOUSE EA, RADKE HM, SUMNER DS: Carotid artery aneurysm. *Arch Surg* 105:786, 1972
8. ROBINSON NA, FLOTTE CT: Traumatic aneurysms of the carotid arteries. *Am Surg* 40:121, 1974
9. RUBIO PA, REUL GJ, BEALL AC et al: Acute carotid artery injury: 25 years' experience. *J Trauma* 14:967, 1974
10. THAL ER, SNYDER WH, HAYES RJ et al: Management of carotid artery injuries. *Surgery* 76:955, 1974