

Case Reports

MALIGNANT-THROMBOSIS SYNDROME : PANCREATIC CARCINOMA PRESENTING WITH BILATERAL CEREBRAL THROMBOSIS IN A YOUNG WOMAN

B. J. SEALEY, M.B., M.R.C.P.,
*Medical Registrar,
Birmingham General Hospital*

E. L. JONES, M.B., Ch.B.,
*Department of Pathology,
University of Birmingham*

The occurrence of venous thrombosis with carcinoma is well recognised, as first described by Trousseau (1873). In recent years it has been found that arterial occlusion can also occur in patients with neoplasms (Oelbaum & Strich, 1953; Williams, 1954; Fisher & Baird, 1956) and that arteriolar and capillary occlusion may involve the brain (Smith, 1961, 1962).

Case Report

The patient was a previously healthy 39-year-old housewife. She was not taking oral contraceptives. On 29th October, 1964, she awoke with a right hemiparesis and was admitted to hospital some hours later.

On examination she showed weakness of the right face, arm and leg, a right Babinski response, and total right hemianaesthesia. BP 150/80 mm. Hg., pulse rate 90, in sinus rhythm. There were no abnormal signs elsewhere in the body. Rectal and vaginal examinations were negative.

Investigations: Hb 78%, WBC 5,600/cu. mm., normal differential count. ESR (Westergren) 10 mm/hr. Serum Na 132, K 4.1, Cl 92 mEq/l. Blood urea 32, cholesterol, 187 mg/100 ml., CSF: normal pressure with a free rise and fall, 1 lymphocyte/cu. mm., protein 25 mg/100 ml. WR and Kahn negative. Skull and chest X-rays normal. ECG normal.

On 9th November, 1964, she developed a total left hemiplegia with aphasia and increased involvement of the right side, no pyrexia or cardiac murmurs.

Bilateral carotid angiograms (Fig. 1) showed occlusion of the right middle cerebral artery 1 cm. beyond its origin, the left posterior parietal artery, and the angular branches of the left middle cerebral artery. There was an anastomotic supply from the anterior cerebral arteries. No evidence of atherosclerosis. Phenindione therapy was commenced. A glucose tolerance test showed a definite diabetic curve: FBS 110, $\frac{1}{2}$ hr., 190, 1 hr., 240, $1\frac{1}{2}$ hr., 230, 2 hr. 200 mg/100 ml.

On 26th November, 1964, she developed sudden dyspnoea and right pleuritic pain. The left calf was slightly tender. Chest X-ray showed bilateral diffuse nodular shadowing coalescent in the midzones, probably due to multiple pulmonary infarcts. At this time anticoagulant therapy was thought adequate from estimations of prothrombin times.

On 3rd December, 1964, gross swelling of the left thigh and leg developed suggesting extension of the deep vein thrombosis. Intravenous heparin therapy (40,000 units/day) was started.

Further investigations: Hb 65%, WBC 6,100/cu. mm., polys 80%, ESR 16mm/hr. No LE cells. Blood fibrinogen 63 mg/100 ml. Ham's acid serum test negative. Direct Coombs' test negative. Serum bilirubin 1.8 mg/100 ml. Haptoglobin normal. Alkaline phosphatase 23 K-A units/100 ml. SGOT 24 units/ml., SGPT 13 units/ml., ECG normal, in sinus rhythm.

Heparin was discontinued after 12 days. Phenindione therapy was recommenced, a rash then developed and ethyl biscoumacetate (Tromexan) was substituted. Prothrombin levels were 2 to 2½ times normal controls, but on 14th January, 1965, sudden left chest pain with dyspnoea and haemoptysis indicated further pulmonary infarction. Heparin therapy was resumed.

On 18th January, 1965, she complained of upper abdominal discomfort, the spleen was enlarged, and the temperature 102°F. Three blood cultures were negative. The bone marrow was normoblastic and macronormoblastic with no evidence of secondary carcinoma or reticulosis.

On 31st January, 1965, she was jaundiced and began to vomit. A mass was noted in the epigastrium, the liver was palpable and the spleen much larger. Diplopia developed and she became unconscious. Death occurred on 8th February, 1965, from hypostatic bronchopneumonia.

The diabetic glucose tolerance test, evidence of widespread vascular occlusion and the terminal epigastric mass strongly suggested a pancreatic carcinoma.

Necropsy: The body (height 5' 6", weight 51.45 kg) was that of a young well-nourished female with jaundice and minimal oedema of the left leg and arm. *Pancreas* was of normal size, but there was an ill defined, hard, greyish-white mass of tumour 5 cm. \times 3 cm. in the middle third of the body. The distal third of the body and tail showed dilatation of ducts, fat necrosis and parenchymal atrophy, indicating chronic duct obstruction. *Lymph nodes* in the porta hepatis and around the coeliac axis and pancreas were firm, enlarged and replaced by metastases. *Spleen* (435 g.) was enlarged and showed an extensive yellow-white-necrotic infarct (8 cm.) surrounded by dark congested pulp. The splenic vein was thrombosed. *Liver* (1570 g.) contained multiple necrotic, umbilicated secondary deposits. Its cut surface was mottled and displayed alternating pale and dark congested areas. The portal vein was completely occluded by firm organising antemortem thrombus and the intrahepatic radicals contained small strands of propagated thrombus. *Kidneys* (340 g.) were symmetrically enlarged, the left con-

Downloaded from https://www.cambridge.org/core. University of Birmingham, on 07 Feb 2020 at 10:07:38, subject to the Cambridge Core terms of use, available at https://www.cambridge.org/core/terms. https://doi.org/10.1017/S0022278X00000000

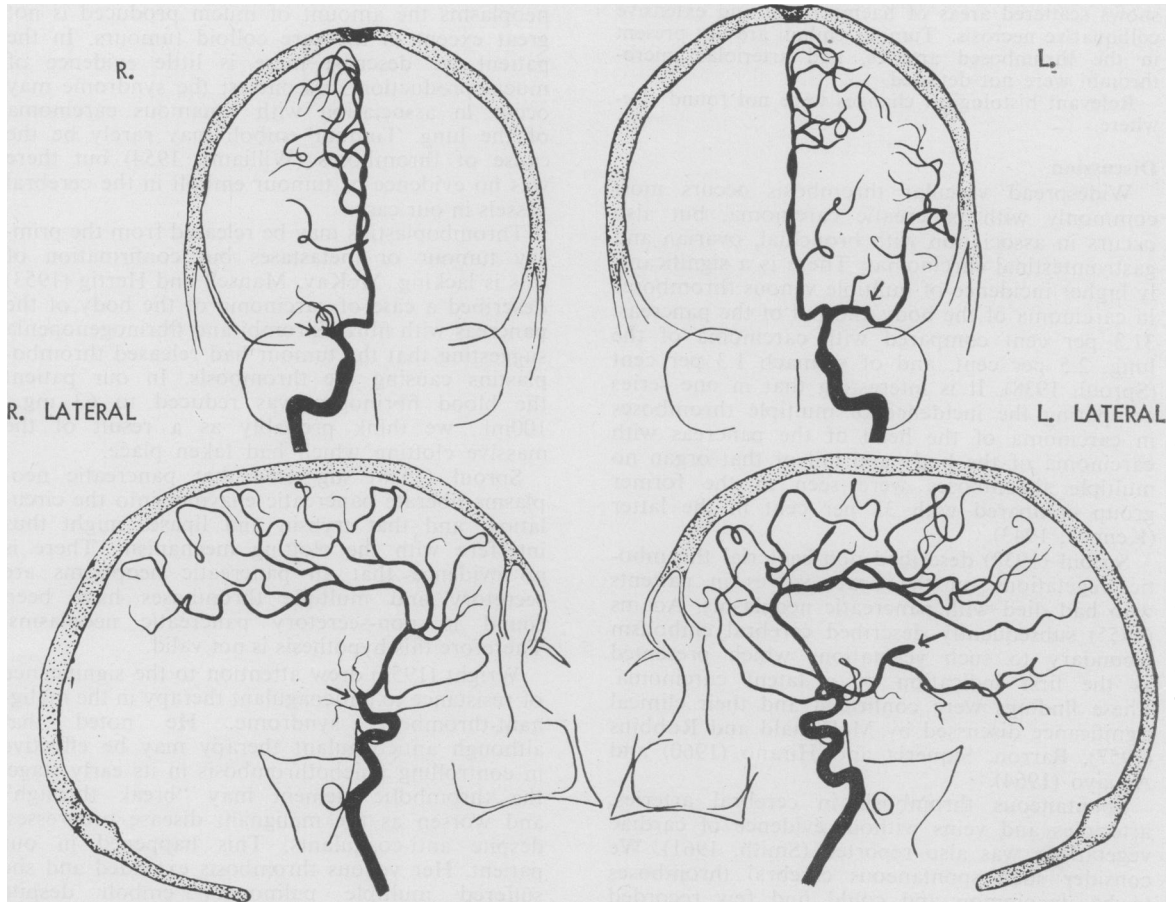


FIG. 1.—The right middle cerebral artery is absent beyond the first cm. (Arrow).

The posterior parietal and angular branches of the left middle cerebral are absent. (Arrow).

tained multiple white infarcts, the largest 6 cm. The left renal vein was thrombosed and a mass of propagated thrombus extended into the left supra-renal vein. The inferior vena cava contained several unattached portions of antemortem thrombus. The common and both internal and external iliac veins contained old and recent organising antemortem thrombi, which extended into both superficial femoral veins. *Heart* (275 g.) showed no changes. In particular the endocardium and valves were unaffected. The pulmonary artery was normal but several of its terminal branches showed thrombotic occlusion. *Lungs* showed multiple small wedge-shaped infarcts. Their bases were firm, nodular and congested. *Carotid Arteries* and main branches, the circle of Willis and the vertebral arteries did not show atheroma. *Brain*. The right middle cerebral artery was thrombosed over a small segment just proximal to its trifurcation. The left middle cerebral artery also showed a smaller thrombosed area just beyond its first division. These thrombi were old and

consistent in age with the presenting cerebro-vascular accidents. There was a recent thrombotic occlusion of the right posterior cerebral artery. The brain was swollen and oedematous showing widespread softening in the right middle and posterior cerebral artery distribution territory.

The remaining organs did not show macroscopical changes.

Histology.—*Pancreas*. The tumour is a well-differentiated large-duot-cell adenocarcinoma showing a marked fibrous stromal reaction, scattered foci of mucous secretion and infiltration of small nerves. The tail shows diffuse fibrosis and atrophy. A number of small vessels are thrombosed. *Liver* shows widespread areas of necrosis. The metastatic deposits display a pronounced degree of differentiation with ciliation of the large cells, a feature seldom seen in pancreatic carcinoma. (Frantz, 1959). *Lungs* show old organising haemorrhagic infarcts, tumour emboli in the peribronchial and perivascular lymphatics, and areas of bronchopneumonia. *Spleen and Kidneys* are

congested and show pale necrotic infarcts. *Brain* shows scattered areas of haemorrhage and extensive colliquative necrosis. Tumour emboli are not present in the thrombosed arteries, and arteriolar microthrombi were not detected.

Relevant histological changes were not found elsewhere.

Discussion

Widespread vascular thrombosis occurs most commonly with pancreatic carcinoma, but also occurs in association with bronchial, ovarian and gastrointestinal carcinomas. There is a significantly higher incidence of multiple venous thromboses in carcinoma of the body and tail of the pancreas, 31.3 per cent compared with carcinoma of the lung, 2.5 per cent, and of stomach 1.3 per cent (Sproul, 1938). It is interesting that in one series comparing the incidence of multiple thromboses in carcinoma of the head of the pancreas with carcinoma of the body and tail of that organ no multiple thromboses were seen in the former group compared with 33 per cent in the latter (Kenney, 1943).

Sproul (1938) described non-bacterial thrombotic vegetations on the heart valves in patients who had died with pancreatic neoplasms. Adams (1955) subsequently described cerebral embolism secondary to such vegetations which presented as the first indication of a latent carcinoma. These findings were confirmed and their clinical significance discussed by McDonald and Robbins (1957), Barron, Siqueria and Hirano (1960) and Aguayo (1964).

Spontaneous thrombosis in cerebral arteries, arterioles and veins without evidence of cardiac vegetations was also reported (Smith, 1961). We consider such spontaneous cerebral thromboses to be uncommon and could find few recorded cases.

Smith (1957, 1961) found neurological disorders attributable to the malignant-thrombosis syndrome in 10 out of 993 consecutive fatal cases of carcinoma. The primary tumours were as follows: 4 pancreatic, 2 uterine, 2 gastric, one mammary and one bronchial. In 6 of the cases, major neurological complications i.e., hemiplegia, first appeared within a week of death. In the remaining 4 cases, 4 weeks, 6 weeks, 20 weeks and 2 years before death respectively.

The relationship between thrombosis and tumours has not been clarified (Aguayo 1964). Toxic, metabolic, haemodynamic and immunological factors have been suggested as being important in causing the thrombotic tendency, particularly in non-bacterial endocarditis (Angrist, Oka, Nakao and Marquiss, 1960).

Trousseau (1873) first suggested that thrombosis resulted from hypercoagulability of the blood but no alterations in clotting factors have been described.

Some authors considered thromboses to be particularly related to mucin-producing tumours (Kenney, 1943; Jennings and Russell, 1948;

McKay, Mansell and Hertig, 1953). In pancreatic neoplasms the amount of mucin produced is not great except in the rare colloid tumours. In the patient we describe there is little evidence of mucin production. In contrast the syndrome may occur in association with squamous carcinoma of the lung. Tumour emboli may rarely be the cause of thromboses (Williams, 1954) but there was no evidence of tumour emboli in the cerebral vessels in our case.

Thromboplastins may be released from the primary tumour or metastases but confirmation of this is lacking. McKay, Mansell and Hertig (1953) described a case of carcinoma of the body of the pancreas with fibrin thrombi and fibrinogenopenia suggesting that the tumour had released thromboplastins causing the thrombosis. In our patient the blood fibrinogen was reduced to 63 mg./100ml., we think probably as a result of the massive clotting which had taken place.

Sproul (1938) suggested that pancreatic neoplasms liberate pancreatic enzymes into the circulation, and that trypsin and lipases might thus interfere with the clotting mechanism. There is no evidence that all pancreatic neoplasms are secretory and multiple thromboses have been found in non-secretory pancreatic neoplasms. Therefore this hypothesis is not valid.

Wright (1952) drew attention to the significance of resistance to anticoagulant therapy in the malignant-thrombosis syndrome. He noted that although anticoagulant therapy may be effective in controlling phlebothrombosis in its early stage, the thrombotic element may "break through" and worsen as the malignant disease progresses, despite anti-coagulants. This happened in our patient. Her venous thrombosis extended and she suffered multiple pulmonary emboli despite Tromexan therapy judged adequate by the Quick one-stage prothrombin estimation. Treatment with heparin on the other hand was thought clinically to have brought about resolution of her femoral vein thrombosis judged by a reduction of nearly 7" in the circumference of the affected thigh and the non-recurrence of clinically obvious pulmonary emboli.

Considering the widespread nature of the metastases in this patient and in view of the observations of O'Meara and O'Halloran (1963) on the use of protamine in preventing the spread of the neoplasm, it is interesting to speculate whether heparin actually promoted more widespread dissemination of the tumour.

An interesting feature in our patient is that though previously healthy she developed sudden hemiplegia. Cerebrovascular incidents described previously usually occurred in patients with well-marked symptoms or in an advanced stage of the disease. The second factor is that though she was too ill for adequate barium studies of the gastrointestinal tract the diabetic GTT provided a clue to the presence of a pancreatic neoplasm. There is a significant relationship between pan-

creatic neoplasms and abnormal glucose tolerance (Bell, 1957).

The persistence of clotting and pulmonary emboli despite adequate oral anticoagulants is significant and confirms Wright's (1952) opinion that the possibility of an occult neoplasm should be considered when this phenomenon occurs.

Finally the unusual finding of ciliated cells in the metastatic deposits is noteworthy because of its rarity.

Summary

A case of pancreatic carcinoma in a woman of 39 is described which presented with hemiplegia and hemianaesthesia which subsequently became bilateral. Despite anticoagulant therapy widespread venous and arterial thrombosis occurred with recurrent pulmonary emboli.

The current theories concerning the association between neoplasia and vascular thrombosis are reviewed. Little is known of the exact cause of this association.

We are indebted to Dr. P. H. Davison under whose care this patient was admitted, for his permission to publish this case.

We also wish to thank Dr. D. B. Brewer and Dr. W. T. Smith for their helpful advice and criticism and Dr. P. B. Carpenter for the preparation of the carotid angiogram diagrams.

We would also like to thank Miss K. G. Ruud for typing the manuscript.

REFERENCES

- ADAMS, R. D. (1955): Case Record 41491 of Mass. Gen. Hosp., *New Engl. J. Med.*, **253**, 1030.
- AGUAYO, A. J. (1964): Cerebral Thrombo-Embolicism in Malignancy, *Arch. Neurol. (Chic.)*, **11**, 500.
- ANGRIST, A. A., OKA, M., NAKAO, K., MARQUISS, J. A. (1960): Studies in Experimental Endocarditis I. Production of Valvular lesions by Mechanisms not involving Infection or Sensitivity Factors, *Amer. J. Path.*, **36**, 181.
- BARRON, K. D., SIQUERIA, E., and HIRANO, A. (1960): Cerebral Embolism Caused by Non-bacterial Thrombotic Endocarditis, *Neurology (Minneapolis)*, **10**, 391.
- BELL, E. T. (1957): Carcinoma of the Pancreas, IA. Clinical and Pathologic Study of 609 Necropsic Cases. II. The Relation of Carcinoma of the Pancreas to Diabetes Mellitus, *Amer. J. Path.*, **33**, 499.
- FISHER, E. R., and BAIRD, W. F. (1956): *Amer. J. Path.*, **32**, 1185.
- FRANTZ, V. K. (1959): Tumours of the Pancreas, Atlas of Tumour Pathology, Armed Forces Institute of Pathology, Section VII—Fascicles 27 and 28, p. 60.
- JENNINGS, W. K., and RUSSELL, W. O. (1948): Phlebothrombosis Associated with Mucin-Producing Carcinomas of Tail and Body of Pancreas; Clinicopathological Study of 2 Cases with Necropsy, *Arch. Surg.*, **56**, 186.
- KENNEY, W. E. (1943): Association of Carcinoma in Body and Tail of Pancreas with Multiple Venous Thrombi, *Surgery*, **14**, 600.
- MCDONALD, R. A., and ROBBINS, S. L. (1957): The Significance of Non-bacterial Thrombotic Endocarditis: An Autopsy and Clinical Study of 78 Cases, *Ann. intern. Med.*, **46**, 255.
- MCKAY, D. G., MANSELL, H., and HERTIG, A. T. (1953): Carcinoma of Body of Pancreas with Fibrin Thrombosis and Fibrinogenopenia, *Cancer*, **6**, 862.
- OELBAUM, M. H., and STRICH, S. J. (1953): Thrombophlebitis Migrans and Carcinoma of the Body and Tail of Pancreas, *Brit. med. J.*, **ii**, 907.
- O'MEARA, R. A. Q., and O'HALLORAN, M. J. (1963): Protamine Derivatives in the Treatment of Advanced Carcinoma of the Breast, *Lancet*, **ii**, 613.
- SPROUL, E. E. (1938): Carcinoma and Venous Thrombosis: The Frequency of Association of Carcinoma in the Body or Tail of the Pancreas and Multiple Venous Thromboses, *Amer. J. Cancer*, **34**, 566.
- SMITH, W. T. (1957): Studies on the Association of Carcinoma and Neuropathy which is not Attributable to Neural Metastases, M.D. Thesis, University of Birmingham.
- (1961): Neurological Disorders Associated with Malignant Disease, *Postgrad. med. J.*, **37**, 282.
- (1952): IV. International Congress of Neuro-pathology: Cerebral Lesions due to the Thrombotic Syndrome associated with Carcinoma, Vol. III, Stuttgart: George Thieme Verlag.
- TROUSSEAU, A. (1873): *Clinique Medicale de l'Hôtel-Dieu de Paris*, 3,695. 4th edition. Paris: Baillière.
- WILLIAMS, A. A. (1954): Malignant Disease Associated with Vascular Phenomena, *Brit. med. J.*, **ii**, 82.
- WRIGHT, I. S. (1952): *The Pathogenesis and Treatment of Thrombosis*. 1st edition, p. 16. New York: Grune and Stratton.