

Dural sinus thrombosis in paroxysmal nocturnal hemoglobinuria

Steven P. Donhowe* and Reynaldo P. Lazaro*.

Introduction

Paroxysmal Nocturnal Hemoglobinuria (PNH) is a rare hemolytic anemia characterized by attacks of nocturnal intravascular hemolysis and hemoglobinuria. Pancytopenia, marrow hypoplasia, iron deficiency, and recurrent thrombotic episodes are also features of the disease. Men and women are affected, and the disorder is non-familial. It occurs in various racial groups, and the diagnosis is usually made in the third to fifth decade. The most serious complication and cause of mortality in PNH is thrombosis of the portal or cerebral venous system¹. Reports on cerebral vein and sinus thrombosis secondary to PNH are meager²⁻⁴. It is an underrecognized cause of stroke in young adults. An illustrative case is presented in this communication.

Case history

Recurrent episodes of body weakness, headache, substernal and abdominal pain, and dizziness accompanied by occasional pigmenturia, developed in this 33-year-old black male three years prior to neurologic evaluation. A positive sucrose water test and Ham test substantiated the diagnosis of PNH. An episode of acute right hemiparesis with gradual recovery occurred four months before admission,

Summary

Dural sinus thrombosis developed in a young man with paroxysmal nocturnal hemoglobinuria (PNH). His neurological disorder developed in the face of anemia and a urinary tract infection. Progressive neurological deterioration occurred in spite of anticoagulation, antibiotic and steroid therapy. The propensity to develop cerebral vein and sinus thrombosis in PNH may be due to release of thromboplastin material from hemolyzed red blood cells, the interaction of complement with red blood cells and platelets, or from increased sensitivity to platelet aggregation.

Key words: Paroxysmal nocturnal hemoglobinuria, sinus thrombosis

followed by a seizure disorder well controlled with Phenytoin and Phenobarbital. Acute visual obscuration in the right eye followed by a progressively worsening occipito-frontal headache developed one week before admission. On physical examination he was awake and alert, but complaining of severe headache. He was afebrile, and his vital signs were normal. His neck was supple, and carotid pulses were normal without bruits. On cardiac examination a grade II/VI systolic murmur was present at the apex. On neurological examination, visual acuity was 9/200 OD and 20/400 OS. The right

* Department of Neurology, Albany Medical College of Union University, Albany, New York 12208

Address for correspondence and reprint requests to Reynaldo P. Lazaro, M.D., Department of Neurology, Albany Medical College of Union University, Albany, New York 12208

Steven P. Donhowe, M.D. is now at Boston University, School of Medicine, Boston, Massachusetts 02130

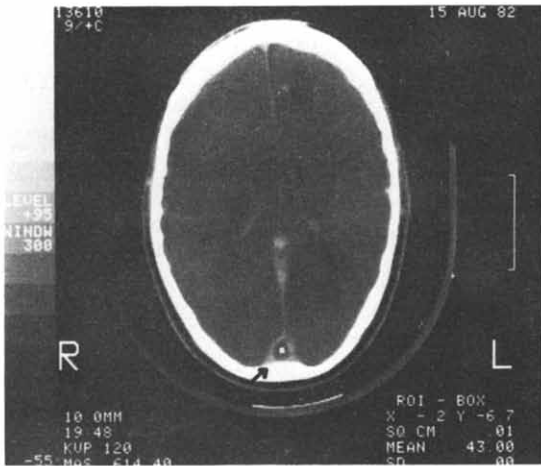


Fig. 1a.
CT scan with contrast demonstrates non-filling of the posterior extension of the superior sagittal sinus (arrow). White dot in the center is an X-ray marker.

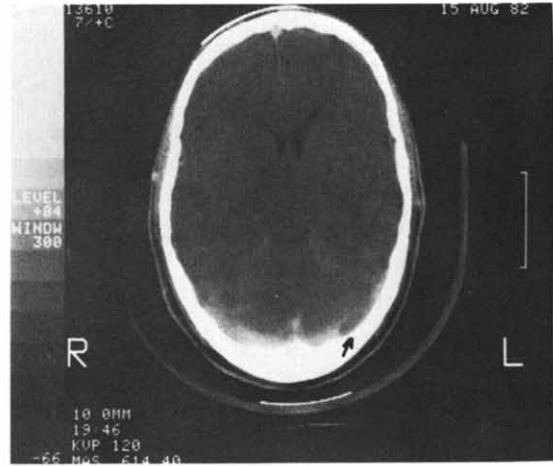


Fig. 1b.
A filling defect is seen in the left lateral sinus (arrow).

pupil was 5 mm, the left pupil 2 mm, and both reacted to light. A vitreous hemorrhage and posterior vitreous separation with attachment at the disc, as well as an inferotemporal retinal tear, were present in the right fundus. The remainder of the neurological examination was normal. The initial hemogram showed: hemoglobin, 8.7 gm/dl; hematocrit, 26.0%; white blood cells (WBC), $14.9 \times 10^3 \text{ mm}^3$ with 12% bands, 68% neutrophils and 14% monocytes; and platelet count, $167,000/\text{mm}^3$. Prothrombin time was 11.6 seconds (control = 11.3 seconds) and partial thromboplastin time 26.5 seconds (control = 34.8 seconds). Abnormal blood chemistry values included the following: lactic dehydrogenase 915 U/L (N = 90-200 U/L); serum glutamic oxaloacetic transaminase 100 U/L (N = 0-45 U/L); and alkaline phosphatase, 126 U/L (N = 4-85 U/L). Ham test and sucrose water test was positive. Hemosiderin was present in the urine. Iron binding capacity was 192 ug/dl (N = 250-390 ug/dl), and serum iron 55 ug/dl (N = 65-150 ug/dl). Urine analysis showed 12 WBC/hpf and marked bacteriuria.

On the third hospital day he developed mild fever. Two units of washed, frozen red blood cells were transfused on the fourth hospital day. The next day he became lethargic and developed right gaze preference, left central facial weakness, left hemiparesis and anosognosia. A computed tomographic scan (CT)

demonstrated non-filling of the posterior extension of the superior sagittal sinus, and a filling defect in the left lateral sinus (Figs. 1a and b). There was also an area of hypodensity in the right temporo-parietal region with gyral enhancement and compression of the adjacent ventricle at higher level. A lumbar puncture produced clear, colorless, cerebrospinal fluid (CSF) (OP = 330 mm H₂O) containing 64 WBC per mm³ (99% neutrophils, 1% lymphocytes) and 16 red blood cells (RBC) per mm³. The CSF glucose was 92 mg/dl and protein 132 mg/dl. Bacterial and fungal cultures were negative. Heparin and dexamethasone were given intravenously but nuchal rigidity developed the following day, and his temperature rose to 39.5°C. He remained lethargic, but arousable, and the focal motor deficits persisted. Moxalactam and Penicillin were started, and another 2 units of washed, frozen red blood cells were transfused. In spite of these, he became progressively comatose and died. Permission for autopsy was not obtained.

Discussion

A structural membrane defect in red blood cells is the underlying pathological cause of PNH, but the nature of this defect has not been elucidated. Granulocytes and platelets also share this membrane defect. This membrane instability is demonstrated diagnostically in the

acidified serum (Ham test), which reflects the propensity of PNH red blood cells to hemolyze in an acid medium. The sucrose water test reflects the excessive hemolysis of normal serum¹. The structural lesion accounts for the increased susceptibility of red blood cells to the lytic action of complement. Chronic hemolytic anemia ensues, typically with attacks of hemolysis and hemoglobinuria during sleep. In addition to sleep-related hemolysis and hemoglobinuria, irregular exacerbation of hemolysis may be asymptomatic, or may present with headache, drowsiness, substernal, lumbar or abdominal pain, or with dysphagia and painful swallowing¹. Exacerbation of hemolysis can occur due to a variety of causes including infection, transfusion with whole blood, surgery, menstruation, vaccinations, and a variety of drugs including ascorbic acid, nicotinic acid, riboflavin, iron salts and quinine^{1,3,5}. Venous thrombosis has a tendency to occur after exacerbations of increased hemolysis³. The cause of the susceptibility to venous thrombosis has been attributed to several mechanisms including the release of thromboplastin material from hemolyzed erythrocytes^{6,7}, the interaction of complement components with hemolyzed RBC, or with complement sensitive platelets of patients with PNH, may also predispose to thrombosis¹. Increased sensitivity to platelet aggregation by ADP, collagen and epinephrine has also been found⁸.

The relentless deterioration of this man's neurologic illness attests to the poor prognosis of PNH once the cerebral venous system is comprised by thrombotic complication. Furthermore, the decline in his neurologic status may have been aggravated by lumbar puncture. The clinical presentation of cerebral venous and dural sinus thrombosis is variable, depending on the extent and location of the thrombosis. Headache, papilledema, and increased CSF pressure may occur if thrombosis remains confined to the superior sagittal sinus⁹. When the thrombotic process extends to the cortical veins, infarction, focal deficits and impaired consciousness occur. Hemiparesis, visual field defects, alexia, aphasia, apraxia, conjugate gaze palsy, meningismus, and bladder dysfunction with loss of voluntary control have been observed^{10,11}. Focal or generalized seizures may

also occur.

Most pathologically verified cases of cerebral vein thrombosis have involved more than partial obliteration of a single sinus. The superior sagittal sinus is the most frequently involved. Venous thrombosis produces edematous, congested cortex and white matter with petechial hemorrhages and a greater tendency for hemorrhagic infarction¹². Endothelial proliferation within the venous vessels, and focal necrosis of the walls of the thrombosed cerebral veins with polymorphonuclear cell infiltrate are also seen¹³.

CSF may show elevated protein and red blood cells, and the pressure may be high. The polymorphonuclear pleocytosis in our patient might have been due to cerebral infarction, while his nuchal rigidity could be attributed to transtentorial herniation or bleeding. However, because of accompanying fever, it is possible that his course was complicated by central nervous system infection despite negative cultures for microorganisms.

Although the definitive diagnosis is made by cerebral angiogram¹⁴, characteristic features exist for accurate and sometimes early diagnosis by CT scan. In non-contrast CT scan, hemorrhagic and ischemic infarcts, cord sign (a high density clot in a cerebral cortical vein), small ventricles and intracerebral hematomas may be found. With contrast CT studies, gyral and tentorial enhancement, empty delta sign^{15,16} (Fig. 1a) and dilated transcerebral medullary veins are frequent features that aid in diagnosis. The empty delta sign represents a thrombus within the sinus, surrounded with contrast material in the wall of the sinus and collateral veins. This sign appears early, and is valuable in the early diagnosis of sinus thrombosis¹⁶. Angiographic features consist of non-visualization of the dural sinuses, prolonged arteriovenous circulation time, dilated dural and venous collateral channels, and reversal of collateral flow. Retrograde jugular venography may show obstruction of sinuses and intraluminal thrombi¹⁴.

Treatment of cerebral vein and superior sagittal sinus thrombosis, regardless of the cause, is controversial. Beneficial treatment of cerebral vein thrombosis with heparin was first reported by Stansfield with subsequent reports

favoring the use of anticoagulation¹⁷⁻¹⁹. The threat of causing intracerebral hemorrhage by using heparin in the setting of venous thrombosis and cerebral vein infarction contraindicates its use according to others^{4,11-13,20}. The use of osmotic agents, such as mannitol, has been recommended for reduction of increased intracranial pressure⁴. Others argue that the dehydration that results from use of mannitol or similar agents predisposes to increased coagulability and further thrombosis^{12,13}. Urokinase a thrombolytic agent, was used effectively in some patients^{14,21} but its efficacy is counterbalanced by potentially dangerous alteration in hemostasis due to depletion of plasminogen, which in the face of already hemorrhagic cerebral infarction, can be vital. Inhibition of platelet function with antiplatelet medications in PNH has been recommended on the evidence that hypersensitive platelets may play a role in the pathogenesis of thrombosis⁸. Reduction of increased intracranial pressure with steroids has been used^{4,13} and craniotomy has occasionally been employed¹⁹. Factors associated with cerebral vein thrombosis, such as dehydration, cachexia, trauma, pregnancy and puerperium, and oral birth control pills² should be recognized, and the increased risk of thrombosis anticipated.

References

- 1 WINTROBE MM. Paroxysmal nocturnal hemoglobinuria. In: Wintrobe MM, ed. *Clinical hematology*. 8th edition. Philadelphia: Lee and Febiger, 1981:978.
- 2 STIRLING ML, LENTON RJ, SUMERLING MD. Cerebral vein thrombosis and the contraceptive pill in paroxysmal nocturnal hemoglobinuria. *Scot Med J* 1980; 25:243
- 3 JOHNSON RV, KAPLAN SR, BLAILOCK ZR. Cerebral venous thrombosis in paroxysmal nocturnal hemoglobinuria. *Neurology (Minneapolis)* 1970; 20:681.

- 4 GETTELFINGER DM, KOKMEN E. Superior sagittal sinus thrombosis. *Arch Neurol* 1977; 34:2.
- 5 CROSBY WH. Paroxysmal nocturnal hemoglobinuria: Relation of the clinical manifestations to underlying pathogenic mechanism. *Blood* 1953; 8:769.
- 6 MCKELLAR M, DACIE JV. Thromboplastic activity of the plasma in paroxysmal nocturnal haemoglobinuria. *Br J Haematol* 1958; 4:404.
- 7 NEWCOMB TF, GARDNER FH. Thrombin generation in PNH. *Br J Haematol* 1963; 9:84.
- 8 STEINBERG D, CARVALHO AC, CHESNEY CM, COLMAN RW. Platelet hypersensitivity and intravascular coagulation in paroxysmal nocturnal hemoglobinuria. *Am J Med* 1975; 59:845.
- 9 VAN CREVEL H. Pathogenesis of raised cerebrospinal fluid pressure. *DOC Ophthalmol* 1982; 52:251.
- 10 SMITH BH. Infections of the dura and its venous sinuses. In: Baker AB, Baker LH, eds. *Clinical Neurology*. Philadelphia: Harper and Row 1973. Vol. 2:12.
- 11 BARNETT HJM, HYLAND HH. Non-infective intracranial venous thrombosis. *Brain* 1953; 76: 36.
- 12 AVERBACK P. Primary cerebral venous thrombosis in young adults: The diverse manifestations of an underrecognized disease. *Ann Neurol* 1978; 3:81.
- 13 DINDAR F, PLATTS ME. Intracranial venous thrombosis complicating oral contraception. *Can Med Assoc J* 1974; 111:545.
- 14 VINES FS, DAVIDS DO. Clinical-radiological correlation in cerebral venous occlusive disease 1971; 98-9.
- 15 BUONANNO FS, MOODY DM, BALL MR. Computed cranial tomographic findings in cerebral sino-venous occlusion. *J Comput Assist Tomogr* 1978; 2:281.
- 16 KRISHNA CVG, KNIPP HC, WAGNER EJ. Computed tomographic findings in cerebral sinus and venous thrombosis. *Radiology* 1981; 140:391.
- 17 STANSFIELD FR. Puerperal cerebral thrombophlebitis treated by heparin. *Br Med J* 1942; 1:436.
- 18 KRAYENBUHL HA. Cerebral venous and sinus thrombosis. *Clin Neurosurg* 1966; 14: 1.
- 19 FARIBURN B. Intracranial venous thrombosis complicating oral contraception: Treatment by anticoagulant drugs. *Br Med J* 1973; 2:647.
- 20 BUCHANAN DS, BRAZINSKY JH. Dural sinus and cerebral venous thrombosis. *Arch Neurol* 1970; 22:440.
- 21 DIROCCA C, IANELLI A, LEONE G, MOSCHINI W, VALORI VM. Heparin-urokinase treatment in aseptic dural sinus thrombosis. *Arch Neurol* 1981; 38:431.