



Long term EEG analytical and neurological follow-up study in completed stroke patients after extra-intracranial vascular anastomosis

H. Wassmann, K.H. Holbach & D.K. Böker

To cite this article: H. Wassmann, K.H. Holbach & D.K. Böker (1984) Long term EEG analytical and neurological follow-up study in completed stroke patients after extra-intracranial vascular anastomosis, *Neurological Research*, 6:3, 115-117, DOI: [10.1080/01616412.1984.11739674](https://doi.org/10.1080/01616412.1984.11739674)

To link to this article: <https://doi.org/10.1080/01616412.1984.11739674>



Published online: 20 Jul 2016.



Submit your article to this journal [↗](#)



Citing articles: 2 View citing articles [↗](#)

Communication

Long term EEG analytical and neurological follow-up study in completed stroke patients after extra-intracranial vascular anastomosis

H. Wassmann, K.H. Holbach*, and D.K. Böker

Neurochirurgische Universitätsklinik, D 5300 Bonn-Venusberg, West Germany
*Neurochirurgische Abt., Katharinen-Hospital, D 7000 Stuttgart, West Germany

In 33 chronic stroke patients, who had internal carotid or middle cerebral artery occlusion that resulted in neurological deficit persisting for an average of more than 10 weeks, it was possible to perform a postoperative follow-up study for a period of six to eight years after extra-intracranial vascular anastomosis.

Serial neurological examinations with grading of motor deficit and EEG analyses were performed to assess the clinical course of the cerebral lesion.

These long term examinations showed a postoperative continuing improvement of electrical brain activity in nearly two thirds of the patients, nine patients showed no significant changes and three worsened. The EEG analytical findings correlated well to the neurological findings. An increase of electrical brain activity was bilateral with accentuation over the affected hemisphere, a phenomenon known from follow-up nrCBF measurements after anastomosis. During the follow-up one patient died five years, one six years following stroke under signs of cardiovascular disease, and one after six years suffering from a recurrent stroke opposite to the side of anastomosis.

In conclusion the findings indicate that EEG analysis is of value for assessment of long term follow-up of cerebral ischaemic lesions, chronic ischaemic alterations of the brain can be improved by anastomosis, and especially in comparison to a non-operated group of stroke patients, the course of the operated one seemed to be more advantageous, as the five-year survival rate of the Framingham study for stroke victims is 69%.

Keywords: EC/IC bypass, EEG analysis, hyperbaric oxygen therapy

INTRODUCTION

In our clinic, extra-intracranial arterial bypass (EIAB) operation has been carried out since 1974 in certain patients with occlusive cerebrovascular disease. To assess the long term effectiveness of this operation, all these patients have been subjected to neurological investigations at six months to one year intervals. Thirty-three patients had this operation in the chronic poststroke stage and their follow-up for 6 to 8 years with regard to neurological function and significance of EEG studies is the subject of this study.

MATERIAL AND METHODS

The following case history illustrates our method of studying these patients: A 55 year old female suffered a stroke in May 1977 with left hemiplegia due to right internal carotid artery occlusion. Within two weeks the hemiplegia improved from zero to eight points (eighteen points represent the normal motor power of one side) (Figure 1). On admission to our clinic one month later she was in a chronic poststroke stage with moderately severe left hemiparesis (neurological score: eight points). She was given hyperbaric oxygen

therapy (HOT) which resulted in improvement of the left hemiparesis by another three points¹. This was considered to be evidence for the partial reversibility of the neurological deficit and was the indication for bypass operation, which was carried out in July 1977. Postoperative angiography showed a functioning bypass with filling of the territory of the left middle cerebral artery. In the course of the next six months there was further improvement of the left hemiparesis by three points and at the end of the second year by another point. The residual hemiparesis involves distal muscles and remains unaltered up to the present. The patient however feels well and is able to carry out full household activities.

Computer analysis EEG shows a significant increase of Alpha-activity on the affected side during the first year after surgery. There is also slight increase of Beta-activity with decrease of Theta-activity. With the exception of a transient increase in the postoperative period, the Delta-activity shows no essential changes. During the observation period, the original EEG (Figure 2) shows a reduction of the focus in the right temporo-parietal region with accentuation of Alpha waves.

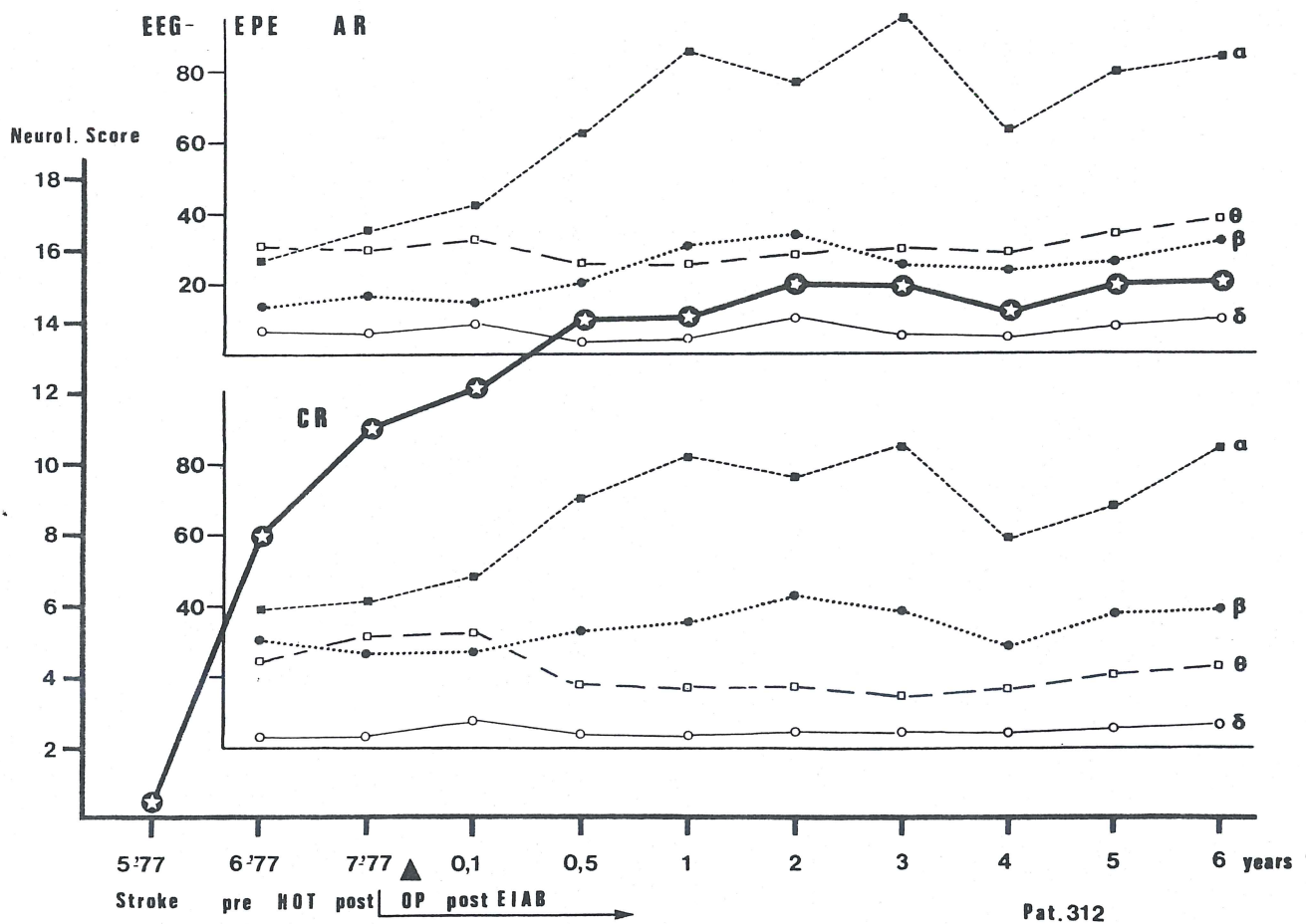


Figure 1. Neurological (star) and EEG analytical follow-up examinations of a patient with right internal carotid artery occlusion undergoing hyperbaric oxygen therapy (HOT) and extra-intracranial arterial bypass (EIAB) operation. Electrical power equivalent (EPE) values of the affected (AR) and contralateral region (CR) are divided in the Beta-, Alpha-, Theta- and Delta-wave-range. Neurological score represents the sum of motor power (6 points represent normal motor power) of hand, arm and leg.

A total of thirty three patients in chronic poststroke stage were treated by EIAB operation. Twenty-six were men and seven women with a median age of 50.3 years. The cause of vascular insufficiency was carotid occlusion in 28 cases and middle cerebral artery occlusion in 5 cases. The indication for bypass operation was improvement under hyperbaric oxygen therapy in all cases.

RESULTS

All these patients showed a patent bypass in the postoperative period as determined by Doppler sonography and angiography.

As a result of observation of these patients over a period of six to eight years and based on clinical neurological assessment and EEG analysis we have divided the patients into three groups:

Group I with three patients showed essentially no change in the first year after surgery. From the second postoperative year there was aggravation of neurological deficit by two points and slight decrease of Alpha-activity. One patient died five years after operation as a result of myocardial infarction (Figure 3).

Group II (Figure 4) with nine patients showed no essential change over an eight year period apart from a slight postoperative increase of Theta- and Delta-activities.

Group III (Figure 5) with 21 patients showed significant improvement of neurological function by 5 points during the first postoperative year. This correlates with an increase of Alpha-activity by 15 points. This improvement was maintained over the 8 year observation period. One patient died in the sixth postoperative year due to myocardial infarction and a second patient died as a result of stroke involving the side opposite to that of surgery.

DISCUSSION AND CONCLUSION

The long term observation after bypass operation of thirty-three selected patients in chronic poststroke stage with fixed moderate neurological deficit showed that in two thirds of these patients there was a definite improvement of clinical neurological status and EEG findings within the first postoperative year and that this improvement was maintained. In one third there was either no improvement or slight deterioration after the second postoperative year. In conclusion it can be stated that EEG is a reliable and useful method for follow-up of patients after bypass operation for the chronic poststroke stage and that it correlates well with clinical neurological findings². In addition the clinical course of properly selected patients after bypass operation is better than that of similar patients treated conservatively, according to Framingham study, the 5 years survival rate of sixty-nine percent in stroke

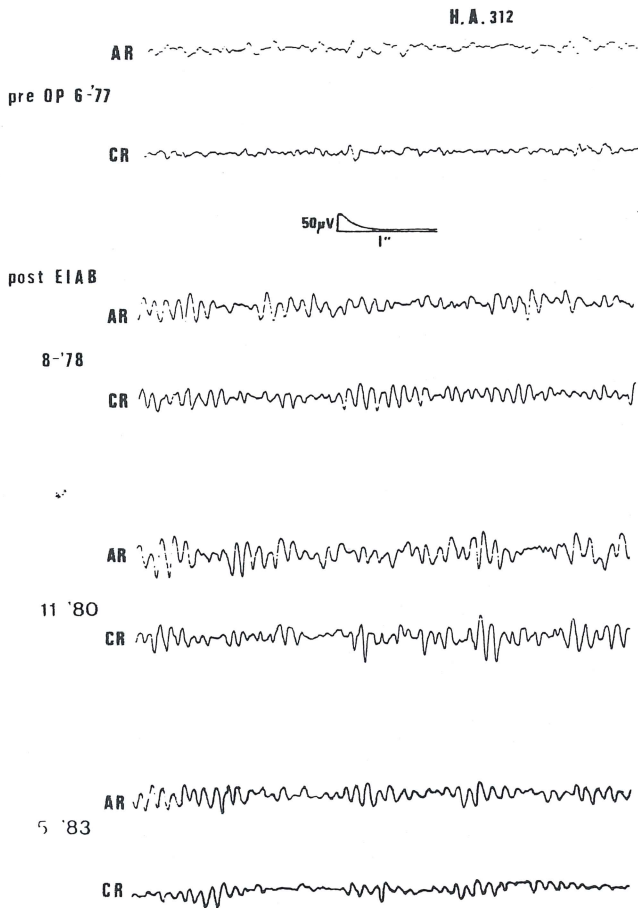


Figure 2. Follow-up original EEG of the affected (AR) and contra-lateral region (CR) of the patient with right internal carotid artery occlusion undergoing extra-intracranial arterial bypass (EIAB) operation.

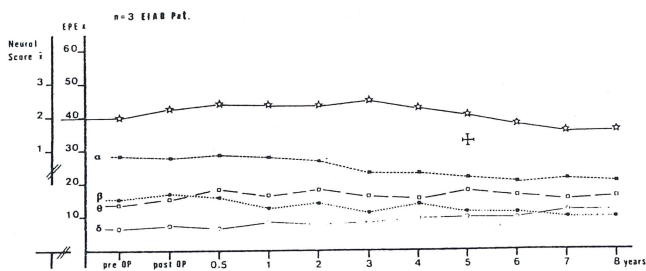


Figure 3. Neurological (star) and EEG analytical follow-up mean values of three patients (group I) undergoing extra-intracranial arterial bypass (EIAB) operation.

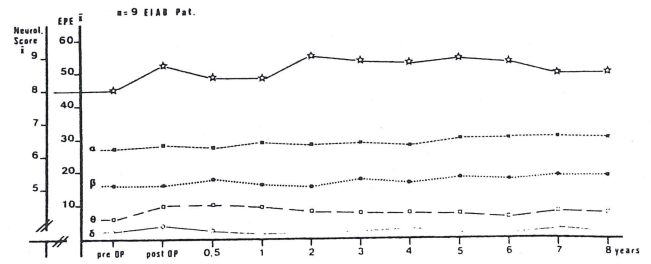


Figure 4. Neurological (star) and EEG analytical follow-up mean values of 9 patients (group II) undergoing extra-intracranial arterial bypass (EIAB) operation.

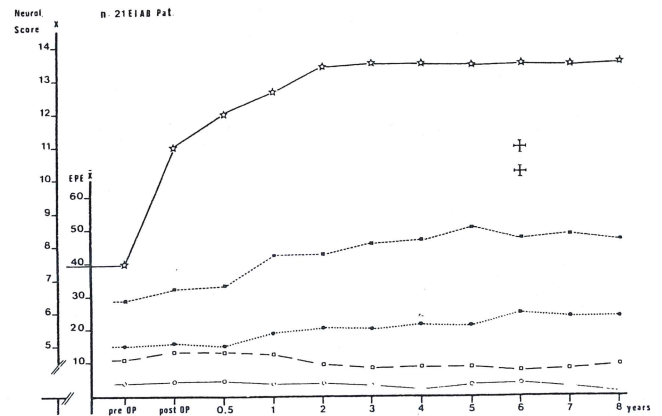


Figure 5. Neurological (star) and EEG analytical follow-up mean values of 21 patients (group III) undergoing extra-intracranial arterial bypass (EIAB) operation.

patients as a natural course is very unfavourable³. Most authors agree, that spontaneous recovery of neurological deficit is rarely observed in the chronic poststroke stage beyond the third month^{4,5}.

REFERENCES

1. Wassmann, H. Quantitative Indikatoren des hirnelektrischen Wirkungsverlaufes bei hyperbarer Oxygenierung. *Z. EEG-EMG* 1980, **11**, 97-101.
2. Holbach, K.H., H. Wassmann and Sanchez, F. EEG analysis for evaluating chronic cerebral ischaemia treated by hyperbaric oxygenation and microsurgery. *J. Neurol.* 1978, **219**, 227-240.
3. Sacco, R.L., Wolf, P.A., Kannel, W.B., and McNamara, P.M. Survival and Recurrence following stroke. The Framingham study. *Stroke*, 1982, **13**, 290-295.
4. Newman, M. The process of recovery after hemiplegia. *Stroke* 1972, **3**, 702-710.
5. Skilbeck, C.E., Wade, D.T., Hewer, R.L. and Wood, V.A. Recovery after stroke. *J. Neurol. Neurosurg. Psychiatry.* 1983, **46**, 5-8.