

# Posthemiplegic Shoulder-Hand Syndrome, with Special Reference to Related Cerebral Localization

FUMIO ETO, MD, MASAKI YOSHIKAWA, MD\*, SATOSHI UEDA, MD and SHUNSAKU  
HIRAI, MD

*Department of Geriatrics, Faculty of Medicine, University of Tokyo, Tokyo, Japan*

**ABSTRACT:** Seven autopsy cases of shoulder-hand syndrome following hemiplegia were studied with regard to cerebral localization. One of them showed an isolated brain lesion in the premotor area due to a metastasis from malignant melanoma. Four other cases with cerebral infarction and one with glioblastoma multiforme showed massive brain lesions involving the frontal and parietal lobe cortex in the area supplied by the middle cerebral artery. The seventh case showed a hemorrhagic cerebral lesion in the lentiform nucleus. The most common overlap area in 6 of the 7 cases was located in the premotor region including the anterior part of the motor region. The shoulder-hand syndrome following hemiplegia always develops on the side contralateral to the brain lesion which might cause a unilateral longstanding autonomic dysfunction. As corroborated in a review of the relevant literature, a lesion in the premotor area appears chiefly responsible for the primary mechanism of the shoulder-hand syndrome in post-stroke hemiplegia.

The shoulder-hand syndrome, a persistent painful shoulder disability with homolateral pain and swelling of the hand, is not a rare complication in patients with hemiplegia and often presents a serious barrier to successful stroke rehabilitation because of discouraging the patients. This syndrome also occurs in many other diseases such as myocardial infarction, trauma, or cervical spondylosis (1,2). However, the exact pathomechanism is still unknown. In hemiplegic patients, the syndrome invariably is restricted to the paralyzed side (3,4). This evidence suggests the pathogenetic importance of a central-nervous-system lesion causing the somatic impairment.

In the past six years, from 1972 to 1977, we observed 7 autopsy cases of hemiplegia with shoulder-hand syndrome. The patients had been admitted to the University of Tokyo Hospital or an affiliated hospital. Their clinical and postmortem records were available in determining the cerebral localization of this syndrome as one of unilateral

longstanding autonomic dysfunction following hemiplegia. The 7 cases are summarized in this article.

## CASE REPORTS

*Patient #1.* A 72-year-old man complained of insidious weakness in the left upper and lower extremities for several weeks. On the day of admission, physical examination showed moderate weakness in the left extremities, with brisker tendon reflexes and a Babinski sign. There was also dark pigmentation on the tip of the right third finger. After admission a series of investigations revealed a malignant melanoma of the right third finger with metastases to the lymph nodes in the right axillary region. Cerebral angiography showed a typical tumor stain in the right frontoparietal area. About two months after admission the patient complained of severe pain in the left shoulder with a swollen hand and fingers and progressive loss of the range of motion. Fever, hypoproteinemia, and severe pneumonia developed in succession. Eight months after admission he died following recurrent episodes of generalized convulsions.

\* Address for correspondence: Masaki Yoshikawa, MD, Department of Geriatrics, University of Tokyo Hospital, 7-3-1 Hongo, Bunkyo-ku, Tokyo, 113, Japan.

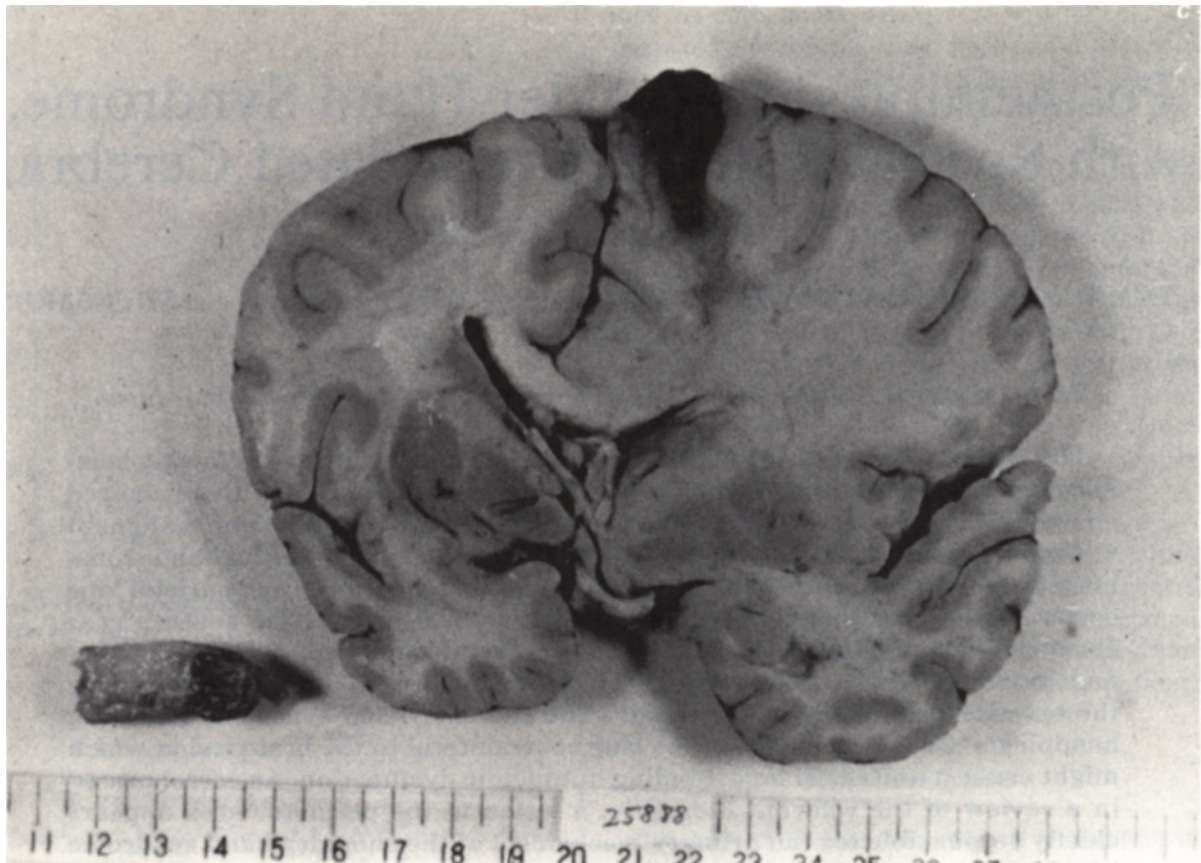


Fig. 1. (Patient #1.) Coronal section at level of the infundibulum showing an isolated lesion in the right frontal-lobe cortex due to metastasis from malignant melanoma originating in right third finger (separate tissue at lower left).

Postmortem examination showed a wedge-shaped necrotizing lesion surrounded by an infiltration of tumor cells in the right frontal lobe, and pronounced edema in the right cerebral hemisphere (Fig. 1). The cerebral arteries were slightly atherosclerotic. There was no visible infarct in the brain except the tumor lesion. This lesion was identified as a metastasis of the malignant melanoma histologically, and was localized for the most part in the premotor region (Fig. 2).

**Patient #2.** A 56-year-old woman noticed weakness of the left hand two months before development of the shoulder-hand syndrome in the left upper extremity and a slowly increasing weakness of the left arm and leg. She was admitted to the Department of Neurosurgery with the presumptive diagnosis of intracranial tumor. A craniotomy and biopsy showed that she had an inoperable tumor, glioblastoma multiforme, in the right cerebral hemisphere. Despite treatment consisting of irradiation and chemotherapy, the patient died six months after the first appearance of the left hemiparesis. At autopsy, the brain weighed 1,340 gm and showed moderate swelling of the right hemi-

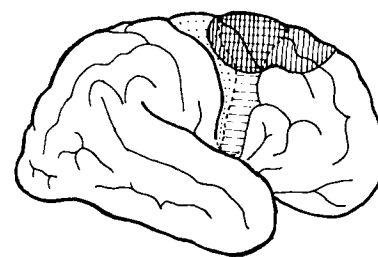


Fig. 2. (Patient #1.) Diagram of lateral surface of the right cerebral hemisphere illustrating location of the tumor lesion.

sphere. Coronal sections of the cerebrum demonstrated a widespread necrotizing lesion extending from the deep parietal region to the frontoparietal cortex, with a completely compressed lateral ventricle in the right hemisphere. This lesion included the premotor cortex. There was no arteriosclerotic ischemic lesion in the brain.

**Patient #3.** A 41-year-old man with mitral valve

stenosis and atrial fibrillation was found in coma. Two days later he regained partial consciousness and showed complete hemiplegia on the right side with expressive aphasia. About two months later he improved to the extent that he was ambulant in parallel bars. At that time the shoulder-hand syndrome developed. Three months later he died of severe gastrointestinal hemorrhage with generalized purpura. Postmortem examination showed a massive infarct in the field supplied by the left middle cerebral artery in the frontoparietal lobe, involving the premotor cortex. The internal carotid artery showed a small finger-tip-sized embolus just before the bifurcation of the anterior and middle cerebral arteries; it was partially recanalized. There were two other old infarctions

(rice-grain size) in the internal capsule and the caudate nucleus in the right cerebral hemisphere (Fig. 3).

*Patient #4.* A hypertensive woman, aged 77, died of pneumonia and congestive cardiac failure four months after development of moderate weakness of the left arm and leg. The shoulder-hand syndrome had been present on the paralyzed side for two months before her death. At autopsy, the brain weighed 1,000 gm and showed moderate cortical atrophy. There was a massive infarct in the area supplied by the right middle cerebral artery, from the frontal lobe to the occipital. In the left cerebral hemisphere, no localized lesion such as a infarct was found (Fig. 3).

*Patient #5.* A hypertensive woman, aged 75,

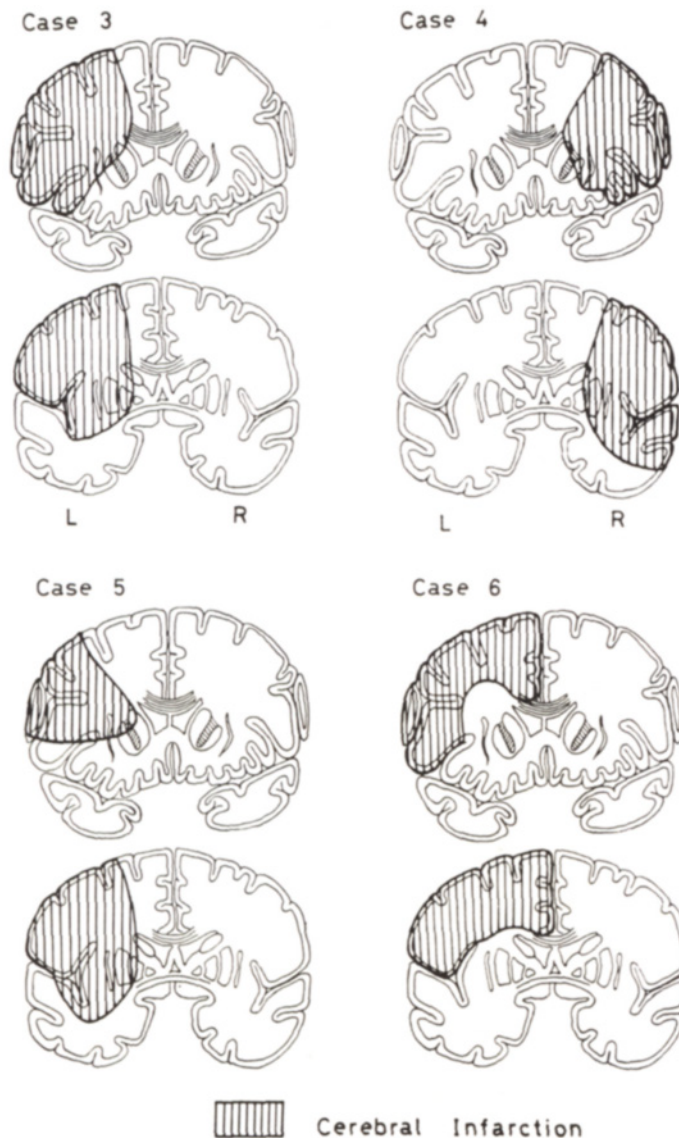


Fig. 3. (Patients #3, 4, 5 and 6.) Coronal section diagrams at level of rostrum of the corpus callosum and at level of the infundibulum illustrating each lesion in 4 cases of cerebral infarction.

had moderate weakness of the right arm and leg with moderate expressive aphasia. In another month, the shoulder-hand syndrome developed. She died five months later of pneumonia. Post-mortem examination disclosed moderate cortical atrophy of the brain and a massive infarct in the area supplied by the left middle cerebral artery, from the frontal lobe to the parietal (Fig. 3).

*Patient #6.* A 78-year-old woman had a cerebral thrombosis with hemiplegia on the right side, and global aphasia. One week later, pronounced swelling of the right hand developed. Three months thereafter she refused passive exercise of the paralyzed arm, as if in pain, and the range of motion in both the shoulder and wrist was gradually lost. She died four months later of pneumonia. Post-mortem examination disclosed a massive infarct in the areas supplied by the left anterior and middle cerebral arteries, involving the cerebral cortex and several small softenings (up to the size of a rice grain) in the head of the caudate nucleus and the putamen in the right cerebral hemisphere (Fig. 3).

*Patient #7.* A 54-year-old man who had undergone gastrectomy for carcinoma of the stomach, suddenly experienced moderate hemiplegia on the right side and mild expressive aphasia. One month later he died from carcinomatosis of the residual stomach tissue and metastases to the liver. Post-mortem examination disclosed a hemorrhagic cerebral lesion located in the lentiform nucleus, with destruction of the surrounding area involving the internal and external capsules in the left cerebral hemisphere.

## DISCUSSION

The shoulder-hand syndrome is a clinical entity described by Steinbrocker et al as a complete form of reflex dystrophy of the upper extremity (1). Although this syndrome has been frequently reported as an interesting complication of myocardial infarction (2), it occurs also in cases of trauma, herpes zoster, cervical spondylosis and hemiplegia. Hemiplegic patients abound in any stroke-care unit. Our previous investigation (3) showed that this syndrome appears in 21.0 per cent of post-stroke hemiplegic patients above 40 years of age, and there is no significant difference in the incidence between right and left hemiplegia. According to Steinbrocker and Argyros (4), the clinical course of this syndrome is divided into three stages. The first stage is characterized by pain and tenderness in the shoulder and hand, with loss of

range of motion, puffy swelling of the arm and hand, and other symptoms of vasomotor changes. These signs usually appear between the second and fourth months after onset of the hemiplegia (3, 5). Because such a painful impairment often interferes with the stroke rehabilitation program by discouraging the patients, early recognition and proper management are essential (6). In recent years, clinical neurologic examinations such as computerized cranial tomography and cerebral angiography have clearly determined the location of the intracranial lesion. These measures could predict the shoulder-hand syndrome at an early stage of stroke rehabilitation, if the appearance of the syndrome is dependent upon a certain peculiar localization in the brain.

The puffy swelling, one of the characteristic signs, results from a vasomotor disturbance. Sympathetic block of the stellate or upper thoracic ganglia is known to relieve the pain, which is sometimes similar to causalgia (6-8). This syndrome may be identified by the manifestation of the longstanding autonomic-nervous-system disturbance caused by brain damage. A large number of communications based on experimental and clinical observations have been published on the subject of autonomic disorders in cerebral lesions, particularly of the frontal lobe cortex (9,10).

Patient #1 is of interest because of the location of the lesion. The isolated lesion in the premotor area in this case may have been responsible for the shoulder-hand syndrome. On the other hand, the metastatic lesion may gradually invade the surrounding areas and be followed by pronounced edema in the affected cerebral hemisphere. The most common overlap area in 6 of the 7 autopsy cases was in the premotor region. The pathologic changes in the patient with hemorrhages in the putamen also involved the corticospinal tract from the premotor cortex at the internal capsule, almost completely. Vaernet (11) reported 2 patients with this syndrome among cases of meningioma affecting the premotor region. This area seems important in pathogenesis.

The pathomechanism of the shoulder-hand syndrome, is one of reflex sympathetic dystrophy and is often represented as a vicious circle of reflexes under the modifying influence of the central nervous system and environmental factors (1,2,7). The vasomotor changes and pain may be related to the dysfunction of the autonomic nervous system. This system is concerned with the regulation of the somatic functions in response to changes in internal or external environment, and when dam-

aged can disturb homeostasis. The autonomic response usually occurs over the whole body or in both sides, but the shoulder-hand syndrome always develops in the side contralateral to the brain lesion.

There are other interesting reports of unilateral autonomic manifestations in cases of brain damage. Bucy (9) described a case of sudden right hemiplegia with marked signs of vasoconstriction involving the right side of the body, in paroxysms. Kennard's report on contralateral vasodilation following destruction of the premotor area is more impressive (10). In this syndrome, peripheral blood flow is increased in the affected hand, probably through vasodilation (3,7). Conclusively, our cases as well as those in the literature indicate that the premotor area should be recognized as the chief pathologic site in relation to the shoulder-hand syndrome following hemiplegia.

The shoulder-hand syndrome, however, occurs also in various diseases without hemiplegia. The age of the patients in any of the causative disorders is almost always over 40 years (1-3). In the fifth and sixth age decades, so-called "frozen shoulder" is a common disability, similar to that in the shoulder-hand syndrome. It is considered primarily as a rotator cuff disorder closely related to the aging process, and appears much later than a few weeks after onset of the primary disease.

Apparently, the development of this disorder requires other predisposing conditions such as degenerative changes in the shoulder. In contrast, the primary mechanism of the post-stroke, shoulder-hand syndrome is related to a lesion in the cerebral premotor area.

## REFERENCES

1. Steinbrocker O, Spitzer N and Friedman HH: Shoulder-hand syndrome in reflex dystrophy of upper extremity, *Ann Int Med* 29: 22, 1948.
2. Rosen PS and Graham W: The shoulder-hand syndrome, *Canad MAJ* 77: 86, 1957.
3. Eto F, Yoshikawa M, Hirai S et al: Shoulder-hand syndrome as a complication of hemiplegia, *Jap J Geriat* 12: 245, 1975.
4. Steinbrocker O and Argyros TG: Shoulder-hand syndrome: present status as a diagnostic and therapeutic entity, *Med Clin N America* 42: 1533, 1958.
5. Davis SW, Petrillo CR, Eichberg RD et al: Shoulder-hand syndrome in a hemiplegic population: a 5-year retrospective study, *Arch Phys Med Rehab* 58: 353, 1977.
6. Moskowitz E, Bishop HF, Pe H et al: Posthemiplegic reflex sympathetic dystrophy, *JAMA* 167: 836, 1958.
7. De Takats G: Sympathetic reflex dystrophy, *Med Clin N America* 49: 117, 1965.
8. Swan DM: Shoulder-hand syndrome following hemiplegia, *Neurology* 4: 480, 1954.
9. Bucy PC: Vasomotor changes associated with paralysis of cerebral origin, *Arch Neurol Psychiat* 33: 30, 1935.
10. Kennard MA: Vasomotor disturbances resulting from cortical lesions, *Arch Neurol Psychiat* 33: 537, 1935.
11. Vaernet K: Two cases of shoulder-hand syndrome in meningioma affecting the premotor region, *Acta Psychiat Neurol Scandinav* 27: 201, 1952.