

## ***A Complete Form of Unilateral Retinocephalic Vascular Malformations: A Case Report***

Akinori KONDO, Junichiro ISHIKAWA, Junya HANAKITA  
and Tsunemaro KOYAMA

*Department of Neurosurgery, Fukui Red Cross Hospital,  
Fukui, Japan*

### **Summary**

A complete form of rare vascular malformation named "unilateral retinocephalic vascular malformation" in a 25-year-old woman with a clinical history of more than 15 years is presented. This case was also associated with other cerebral vascular anomalies such as a saccular aneurysm and an azygos pericallosal artery. The difference between usual arteriovenous malformation and this extensive vascular malformations in terms of the incidence of intracranial hemorrhage and also epileptic seizures is briefly commented upon.

**Key words:** Extensive vascular malformation, aneurysm, azygos artery

### **Introduction**

An extensive arteriovenous malformation involving the face, retina and brain all on the ipsilateral side was named "unilateral retinocephalic vascular malformations" by Théron et al. in 1974<sup>4)</sup> after reviewing and analyzing 22 cases in the foregoing literature and of their own three cases. We present a typical case of this vascular malformation which combines other cerebral vascular anomalies.

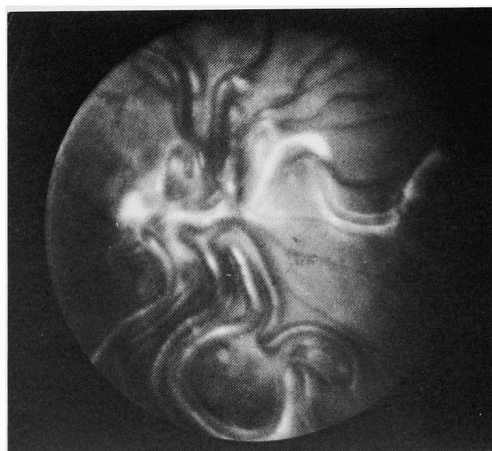
### **Case Report**

A 25-year-old woman was referred to us because of disturbed consciousness and left hemiparesis. She suddenly started complaining of severe throbbing headache in the right frontal region after taking a bath 2 days prior to her admission and became semicomatose thereafter for several hours.

### **Examinations**

She was slightly lethargic but responsive to verbal commands upon admission. She was short and slender with slight mental retardation. She displayed remarkably dilated cutaneous venous channels on her right forehead and

temple with small cutaneous telangiectasia over the same area, but they did not extend beyond the midline. She exhibited a mild exophthalmos and also moderately dilated bulbar conjunctival vessels of the right eye. Bruit was loudly heard over all the parts of her right frontal and temporal areas. Her right fundus photograph demonstrated typical arteriovenous malformation of the retina which completely obscured the optic disc (Fig. 1) and vision of her right eye was almost lost. She



**Fig. 1** Fundus photograph shows arteriovenous malformations of the right retina which obscure the optic disc.

showed gaze-fixed nystagmus to the right and upward. Dysarthria was evident and deglutition was moderately disturbed. She showed spastic left hemiparesis with positive Babinski sign on the left. All sensations were reduced on the left side of the body except for the face where they were impaired on the right side. Lumbar spinal tap revealed watery clear CSF with no pleocytosis and normal Queckenstedt's sign. Approximately 5 days after admission, she regained clear consciousness and dysarthria slightly improved, but deglutition was still moderately disturbed. About 2 weeks after admission, she was able to sit on the bed for a while and dysarthria improved greatly. Almost 1 month after admission, she was able to walk with an aid. When she was discharged from the hospital after 5 weeks stay, she was able to walk by herself although her gait was still clumsy and her left spastic hemiparesis, especially of her left thumb and fingers, was still present.

#### Past History

She first noticed right exophthalmos with bulbar conjunctival hyperemia and cutaneous venous engorgement in the area of her right forehead at approximately 9 years of age. At age 10 years, she underwent right common carotid ligation in the neck in another hospital and the surgery was effective to reduce her symptoms for a while. Since about 14 years of age, however, left spastic hemiparesis developed gradually, right exophthalmos with venous engorgement on the right forehead recurred and the right visual acuity and her intelligence deteriorated. She neither experienced epileptic seizures nor cerebral ischemic attacks. Her familial history was non-contributory.

#### Laboratory Findings

Hematocrit was 37%, hemoglobin 12.2 gm% and red blood cell count was 3.8 million per cu mm. Her hypothalamo-hypophyseal hormonal function and other routine laboratory tests were all in the normal range. Electroencephalogram displayed slight but diffuse cerebral dysfunction. Electrocardiogram was normal and she did not show cardiomegaly on plain chest film.

#### Radiology

Roentgenogram of the skull showed dilated deep vascular grooves on the right frontoparietal area. Right optic canal was not enlarged.

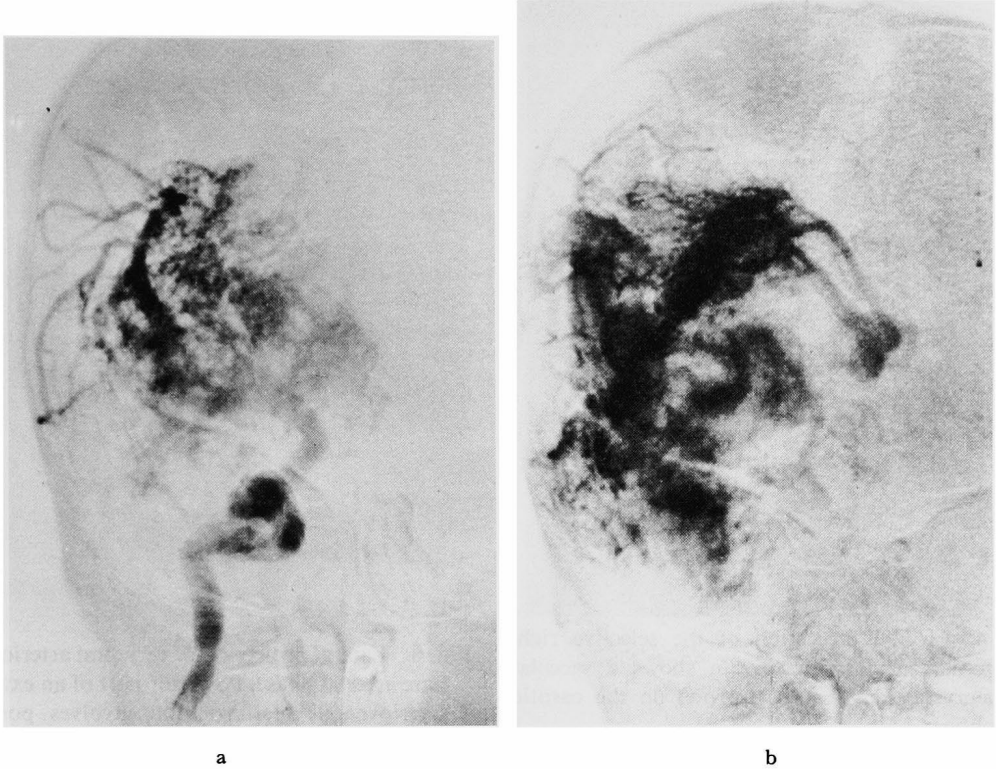
A selective internal carotid arteriogram was performed on the right by direct percutaneous puncture distal to the previous carotid ligation. It showed a remarkably dilated right internal carotid artery and a trunk of the middle cerebral artery. Extensive arteriovenous malformation involving the retina, optic pathway, sellar region, hypothalamus, entire basal ganglia and thalamic region were visualized and this was mainly fed by dilated lenticulostriate arteries and enormously developed and dilated branches from the insular portion of the right middle cerebral artery. This arteriovenous malformation was drained mostly by the internal cerebral vein, right thalamostriate vein, basal vein, middle cerebral vein, cavernous sinus, vein in the frontal base, ascending frontal and parietal veins which were all dilated extraordinarily (Fig. 2a, b) (Fig. 3a, b).

A saccular aneurysm-like shadow was seen on the right carotid siphon (Fig. 4).

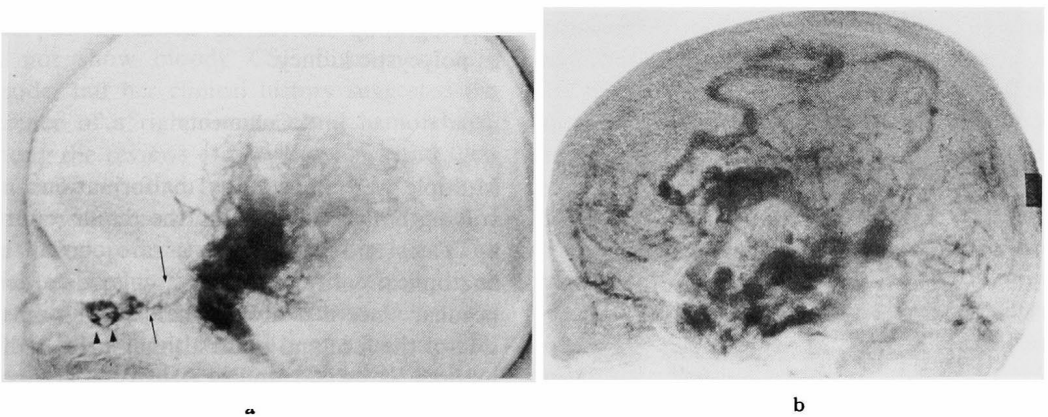
The anterior cerebral artery was not filled from this side. Left common carotid arteriogram revealed moderately dilated internal carotid artery and also an azygos pericallosal artery. The arteriovenous malformation was also supplied from the left carotid artery (Fig. 5).

Vertebral arteriogram demonstrated megadolicho-basilar artery. The dilated right posterior cerebral artery and thalamoperforators sent off many feeders to the conglomerated arteriovenous malformation occupying the posterior portion of the thalamus and the upper brain stem (Fig. 6).

Brachial arteriogram revealed a dilated innominate artery and the previously occluded common carotid artery. The right inferior thyroid artery, the ascending cervical arteries and the cervical profund artery were all dilated and tortuous and they made an abnormal vascular network in the mandibular and maxillary regions (Fig. 7). The left inferior thyroid artery and possibly the right superior thyroid artery, both dilated, were making a



**Fig. 2** Frontal projection of the selective right internal carotid arteriogram. a: Late arterial phase. A huge cerebral arteriovenous malformation mainly fed by dilated lenticulostriate arteries and branches from the insular portion of the middle cerebral artery, occupying basal ganglia and thalamic region. b: Venous phase. Dilated thalamostriate veins and numerous deep draining veins.



**Fig. 3** Lateral projection of the selective right internal carotid arteriogram. a: Arterial phase. An extensive vascular malformation involves the retinal region (arrow heads), optic pathway (arrows), sellar region and thalamus. b: Venous phase. Extraordinarily dilated numerous draining veins: internal cerebral vein, basal vein, middle cerebral vein, ascending frontal and parietal veins and so on.

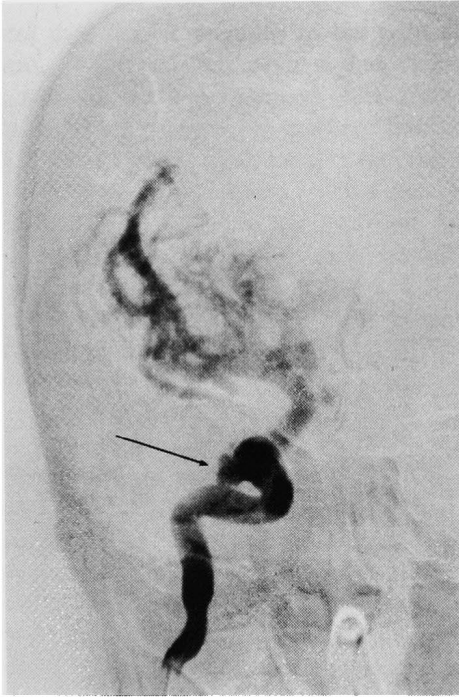


Fig. 4 Frontal projection of the selective right internal carotid arteriogram shows a saccular aneurysm like shadow (arrow) on the carotid siphon.

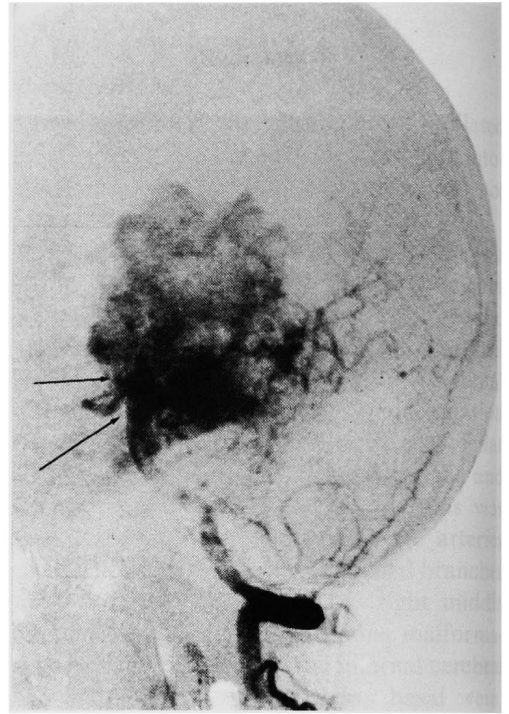


Fig. 6 Lateral projection of vertebral arteriogram. Late arterial phase. Posterior part of an extensive arteriovenous malformation involves posterior thalamic region and brain stem, but not the posterior fossa. Megadolichobasilar artery is also noted. (arrows)

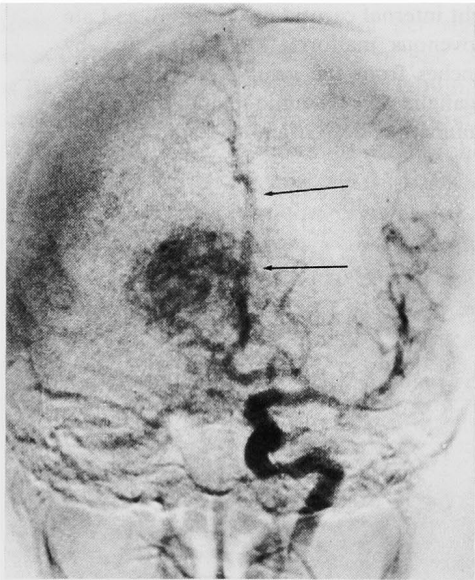


Fig. 5 Frontal projection of the selective left internal carotid arteriogram. Arterial phase. A part of arteriovenous malformation of the right hemisphere is supplied from the left side. No abnormal vascular malformation on the left hemisphere. An unpaired pericallosal artery is visualized. (arrows)

crossing anastomotic channel in the anterior portion of the neck through which the right carotid artery was visualized distal to the occlusion (Fig. 8).

Pyelogram on both sides taken during carotid arteriography showed no abnormalities, such as polycystic kidney.

#### Comments

Multiple arteriovenous malformations involving both the brain and the retina reported by Yates and Paine<sup>5)</sup> are a rare clinical and anatomical entity and this vascular disorder is peculiar since it is always mainly lying on one side of the face and brain although the malformation is wide and extensive. The case presented here shows a complete form of this extensive vascular abnormality which involved the retina, optic pathway, thalamus, brain stem and also the face and mandibular region all on the right side and also had mental dullness.<sup>1,6)</sup> She suddenly lost consciousness for

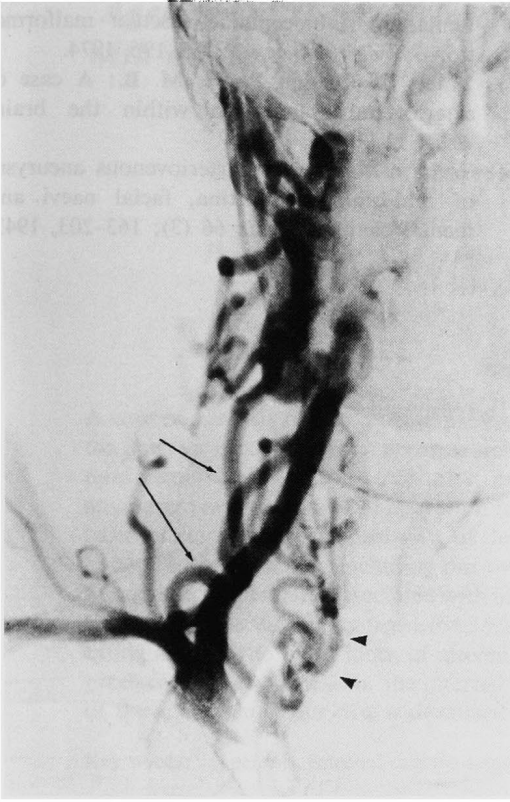

Fig. 7 Frontal projection. Right brachial arteriogram shows dilated vertebral artery and also dilated and tortuous inferior thyroid artery (arrow heads) and ascending cervical arteries (arrows) which make abnormal vascular network in the mandibular and maxillar regions.

several hours and revealed signs of increased intracranial pressure thereafter. Her spinal tap did not show bloody CSF throughout this episode, but her clinical history suggested the presence of a right intracerebral hemorrhage. Among the reviews of previous cases and their own cases reported by Théron et al.,<sup>4)</sup> 2 cases developed subarachnoid hemorrhage and 3 cases developed intracerebral hemorrhage. The incidences of intracranial hemorrhage from extensive arteriovenous malformations are much less frequent than that of usual cerebral arteriovenous malformation according to Pool and Potts who described that intracranial hemorrhage occurred in 40–60% of the total cases.<sup>3)</sup> The patient reported here did not experience epileptic seizures, and only one case of petit mal attack was reported in the summarizing review of 25 cases by Théron et al.<sup>4)</sup>

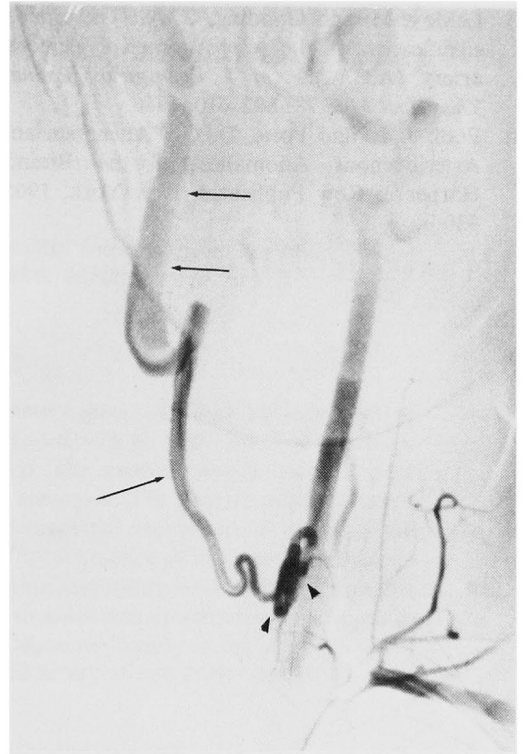


Fig. 8 Frontal projection of the left subclavian arteriogram. Left inferior thyroid artery (arrow heads) and possibly the right superior thyroid artery (lower arrow) make a crossing anastomotic channel which supplies distal portions of the right internal carotid artery (upper arrows).

This incidence of epilepsy is also extraordinarily rare when compared to the results of 30–50% incidence of epileptic seizures in usual arteriovenous malformation.<sup>3)</sup>

Théron et al.<sup>4)</sup> did not mention other vascular anomalies concomitant with “unilateral retinocephalic vascular malformations” in their own series or in their summarizing review of other cases. Since these extensive arteriovenous malformations arise from multiple developmental anomalies, they likely combined other types of vascular anomalies, such as a saccular aneurysm and azygos artery, which were seen in our case.<sup>2)</sup>

#### References

- 1) Brown, D. G., Hilal, S. K. and Tenner, M. S.: Wyburn-Mason Syndrome. Report of two cases without retinal involvement. *Arch Neurol*

- 28: 67-68, 1973.
- 2) LeMay, M. and Gooding, C. A.: The clinical significance of the azygos anterior cerebral artery (A.C.A.). *Am J Roentgenol Radium Ther Nucl Med* 98: 602-610, 1966.
  - 3) Pool, J. L. and Potts, D. G.: "Aneurysm and Arteriovenous Anomalies of the Brain." Harper & Row Publishers, New York, 1965, 330 p.
  - 4) Théron, J., Newton, T. H. and Hoyt, W. F.: Unilateral retinocephalic vascular malformations. *Neuroradiology* 7: 185-196, 1974.
  - 5) Yates, A. G. and Paine, M. B.: A case of arteriovenous aneurysm within the brain. *Brain* 53: 38-46, 1930.
  - 6) Wyburn-Mason, R.: Arteriovenous aneurysm of mid-brain and retina, facial naevi and mental changes. *Brain* 66 (3): 163-203, 1943.