

The Determination of Speech Organization in a Patient with an Arteriovenous Malformation

Richard A. Close, M.D., Anne Marie O'Keefe, M.A., and William A. Buchheit, M.D.

Department of Neurosurgery (R.A.C., W.A.B.) and Department of Psychiatry (A.M.O.), Temple University Hospital, Philadelphia, Pennsylvania 19140

A case is reported of an arteriovenous malformation in the left motor speech area which was successfully excised without aphasia in a right-handed man. Preoperative sodium amobarbital carotid infusion testing demonstrated that the patient had right hemisphere dominance for speech. A review of the literature suggests that this is not an uncommon occurrence in individuals with congenital lesions of the left cerebral hemisphere. Lateralization of speech dominance should be established through definitive testing in these cases, especially if surgical removal of the malformation is contemplated.

Key words: Arteriovenous malformation, Aphasia, Carotid infusion test, Dominance, Handedness

In evaluating the surgical risks for patients with intracranial arteriovenous malformations, the surgeon must be absolutely certain of the relationship between the locus of the lesion and the functional motor speech areas.

Kunc has reported 18 selected cases of the extirpation of arteriovenous malformations from speech and motor-sensory areas with virtually no morbidity (6). He feels that his success was a result of microsurgical techniques and the fact that the brain tissue involved with the arteriovenous malformations was (and usually is) hypoplastic and nonviable.

Although symptoms of aphasia are common with arteriovenous malformations of the left motor speech area, their incidence is much lower than would be expected by predictions based on the normal functional development and organization of the cerebral hemispheres. Among Kunc's patients, 13 malformations involved the left motor and sensory speech cortex, but only six of these patients were aphasic preoperatively. The review by Olivecrona and Riives of 43 cases of arteriovenous malformation included 14 localized in the left middle cerebral artery distribution; only three of these patients presented with any symptoms of aphasia (11).

Milner maintains that early insult to critical left hemisphere zones (Broca's area and superior speech cortex) due to injury or congenital lesion (e.g., arteriovenous malformation) can result in right hemisphere dominance, or more rarely, bilateral representation of speech functions (10). Furthermore, individuals with arteriovenous malformations or other congenital lesions should not be presumed to have typical hemispheric organization for handedness or nonverbal abilities (1, 9, 10, 16).

A recent report demonstrated right hemisphere language dominance in a left-handed individual with a left frontoparietotemporal arteriovenous malformation (18). We are reporting a case of a right-handed individual with an arteriovenous malformation of the left motor speech area and proven right hemisphere speech dominance.

CASE REPORT

A 28-year-old right-handed Negro male was admitted to Temple University Hospital on January 31, 1977 because of seizures. The seizures, characterized by automatisms and preceded by an aura of epigastric discomfort, dated back to childhood (age 7). His developmental milestones and childhood disease history were unremarkable. There was no history of auditory, gustatory, or visual hallucinations. There had been no grand mal seizures nor speech disturbance. His seizures, occurring as often as twice a week since the age of 22, were under poor control with carbamazepine.

An angiogram done 2 years prior to this admission demonstrated a large arteriovenous malformation in the left posterior frontal lobe. He had originally refused operation, fearing a permanent linguistic disability. There was no history of intracerebral or subarachnoid hemorrhage. Physical examination was normal. Another cerebral angiogram at the time of present admission (Fig. 1) demonstrated the lesion to be unchanged.

Neuropsychological evaluation with a lateral dominance test showed him to be strongly right-handed, right-eyed, and right-footed. An aphasia screening test proved normal, but his over-all performance pattern on a series of tests, including several components of the Halstead-Reitan battery (5, 13), was compatible with minimal, chronic, and diffuse organic brain dysfunction.

Sodium amobarbital (Amytal sodium, Eli Lilly & Co., Indianapolis, Indiana) infusion tests, done first in the left internal carotid artery, and, several days later, in the right, showed ipsilateral EEG slowing and contralateral hemiplegia, but produced aphasia only with the right-sided injection. The results of these tests definitively established right hemisphere dominance for speech.

The lesion was resected (Fig. 2). Postoperatively, he had no aphasia. He had a mild right hemiparesis which rapidly improved. Neuropsychological re-evaluation 5 weeks after discharge showed minimal reduction in grip strength, some slowing of motor speed, and reduced tactile sensitivity in his right hand, but no significant changes in intellectual functioning or cognitive abilities.

DISCUSSION

Among normal right-handers, the incidence of left hemisphere dominance for speech has been reported to be as high as 99.7%, based on a retrospective clinical study of acquired disease to the language area of the brain (7). Rossi and Rosadini, using the carotid Amytal infusion test, reported a 98.6% incidence of left hemisphere speech dominance among dextrals with normal angiograms (14). Milner's study, although based on a clinical population and undoubtedly including individuals with congenital disorders, still reports an incidence of 92% left hemisphere speech dominance for right-handers (10). Right hemisphere dominance for speech is so rare in dextrals that it should be considered to be due either to latent left handedness (e.g., the shifted sinistral) or to a congenital or early left hemisphere lesion (1-3, 16).

The sodium Amytal carotid infusion test, developed by Wada, has been used extensively in laboratory and experimental settings with relative safety (1, 4, 8, 10, 12, 15, 17, 18). Effective utilization of the test must demonstrate ipsilateral slowing of the EEG and contralateral motor disturbance following intracarotid injection of 200 mg of 10% sodium Amytal. Aphasia will follow injection of the language domi-

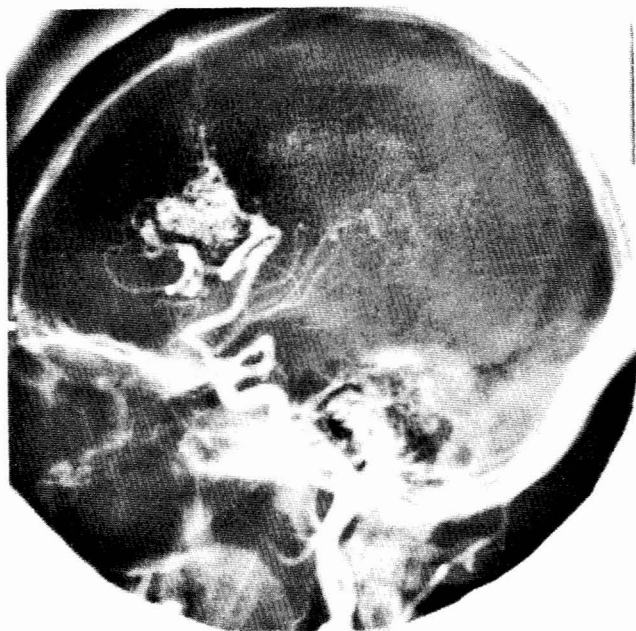

FIG. 1. Lateral projection, left carotid arteriogram demonstrating a posterior frontal arteriovenous malformation, January, 1977.

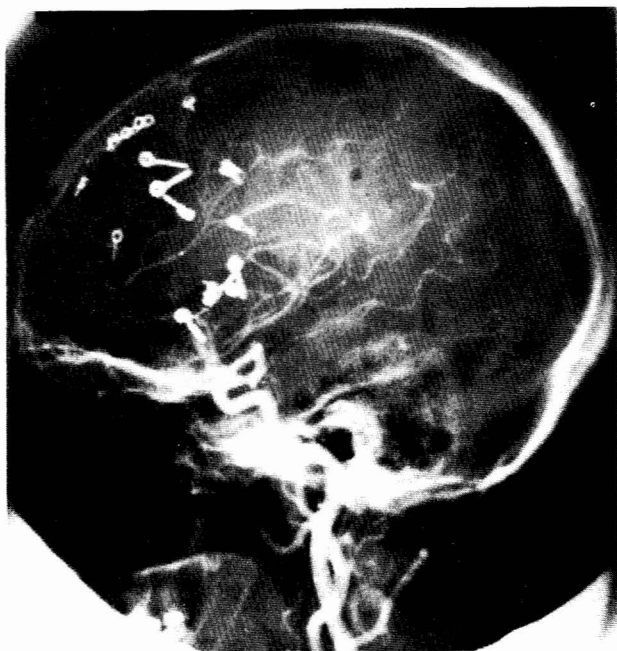


FIG. 2. Postoperative left carotid arteriogram demonstrating total removal of the lesion, February, 1977.

nant hemisphere only. Hemidecerebration (4) and delayed hemisphere-specific emotional responses (12, 14) have been reported. No cases have been reported of death or serious disability due to the administration of this test.

CONCLUSIONS

The carotid Amytal infusion test is well known, and the advantages of its application in a case such as this are obvious. We have the impression, however, that this test is not used routinely, although it is easy and safe to perform. We suggest

its application in all individuals (sinistrals and dextrals) with arteriovenous malformations thought to be within the speech area of either hemisphere, so as to more accurately determine the safety of surgical excision.

Individuals with arteriovenous malformations, especially in areas normally considered functionally relevant to language ability, may have developed highly idiosyncratic functional organization of the cerebral hemispheres regardless of handedness (10, 16). In cases of early or congenital lesions, the lateralization should be established as definitively as possible rather than be simply presumed from the patterns revealed in statistics based on normal populations.

ACKNOWLEDGMENTS

The authors thank Mark Kaplan and Howard Edelman for research assistance, Michael Scott, M.D. for his kind critical review, and M. Amy Wischum for preparation of the manuscript.

Received for publication, March 21, 1977; accepted, April 24, 1977.

Reprint requests: Richard A. Close, M.D., Department of Neurosurgery, Temple University Hospital, Philadelphia, Pennsylvania 19140.

REFERENCES

1. Branch, C., Milner, B., and Rasmussen, T. Intracarotid sodium Amytal for the lateralization of cerebral speech dominance. *J. Neurosurg.*, 21:399-405, 1964.
2. Brown, J. W., and Hecaen, H. Lateralization and language representation. *Neurology (Minneapolis)*, 26:183-189, 1976.
3. Ettlenger, G., Jackson, C. V., and Zangwill, O. L. Dysphasia following right temporal lobectomy in a right handed man. *J. Neurol. Neurosurg. Psychiatry*, 18:214-217, 1955.
4. Gilman, S., MacFadyen, D. J., and Denny-Brown, D. Decerebrate phenomena after carotid amobarbital injection. *Arch. Neurol.*, 8:662-675, 1963.
5. Halstead, W. C. *Brain and Intelligence: A Quantitative Study of the Frontal Lobes*. Chicago, Univ. Chicago Press, 1947.
6. Kunc, Z. Surgery of arteriovenous malformations in the speech and motor-sensory regions. *J. Neurosurg.*, 40:293-303, 1974.
7. Levy, J. Psychobiological implications of bilateral asymmetry. In *Hemisphere Function in the Human Brain*, edited by Dimond, S. J., and Beaumont, J. G., New York, Wiley and Sons, 1974.
8. Luessenhop, A. J., Boggs, J. S., LaBorwit, L. J., and Walle, E. L. Cerebral dominance in stutterers determined by Wada testing. *Neurology (Minneapolis)*, 23:1190-1192, 1973.
9. Luria, A. R. *Higher Cortical Functions in Man*. New York, Basic Books, Inc., 1966.
10. Milner, B. Hemisphere specialization: Scope and limits. In *The Neurosciences: 3rd Study Program*, edited by Schmitt, F. O., and Worden, F. C. Cambridge, Mass., MIT Press, 1973.
11. Olivecrona, H., and Riives, J. Arteriovenous aneurysms of the brain: Their diagnosis and treatment. *Arch. Neurol. Psychiatry*, 59:567-602, 1948.
12. Perria, L., Rosadini, G., and Rossi, G. F. Determination of side of cerebral dominance with amobarbital. *Arch. Neurol.*, 4:173-181, 1961.
13. Reitan, R. M., and Davison, L. A. *Clinical Neuropsychology: Current Status and Applications*. New York, Winston, 1974.
14. Rossi, G. F., and Rosadini, G. Experimental analysis of cerebral dominance in man. In *Brain Mechanisms Underlying Speech and Language*, edited by Darley, F. L., and Millikan, C. H. New York, Grune and Stratton, 1967.
15. Wada, J. A new method for the determination of the side of cerebral dominance. A preliminary report on the intracarotid injection of sodium Amytal in man. *Med. Biol. (Tokyo)*, 14:221-222, 1949.
16. Wada, J. A., Clarke, R., and Hamm, A. Cerebral hemispheric asymmetry in humans. *Arch. Neurol.*, 32:239-246, 1975.

17. Wada, J. A., and Rasmussen, T. Intracarotid injection of sodium Amytal for the lateralization of cerebral speech dominance. *J. Neurosurg.*, 17:266-282, 1960.
18. Wertz, R. T., Messert, B., Collins, M., Rosenbek, J. C., and Kao, C. C. Right-hemisphere language dominance in a case of left-hemisphere arteriovenous malformation. *J. Speech Hear. Disord.*, 42:106-112, 1977.

COMMENT

Based on a very exceptional case, the authors make a strong argument for the use of preoperative sodium Amytal carotid infusion (modified Wada) testing of patients with arteriovenous malformations thought to be within language areas in order to more accurately determine the risks of

surgical therapy. Vast experience with this testing technique in the preoperative evaluation of the intractable epilepsies has demonstrated its safety and reliability in the determination of hemispheric laterality for language. There are, however, certain limitations of the intracarotid Amytal test which are more readily overcome with a shorter acting barbiturate, methohexital (Wilder, B. J., Willmore, L. J., and Sybert, G. W., in preparation). The author's case also illustrates the importance of the well known relationship between congenital lesions and idiosyncratic hemispheric language localization.

George W. Sybert, M.D.
Gainesville, Florida