

# Dichotic Listening in Crossed Aphasia

## 'Paradoxical' Ipsilateral Suppression

Gianfranco Denes, MD, Franco Caviezel, MD

• In a 35-year-old right-handed man who had no personal or family history of left-handedness, left hemiparesis and predominantly motor aphasia suddenly developed following cerebrovascular accident. Clinical and laboratory data, including computerized tomographic scan, showed a clearly defined right hemisphere lesion. On dichotic listening test, a clear-cut right ear extinction was present.

(*Arch Neurol* 1981;38:182-185)

Dichotic listening (DL) tests have been, to our knowledge, rarely carried out in right-handed aphasic patients.<sup>1-3</sup> Most of the patients demonstrated an impairment in reporting verbal material presented to the right ear, showing the so-called contralateral ear effect or lesion effect.<sup>4</sup> A consistent minority of patients showed, however, a left ear extinction or "paradoxical ipsilateral ear effect"<sup>2,3,5,6</sup> in DL tests. Whereas the contralateral ear effect has been proved to be a consequence of a lesion interrupting the left geniculocortical pathway, the paradoxical extinction was seen, as suggested by Sparks and Geschwind<sup>7</sup> and by Milner et al.,<sup>8</sup> in the presence of a deep left-hemisphere lesion that extends to the point where the auditory pathway, after crossing the corpus callosum from the right temporal lobe, arrives in the dominant hemisphere.

Studies on DL in cases of crossed aphasia have not, to our knowledge, been reported. This term<sup>9</sup> designates a pattern of aphasia of adult onset following a right-hemisphere lesion in a right-handed person. Some 90 cases are reported.<sup>10,11</sup> In the majority of the cases, however, a history of familial

sinistrality, a lack of complete right-handedness, or the presence of bilateral lesions have made acceptance of the syndrome open to question.

From a careful analysis of the reported cases, Brown and Hécaen<sup>12</sup> found only nine valid cases in which "the following criteria were satisfied: thorough language testing, a pathological lesion limited to the right hemisphere, absence of childhood brain damage, strong right-handedness, and a negative family history of left-handedness." At least seven more cases<sup>13-16</sup> (including unpublished report of G. Assal, MD) have since been described, to which the present case can be added. These patients usually show disorders of spoken language, with little difficulty in comprehension of spoken or written language.

As for etiology, Boller<sup>11</sup> points out that the great majority of the cases are of neoplastic or traumatic origin, whereas most of the reported cases of aphasia following brain damage on the left side in right-handed people are of vascular origin. According to Boller, the distance effects due to the tumor or the bilateral lesions caused by the trauma would produce disorders of language that could be mistakenly attributed to the lesion on the right side.

A last point of difference between normal and crossed aphasia is the age of incidence: the majority of the patients with crossed aphasia are under 40 years at the age of onset, whereas the mean age of those with normal aphasia is generally over 60 years.

We report the result of DL studies in a right-handed patient in whom a typical pattern of crossed aphasia developed following right carotid artery thrombosis. Also, we discuss some possible mechanisms of hemispheric specialization in such cases.

### REPORT OF A CASE

The patient was a 35-year-old man. He had been hypertensive (blood pressure, 180/100 mm Hg) for some years. He was ostensibly right-handed, and no instances

of left-handedness were found in his family.

In March 1978, he was admitted to another hospital because of abrupt onset of left hemiparesis (more marked in the upper limb) and aphasia, which was described as predominantly expressive. The speech disturbance occurred first, immediately followed by the motor impairment, without loss of consciousness. A carotid angiography showed an occlusion of the right internal carotid artery 4 mm above its origin. In the following days the patient showed a steady improvement in both motor and aphasic deficits.

When first seen in our department in November 1978, the patient was oriented, alert, and cooperative. His mood was appropriate, and short- and long-term memory were within normal limits. There was a left hemiparesis, more marked in the upper limb, with hyperreflexia and left Babinski's sign. Results of sensory examination, including two-point discrimination, were normal. No cerebellar signs were noted. Visual fields were normal to confrontation. Results of ophthalmoscopic examination were normal. Left central facial paresis was evident. In December 1978, a computerized tomographic (CT) scan (Fig 1) showed asymmetry of the lateral ventricles, the right being larger without shift. A large triangular area of hypodensity was evident in the right frontoparietal region that extended from the cortex downwards, with slight involvement of the basal ganglia, and close to the lateral wall of the body of lateral ventricle. On the basis of the scan, a mapping of the lesion was performed according to the criteria of Mazzocchi and Vignolo,<sup>17</sup> showing the boundaries of the ischemic damage on both a superficial and a deep level (Fig 2).

### Handedness Study

The patient reported that he had been right-handed since childhood. His handedness was tested by means of the Edinburgh Inventory,<sup>18</sup> which yielded a laterality quotient of +9. Informal testing of the patient's relatives failed to show cases of left-handedness or ambidexterity.

### Neuropsychological Studies

The patient's first language examination took place 20 days after the ictus. Spontaneous speech was limited to a few words intermixed with pauses. Articulatory disturbances, associated with phonemic paraphasias and with a mild pattern of

Accepted for publication May 24, 1980.  
From Clinica Neurologica dell'Università di Padova, Italy.

Read in part before the Second International Neuropsychological Society European Conference, June 28, 1979, Noordwijkerhout, Holland.

Reprint requests to Clinica Neurologica dell'Università, Via Giustiniani, 5, 35100 Padova, Italy (Dr Denes).

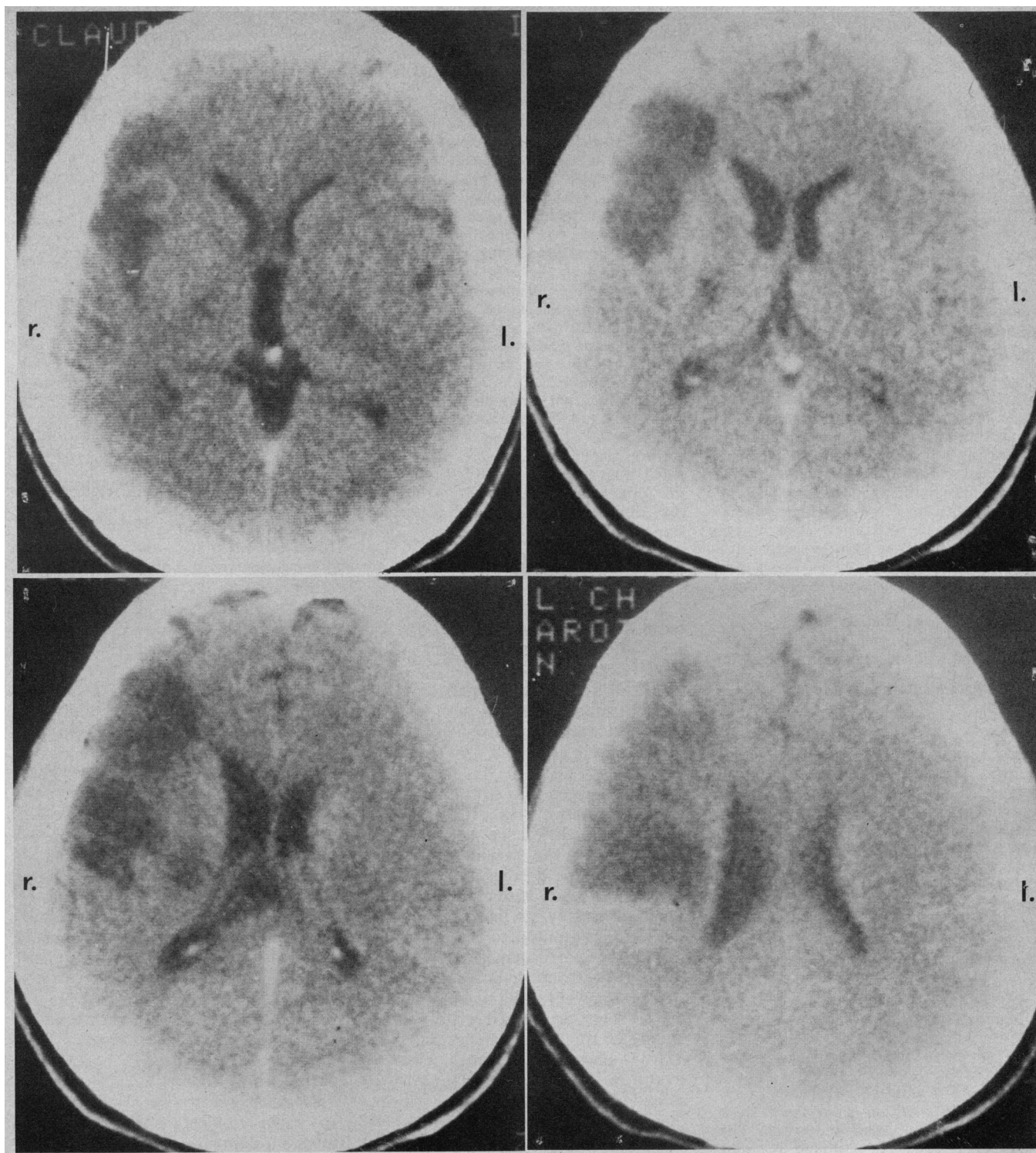


Fig 1.—Computerized tomographic scan obtained in December 1978 showing area of triangular hypodensity in right frontoparietal region, which extends from cortex downwards, arriving close to lateral wall of body of lateral ventricle.

agrammatism, were noted. Comprehension was good for both words and sentences, but he scored 12 of 36 in the shortened version of the Token test.<sup>19</sup> Repetition was good for letters, words, and short sentences, while he failed with sentences of more than five words. His ability to name was impaired (four items of 20). Reading aloud was fairly well preserved, with better per-

formance with sentences than with words and better with words than with syllables and single letters. Some verbal paraphasias (tablecloth instead of table) were noted.

A second examination was performed six months later using an Italian version of the Goodglass and Kaplan battery.<sup>20</sup> Spontaneous speech was of normal fluency and prosody, with correct use of grammatical

parts and normal phrase length and with rare phonemic paraphasias. The informational content was proportional to the length of the sentence, but frequent anomic disturbances were present. The patient showed good comprehension in a word-discrimination test (20 of 20) while he scored five of 11 in a test of execution of complex orders. He scored 26 of 36 in the

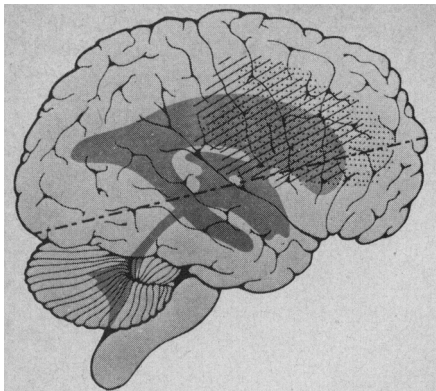


Fig 2.—Mapping of lesion, showing boundaries of ischemic damage at both superficial (triangles) and deep (lines) levels.

Token test, which is below the minimum in relation to his age and educational level.

On an automated sequence test, he performed well in spite of a marked difficulty in starting the sequence. He obtained the maximum score in the repetition tests. His performance in the object-naming tests, in contrast with the word-searching difficulties noted in his spontaneous speech, was good: he scored 25 of 30 in the responsive naming test, 95 of 105 in the visual confrontation naming test, and 26 of 30 in the body-parts naming test. Reading and understanding of written language were good. Writing was good, too, with normal fluency and without any paraphasia.

#### Related Cortical Functions

No signs of apraxia were noted apart from a mild pattern of oral apraxia during the first stages of his illness. His drawing abilities, both spontaneous and on copy, were good. No signs of oral or written dyscalculia were present. On Raven's progressive matrices 1938, he scored 48 of 60 four months after the ictus. Two months later, a Wechsler Adult Intelligence Scale showed a verbal score of 67 and a performance score of 45 with a total score of 112, corresponding to an IQ of 103.

Finger gnosis was good. No signs of unilateral spatial agnosia were present.

#### DL Tests

**Materials.**—The tape used for these tests was that adopted by Mazzucchi and Parma,<sup>21</sup> prepared following the technique suggested by Rubino.<sup>22</sup> Dichotic stimuli were recorded with a 5-s silence between stimuli. Digits within a sequence were separated by half-second intervals. The tape was played on a stereo recorder through stereo headphones; the output of the two channels was calibrated to about 70 dB.

**Procedure.**—Although an audiometric test was not administered to our patient, we checked the subjective loudness at each ear carefully. He was told to inform the examiner if at any time during the test he felt a different volume in the two ears. Furthermore, before testing we determined his digit span monoaurally; six digits were reported correctly in both ears.

Our test was formed of three sets of stimuli presented dichotically; each set consisted of 12 pairs of stimuli. The sequence of sets was as follows: two digits, three digits, two words. In set 3, the items used were common two-syllable words. Before the first two sets, the patient heard two pairs of stimuli as practice trials. He was instructed to report what he had heard after each pair without time limits. No instructions were given about the order of report. In the middle of each set, ie, after the sixth pair, the headphones were reversed. As regards scoring procedures, 1 point was given for each item, digit, or word that he correctly reported; no guessing correction was adopted.

The same test was repeated a few days later under the influence of selective attention; the patient was instructed to recall the items presented in either his right or left ear, ignoring what he heard in the unattended ear. No instructions were given about the order of report. Again, the performances of the two ears were compared using the same scoring procedures of the former test. The first set of stimuli (two digits) was used only as a practice trial.

#### RESULTS

The results of the series without focused attention were as follows: set 1, 83% in the right ear (RE) and 75% in the left ear (LE); set 2, 33% (RE) and 97% (LE); and set 3, 50% (RE) and 79% (LE). Results of the test with focused attention were as follows: set 2, 97% (RE and LE); and set 3, 58% (RE) and 91% (LE).

It can be seen that in the first trial his performance was good, without any notable difference between the two ears. In the second and third trials, a marked decrease in reporting both digits and words was present. This fact was by far more evident for the items presented to the right ear, where the performance dropped to 33% for digits and to 50% for words.

When, however, the dichotic listening test was performed with precued unilateral recall, his performance improved, showing a nearly flawless report in set 2, independent of the attended ear. In set 3, however, though his performance was 91% correct in recalling words presented to the left ear, he was able to report only 58% of the items presented to the right ear.

#### COMMENT

The present case seems to fit all of the criteria that are said to be necessary for a correct diagnosis of crossed aphasia: strict right-handedness without any history of familial sinistrality, absence of childhood brain damage, pathologic changes confined to the

right hemisphere, and definite language impairment tested with thorough language examination. His aphasia involved spoken speech primarily, although the poor Token-test performance suggested mild comprehension deficits.

When language disturbances follow right hemisphere damage in a right-handed patient, the question must naturally arise whether they are really expressions of involvement of nervous structures subserving language or if they could be the result of an acute, confusional state following a right hemisphere lesion. This latter point is not academic, since quite recently Mesulam et al<sup>23</sup> described some patients in whom an acute confusional state developed following an infarct in the distribution of the right middle cerebral artery. In a recent review of disorders of higher cortical functions in acute confusional states of various etiology, Chédru and Geschwind<sup>24</sup> found disturbances of language function in many cases that were often accompanied by disturbances in other cognitive functions. Our patient's language disturbances were present in the absence of other neuropsychological deficits. His attention was good, as shown by his normal digit span. His ability in calculating and drawing was maintained, and his IQ was well within normal limits. In addition, it is important to point out the cerebrovascular etiology, which is not likely to produce long-distance effects, especially eight months after its onset. The lack of right-hemisphere lesion signs as visuospatial neglect or constructional deficits is worth mentioning, since in our patient the right hemisphere seems to subserve only linguistic functions. At this point, it seems appropriate to remember that Hécaen and Sauguet<sup>25</sup> found that a right-hemisphere lesion in left-handed subjects is characterized by the comparatively high frequency of language disturbances, whereas disturbances of calculation, praxis, and visuognosis are similar to those found in right-handers with right-hemisphere lesions. On the contrary, a left-hemisphere syndrome in left-handers causes a language impairment similar to but of a less marked degree than that found in right-handers. Such language disturbances, however, are concomitant with some other symptoms that are generally seen following right-sided lesions in right-handers. Another characteristic of these subjects appears to be a less marked intrahemispheric localization of the neurological loci subserving higher

cortical functions.

As far as DL performance is concerned, the following points are worth stressing: when the task was easy, he scored almost perfectly with both ears, showing neither dominance nor lesion effect; with increasing task difficulty, however, he showed a dramatic loss in his ability to recall and report the items presented to the right ear, showing a clear-cut pattern of paradoxical extinction.

In a very recent study, Damasio and Damasio<sup>26</sup> found that an ipsilateral extinction on DL can be found with deep suprasylvian lesions in the parietal or parietooccipital regions, in the left or right hemisphere close to the lateral ventricles, blocking the interhemispheric auditory pathway traveling from the nondominant hemisphere to the posterior temporal region of the dominant one. In the present case, the findings of CT scan

showing a deep lesion close to the wall of the lateral ventricle, although slightly more anterior than expected, seemed to indicate that the same pattern can be responsible for the ipsilateral extinction, which therefore is not at all paradoxical. A similar pattern was pointed out by Damasio et al,<sup>6</sup> who found a right-ear extinction in a left-handed subject who was found to be right-hemisphere dominant by the Wada test,<sup>27</sup> and by Rubens et al<sup>3</sup> in right-handed aphasic patients following deep suprasylvian lesions.

With regard to the effect of precued recall, it must be remembered<sup>28</sup> that the degree of the dominant ear advantage usually is reduced by focused attention and increased by task difficulty. These considerations can explain the lack of differences between the performances of the two ears when using digits and the noticeable bias when using words. Actually, set 3

(two words) proved to be more difficult than did set 2 (three digits) not only in the present case but also when used by Mazzucchi and Parma<sup>21</sup> both in control subjects and in temporal-lobe epileptic patients.

A last point must be considered: our patient, like the majority of crossed aphasic patients, had a very good recovery. This fact has been judged by some authors<sup>12</sup> as a sign of a minor degree of cerebral dominance for language, allowing a good recovery by the left hemisphere, which is endowed with linguistic functions. The DL studies in our patient, showing that the right hemisphere has maintained the dominance for language despite the lesion, cast some doubts on such a hypothesis.

Anna Mazzucchi, MD, and Mario Parma, MD, provided the dichotic tape. Norman Geschwind, MD, revised an earlier version of this report.

#### References

- Schulhoff C, Goodglass H: Dichotic listening, side of brain injury, and cerebral dominance. *Neuropsychologia* 1969;8:149-160.
- Sparks R, Goodglass H, Nickel B: Ipsilateral vs contralateral extinction in dichotic listening resulting from hemisphere lesions. *Cortex* 1970;6:249-260.
- Rubens AB, Johnson MG, Speaks C: Location of lesions responsible for the 'paradoxical ipsilateral effect' with dichotic listening tests in patients with aphasia due to stroke, abstracted. *Neurology* 1978;28:396.
- Kimura D: Some effects of temporal lobe damage on auditory perception. *Can J Psychol* 1961;15:156-165.
- Michel F, Peronnet P: Extinction gauche au test dichotique: Lésion hémisphérique ou lésion commissurale? in Michel F, Schott B (eds): *Les syndromes de disconnexion calleuse chez l'homme*. Lyons, France, Colloque International de Lyon, 1975, pp 85-117.
- Damasio H, Damasio AR, Castro-Caldas A, et al: Dichotic listening pattern in relation to interhemispheric disconnection. *Neuropsychologia* 1976;14:247-250.
- Sparks R, Geschwind N: Dichotic listening in man after section of neocortical commissures. *Cortex* 1968;4:3-16.
- Milner B, Taylor L, Sperry RW: Lateralized suppression of dichotically presented digits after commissural section in man. *Science* 1968;161:184-186.
- Bramwell B: On crossed aphasia. *Lancet* 1899;1:1473-1479.
- Roberts L: Aphasia, apraxia, and agnosia in abnormal states of cerebral dominance, in Vinken P, Bruyn GM (eds): *Handbook of Clinical Neurology*. Amsterdam, Elsevier North Holland Inc, 1969, vol 4, pp 312-326.
- Boller F: Destruction of Wernicke's area without language disturbance. *Neuropsychologia* 1973;11:243-246.
- Brown JW, Hécaen H: Lateralization and language representation. *Neurology* 1976;26:183-189.
- April RS, Tse PC: Crossed aphasia in a Chinese bilingual dextral. *Arch Neurol* 1977;34:766-770.
- Urbain E, Seron X, Remits A, et al: Aphasie croisée chez une droitier: A propos d'une observation. *Rev Neurol* 1978;12:751-759.
- Pillon B, Desi M, Lhermitte F: Deux cas d'aphasie croisée avec jargonographie chez des droitiers. *Rev Neurol* 1979;1:15-30.
- Zangwill OL: Two cases of crossed aphasia in dextrals. *Neuropsychologia* 1979;17:167-172.
- Mazzucchi F, Vignolo LA: Computer assisted tomography in neuropsychological research: A simple procedure for lesion mapping. *Cortex* 1978;14:136-144.
- Oldfield RC: The assessment and analysis of handedness: The Edinburgh Inventory. *Neuropsychologia* 1971;9:97-133.
- De Renzi E, Faglioni P: L'esame dei disturbi afasici di comprensione orale mediante una versione abbreviata del test dei gettoni. *Riv Patol Nerv Ment* 1975;96:252-269.
- Goodglass H, Kaplan E: *The Assessment of Aphasia and Related Disorders*. Philadelphia, Lea & Febiger, 1972.
- Mazzucchi A, Parma M: Responses to dichotic listening tasks in temporal epileptics with or without clinically evident lesions. *Cortex* 1978;14:381-390.
- Rubino CA: A simple procedure for constructing dichotic listening tapes. *Cortex* 1972;8:333-338.
- Mesulam MM, Waxman SG, Geschwind N, et al: Acute confusional states with right middle cerebral artery infarctions. *J Neurol Neurosurg Psychiatry* 1976;39:84-89.
- Chédru F, Geschwind N: Disorders of higher cortical functions in acute confusional states. *Cortex* 1972;8:395-411.
- Hécaen H, Sauguet J: Cerebral dominance in left-handed subjects. *Cortex* 1971;7:19-48.
- Damasio H, Damasio AR: 'Paradoxical' ear extinction in dichotic listening: Possible anatomic significance. *Neurology* 1979;29:644-653.
- Wada J, Rasmussen TR: Intracarotid injection of sodium amytal for the lateralization of cerebral speech dominance. *J Neurosurg* 1960;17:266-282.
- Geffen G: The development of the right ear advantage in dichotic listening with focused attention. *Cortex* 1978;14:169-177.