

Crossed Dextral Aphasia: A Clinical Radiological Correlation

PHILIP R. YARNELL

University of Colorado Medical Center

Three lifelong right-handed patients with clinically and radiologically well-defined right-hemispheric infarctions became aphasic. Their language functions in the rehabilitative, subacute phase of their illness were characterized by fluent, literal paraphasic output, dyslexia, and dysgraphia. Auditory comprehension was fair for contextual conversation, and the combination of language abilities enabled them to reach a "functional communication" stage. This study was unable to determine why these three patients had crossed dextral aphasias resulting from their otherwise typical clinical and radiological right-hemispheric infarcts. Of interest, the radiologically well-defined lesions, aside from being ipsilateral, fitted well the "posterior" fluency localization in two of the three patients, but was more extensive in the third.

Crossed dextral aphasia refers to a right-hemisphere lesion yielding as aphasia in a right-handed patient. Brown and Wilson (1973), and Brown and Hacaen (1976) have comprehensively reviewed the literature of this relatively rare occurrence. The language characteristics and approximate lesion location in nine dextral patients were tabulated and discussed.

With the widespread advent of, first, radionuclide imaging, and then computerized tomography (C.T.) scanning, investigators have been interested in clinical-radiological characterization of aphasia deficits during life (Benson & Patten, 1967; Benson, 1967; Karis & Hornstein, 1976; Kersetz, Lesk, & McCabe, 1977; Yarnell, Monroe, & Sobel, 1976; Hayward, Nasser, & Zatz, 1977; Nasser & Hayward, 1978; Kersetz, Harlock, & Coates, 1979). Patients with completed cerebral infarctions rather than those with tumors or trauma have yielded the most defined anatomic-clinical aphasia correlation for study (Yarnell et al., 1976; Hayward et al 1977; Nasser & Hayward, 1978; Kersetz et al., 1979).

I am indebted to Ms. Claire Ludlow, former Director of Speech Pathology, Spalding Rehabilitation Center for her help in collating the speech data, and to J. Kim and J. Ritsick for referring their patients for study. Send all correspondence and reprint requests to: Philip R. Yarnell, 1471 Stuart St., Denver, CO 80204.

Three cases of crossed dextral aphasia have recently been investigated with clinical radiological correlation. The large majority of previously described crossed dextral aphasics have nonfluent agrammatism and mutism as their most common characteristic (Brown and Hecaen, 1976). The present patients are then even more unusual in that their right-hemisphere infarctions were associated with aphasias that were considered fluent by Geschwind's (1971) classification schema.

PATIENT DATA

Patient 1

History. A 61-year-old right-handed chronic alcoholic accountant had several prior admissions for confusion and ataxia and seizures during the year prior to his aphasia event. Serial radionuclide images and electroencephalograms were normal. On each of these preceding admissions he recovered to a jovial normal state after alcohol withdrawal. There was a history of childhood stuttering. He was readmitted, confused but with a specific language disturbance.

Clinical (1 month postinfarction). He was alert and usually initially cooperative but as the examination progressed he would become increasingly frustrated and belligerent. He was impulsive and had a tendency to geographical disorientation. A suggestive confrontation left hemianopsia was present, but he would attend to left space. There was a mild decrease in left-arm sensation. The motor system was intact. Electrencephalography now demonstrated a right-temporal slow-wave focus.

Radiology. Radionuclide images showed an evolving right-inferior-parietal lateral static uptake (Fig. 1) resolving over 2 months. A right-parietal arterial branch occlusion with an early-draining vein was demonstrated on angiography.

Language (1 month postinfarction). (1) Oral language. There was a jargon fluent circumlocutious output intermixed with real-word automatic appropriate phrases. Also present were periods of literal paraphasia and verbally apraxic struggling stuttering speech.

(2) Auditory comprehension. He could follow two- to three-step commands with repetition. He was inconsistent in responding to general information queries.

(3) Lexic skills. He was dyslexic, reading and recognizing only simple single words.

(4) Naming. He was dysnomic with jargon or circumlocutious automatic phrase-naming attempts with general unawareness of errors.

(5) Repetition. He was unable to repeat even in unison. This gave rise to much struggling, stuttering behavior.

(6) Apraxia. Severe verbal apraxia was present.

(7) Graphic skills. He was severely dysgraphic. He could only write his name. He could not write words or numbers.

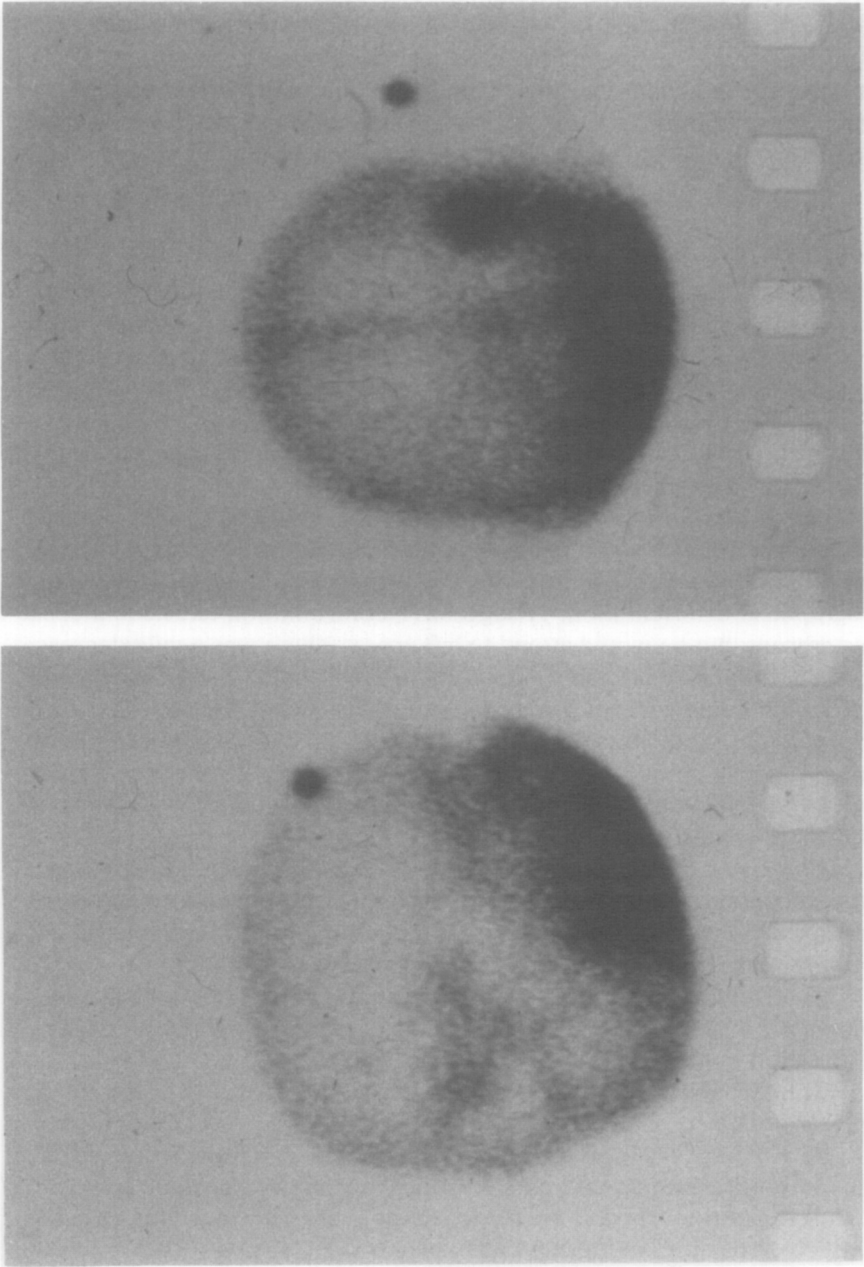


FIG. 1. Radionuclide right-lateral (left) and posterior (right) images of Patient 1 revealing a right-superior-temporal, inferior-posterior-parietal uptake.

Language summary. His speech was characterized by a mixture of fluent jargon, automatic phrase circumlocutiousness, and stuttering verbal-apraxia behavior. He was dyslexic, dysgraphic, and dysnomic and could not repeat. His comprehension was inconsistent but better in context. He was considered a semifunctional communicator on leaving the rehabilitation center to his residence.

Patient 2

History. A 68-year-old right-handed retired farmer awoke with a left hemiplegia the week following an inguinal herniography. Peptic-ulcer bleeding and urinary sepsis further complicated his acute hospitalization. Five months postinfarction he had a seizure.

Clinical (6 months postinfarction). He was bright and affable. He showed a progressively diminishing intermittent disorientation. A left hemianopsia with some tendency to left-spatial neglect and a dense left-hemisensory loss were present. He had a spastic left hemipelagia and was moderately dysarthric. He could ambulate with a brace and hemiwalker with one person assisting. He needed minimal to moderate assistance in the activities of daily living but could be trained.

Radiology (5 months postinfarction). Radionuclide images showed a diffuse holo-, right-middle-cerebral distribution uptake. The C.T. scan showed a very extensive right-temporo-parietal low-absorption area with compensatory, right-ventricular dilatation (Fig. 2).

Language (6 months postinfarction). (1) Oral language. There was fluent output with phonemic paraphasia and perseverations. He was moderately dysarthric also.

(2) Auditory comprehension. He could follow two-level commands and did fairly well in simple contextual conversation.

(3) Lexic skills. He had moderate comprehension problems at the sentence level.

(4) Naming. He was literally paraphasic and made increasing errors on attempting serial object naming.

(5) Repetition. He was unable to repeat.

(6) Apraxia. He had a moderately severe oral apraxia.

(7) Graphic skills. He was dysgraphic with misspellings and perseveration errors. He could only inconsistently copy single words.

Language summary. He had a conduction-type fluent literal paraphasic aphasia with dysgraphia, fair lexic skills, and moderate dysnomia. He had a relatively better-persevered contextual oral comprehension and was discharged to his home as a functional communicator in familiar surroundings.

Patient 3

History. A 66-year-old right-handed, retired carpenter developed left-sided weakness evolving over a day into a left hemiplegia with associated

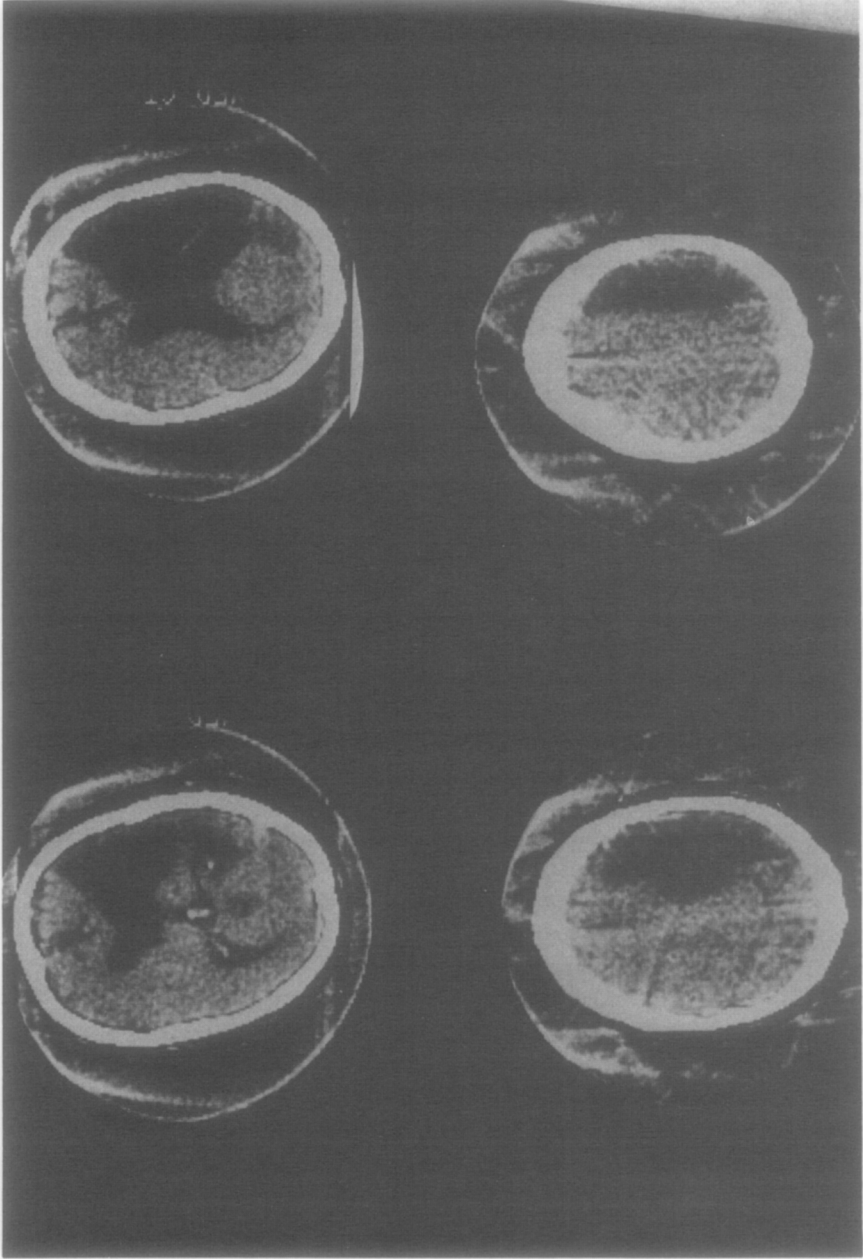


FIG. 2. C.T. scan of Patient 2. Selected serial sections reveal an extensive right-sided frontal-temporo-parietal low-absorption region with ipsilateral ventricular dilation most marked in the posterior-lateral ventricle body area.

language dysfunction. One year prior he had a transient left-body weakness resolving in a few days without hospitalization and without any language disturbance.

Clinical (2½ months postinfarction). Initially he was easily confused on testing, but this gradually resolved. He had intact memory and could slowly learn sequencing tasks such as patterned dressing after early initial confusion. A gross left hemianopsia with inconsistent awareness of his left side and a dense left-hemisensory loss were present. He was mildly dysarthric and had a spastic left hemiparesis. He could ambulate with a cane and brace and could grossly move his proximal left arm. He was educable in the activities of daily living.

Radiology (2½ months postinfarction). Radionuclide images showed a right-postero-parietal lateral uptake (Fig. 3). The C.T. scan showed a right-postero-parietal cortical low-absorbtion area with peripheral enhancement (Fig. 4).

Language (2½ months postinfarction). (1) Oral language. There was a fluent, circumlocutious mixed jargon and literal paraphasic speech with a tendency to verbocity. He was mildly dysarthric.

(2) Auditory comprehension. He could follow two-level commands and had fair to good contextual conversational comprehension. However, he would fail in complex input situations.

(3) Lexic skills. There was a severe dyslexia with even inconsistent matching of words to pictures.

(4) Naming. He made unrecognized paraphasic errors but had some word-searching frustration behavior as well.

(5) Repetition. He could repeat simple phrases but he made errors at the sentence level without awareness.

(6) Apraxia. None.

(7) Graphic skills. He was severely dysgraphic. He scribbled with only some real letters.

Language summary. He had fluent, literal paraphasic, jargon, circumlocutious speech with severe dyslexia and dysgraphia. Repetition and naming abilities were only fair. He had relatively better-preserved contextual conversational comprehension and was considered a functional home communicator upon discharge to his home.

DISCUSSION

The study of these three patients with crossed dextral aphasia yields interesting findings. Surprisingly, all showed fluent literal paraphasic speech with fair to good two-level command and contextual conversation comprehension. Dysnomia characterized by many unrecognized paraphasic errors was a common feature. Only Patient 2 had fair lexic skills, while only Patient 3 had fair repetition ability. All were poor at graphic skills although the writing, right-hand motor functions were normal.

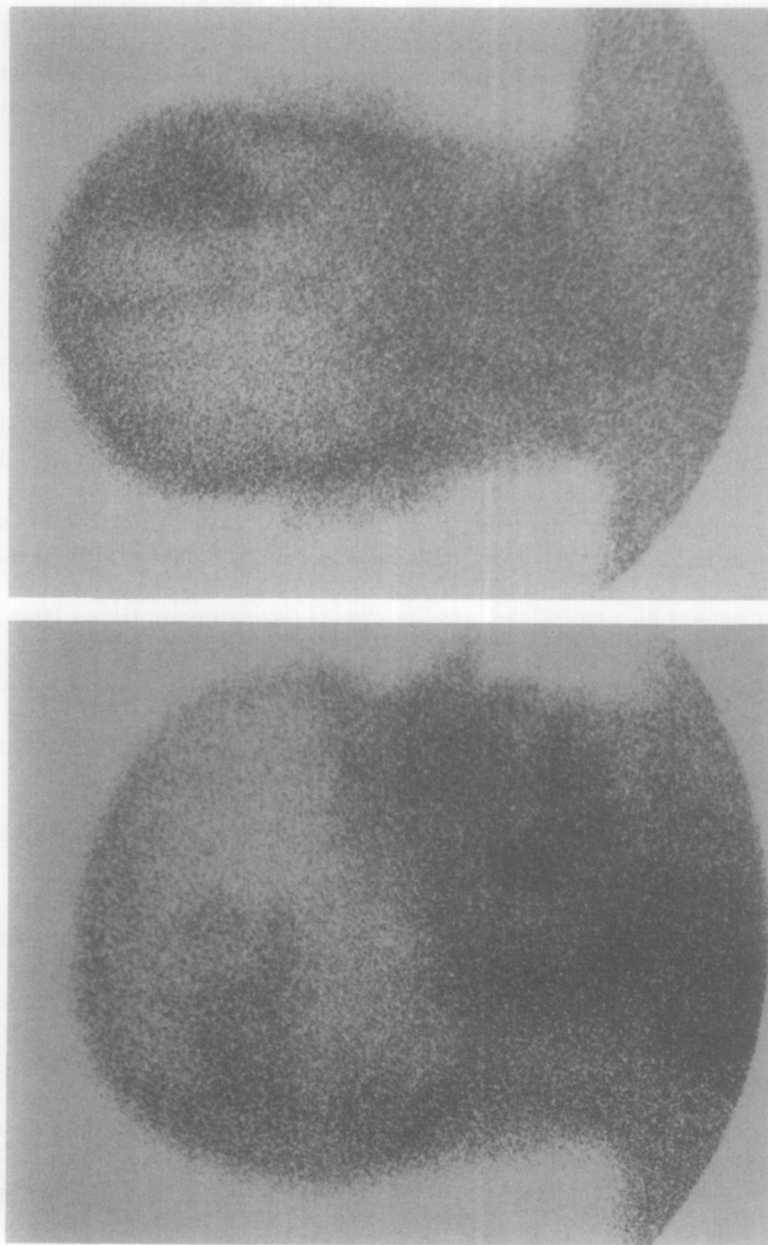

FIG. 3. Radionuclide right-lateral (left) and posterior (right) images of Patient 3 revealing a right-sided posterior-inferior and midparietal uptake.

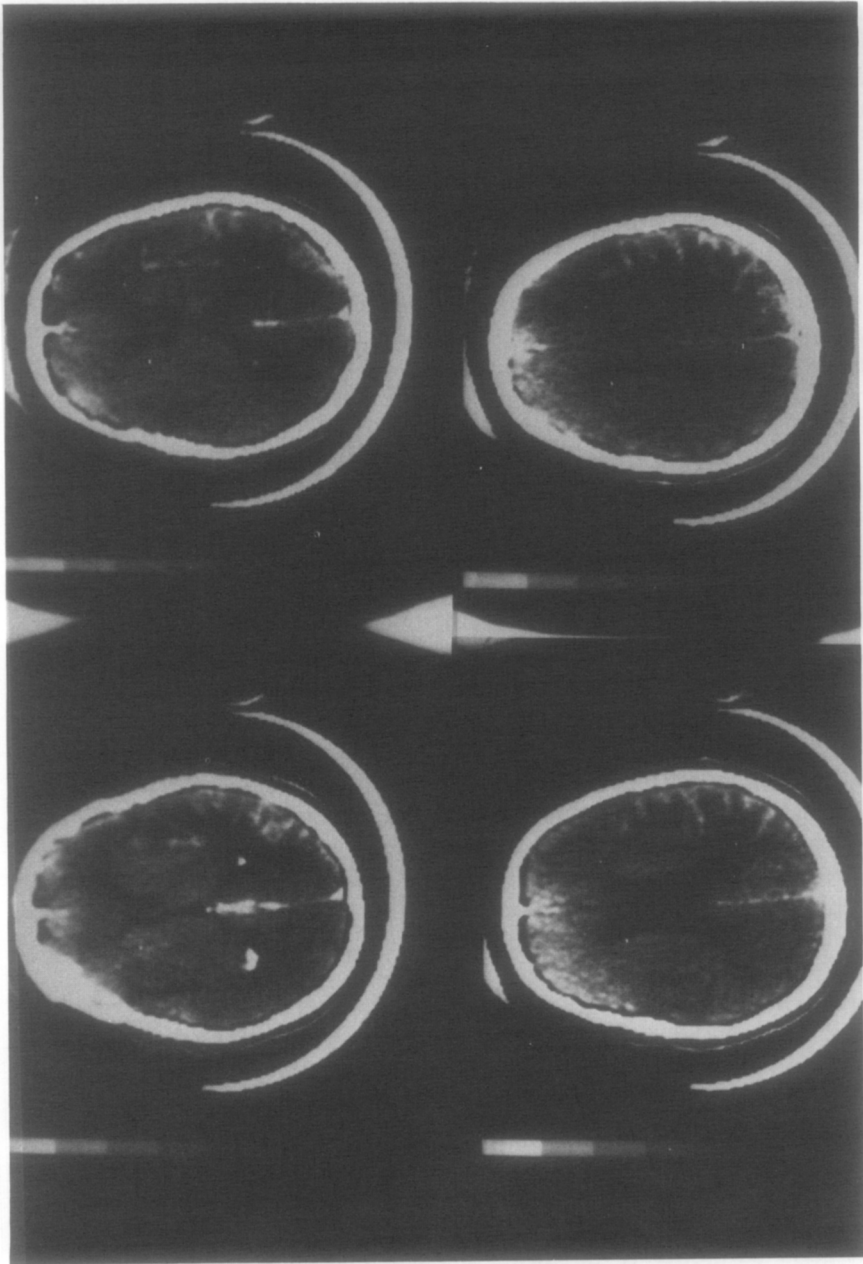


FIG. 4. C.T. scan with enhancement of Patient 3 revealing a right peritrial and posterior-lateral ventricle body low-density area with surrounding enhancement.

These evaluations were at the subacute stages of their illnesses when the language deficits were fairly stable. All, at the time of discharge from the rehabilitation center, had reached at least a semifunctional communicator status through their circumlocutious paraphasic fluent speech and their relatively preserved contextual understanding. All were able to return to their homes.

Brown and Hecaen (1976) note that the occurrence of aphasia in right-handed individuals with a right-hemisphere lesion is most unusual. Percentages ranging from 1.8% in Zangwill's (1967) series, to 1% in the work of Gloning, Gloning, Haub, and Quatember (1969), down to 0.38% in the review by Hecaen et al. (as cited by Brown & Hecaen, 1976) are noted. Geschwind (1971) also agrees, stating that right-hemisphere lesions produce aphasia in right-handers in less than 1 of 100 cases. Our patients testified to being lifelong nonswitched right-handers; however, a total family history as to any sinistrality was not fully explored or available.

Patient 1 was a lifelong intermittent stutterer which was exacerbated by his aphasia. Childhood brain injury was not historically known in any of the patients. Patient 1 and 3 had prior central nervous system dysfunction within the year preceding their aphasias. Seizures, ataxia, and confusion in Patient 1 and a mild left hemiparesis in Patient 3 totally resolved without residual. No aphasic deficit was recorded by neurologic examination in Patient 1 during his alcoholic detoxification stays or by an extensive history in Patient 3. Patient 1 had normal serial radionuclide images and electroencephalograms during these earlier events which then became focally right-hemispheric abnormal during his aphasic event. Patient 3 was not hospitalized nor did he have any laboratory tests during his transient hemiparetic episode.

The three patients had a left-field defect to confrontation testing but each was able to learn to attend to his left body and space. Sensory deficit was present on the left side in all. Patients 2 and 3 each had a significant left hemiparesis. Fluent aphasia combined with significant hemiparesis is unusual in "noncrossed" right-handed aphasic patients (Geschwind, 1971).

Brown and Hecaen (1976) made a most thorough summary and tabulation of the crossed dextral aphasia literature. They concluded that the most common feature of crossed dextral aphasia is a nonfluent agrammatism or even mutism. Agrammatism occurred in eight of their nine summarized patients. Mutism was initially present in six of nine patients lasting up to 9 months in one. Naming was fair to good in eight of nine patients while repetition was either well preserved or showed the characteristics of the patients' spontaneous speech. Oral comprehension varied from good to moderate impairment in seven of the nine with severe impairment in the remaining two. Only one patient in their summary table, that of Hecaen et al., had a fluent aphasia without agrammatism.

Thus our patients are even more exceptional in contrast to the summarized crossed dextral aphasics in that they all were fluent without agrammatism. In their summarized cases, Brown and Hecaen (1976) only listed two of the patients as having "posterior lesions," the previously mentioned patient of Hecaen et al. with a right-temporo-parietal hematoma and Ettlinger, Jackson, and Zangwill's (1955) patient with a right temporal lobectomy. Three of the summarized patients had anterior lesions while the remaining four had central lesions. All of the present patients had at least some major radiologically defined involvement in the "posterior" area as defined by bordering the posterior body and atrial portion of the lateral ventricle. This localization, by serial radionuclide images in Patient 1 and by both radionuclide images and computerized tomography scans in Patients 2 and 3, represented the predominant involvement site, in Patients 1 and 3. In Patient 2 the infarction was more extensive, a holo-right-middle-cerebral distribution, so the "posterior" aspect was only a portion of the total area. For the usual right-handed, left-hemisphere-infarction patient, the postrolandic, posterior parietal-superior temporal areas were the regions best correlating with aphasia fluency in the radionuclide localization of both Benson (1967) and Kersetz et al. (1977), in the combined angiographic, radionuclide, C.T. scan study of Yarnell, et al. (1976) and the C.T. scan localization study of Nasser and Hayward (1978). Kersetz et al. (1977) used anatomical templates for their radionuclide study, and Nasser and Hayward (1978) made composite line drawing localization maps from their C.T. study to correlate radiologically the various aphasia classification.

Patients 1 and 3 might be predicted to have fluent aphasias from most of the prior studies if their lesions had been left hemispheric (Benson, 1967; Kersetz et al., 1977; Yarnell et al. 1976; Hayward et al., 1977). Patient 2's most extensive lesion would be more consistent with a global aphasia if it were in the left hemisphere (Kersetz et al., 1977; Yarnell et al., 1976; Nasser and Hayward, 1978). The patient of Hecaen et al., one of the two "posterior" lesion patients summarized by Brown and Hecaen (1976), had a right-temporo-parietal hematoma which would fit into most of the fluent aphasia localizations for left hemispheric lesions. However, the other posterior lesion patient, the patient of Ettlinger et al. (1955), had a right temporal lobectomy lesion which might have spared the para-atrial, posterior lateral ventricular body area of fluency localization.

Thus the prior findings of mutism evolving into agrammatism in the characteristic crossed dextral aphasic may simply represent a reflection of lesion localization. The preponderance of anterior and central infarct lesion patients, if they were "noncrossed," would fit into most authors' nonfluent aphasia localizations (Kersetz et al., 1977; Yarnell et al., 1976; Nasser & Hayward, 1978; Geschwind, 1971).

The reasons for the rare case of some right-handers developing aphasia

TABLE 1
LANGUAGE-RADIOLOGIC CORRELATION SUMMARY

Patient	Oral language	Auditory comprehension	Reading	Naming	Repetition	Apraxia	Writing	Localization
1 61/M	Fluent, literal paraphasias, jargon circumlocutious, automatic, stuttering	Fair two- to three-step commands and fair but inconsistent conversational level	Severe dyslexia	Severe dysnomia	Unable	Verbal, severe	Severe dysgraphia	Right posterior superior temporal-inferior parietal
2 68/M	Fluent literal paraphasias, perseverations	Good two-level commands and fair to good in contextual conversation	Moderate	Moderate dysnomia	Unable	Oral, moderately severe	Moderately severe dysgraphia	Right fronto-temporo-parietal, extensive lesion
3 66/M	Fluent circumlocutious jargon literal paraphasias, verbose	Good two-level commands and fair to good in contextual conversation	Severe dyslexia	Moderate dysnomia	Fair	None	Severe dysgraphia	Right posterior parietal

from their right-hemisphere infarction remains unanswered from this study. Radiologically, there were not multifocal, bihemispheric, or unusual morphology lesions to help explain this phenomenon. Furthermore, the vast majority of right-handers with such right-hemisphere radiologically defined lesions will not become aphasic.

REFERENCES

- Benson, D. F., Patten, D. H. 1967. The use of radioactive isotopes in the localization of aphasia producing lesions. *Cortex*, **3**, 258–271.
- Benson, D. F. 1967. Fluency in aphasia. Correlation with radioactive scan localization. *Cortex*, **3**, 373–394.
- Brown, J. W., & Wilson, F. R. 1973. Crossed aphasia in a dextral. *Neurology*, **23**, 907–911.
- Brown, J. W., & Hecaen, H. 1976. Lateralization and language representation. *Neurology*, **26**, 183–189.
- Ettlinger, G., Jackson G. V., & Zangwill, O. L. 1955. Dysphasia following right temporal lobectomy in a right-handed man. *Journal of Neurology, Neurosurgery and Psychiatry*, **18**, 214–217.
- Geschwind, N. 1971. Current concepts. Aphasia. *New England Journal of Medicine*, **284**, 654–656.
- Gloning, I., Gloning, K., Haub, G., & Quatember, K. 1969. Comparison of verbal behavior in right-handed and non right-handed patients with anatomically verified lesion of one hemisphere. *Cortex*, **5**, 43–52.
- Hayward, R. W., Nasser, M. A., Zatz, L. M. 1977. Cranial computed tomography in aphasia. *Radiology*, **123**, 653–660.
- Karis, R., & Hornstein, S. 1976. Localization of speech parameters by brain scan. *Neurology*, **26**, 226–230.
- Kersetz, A., Lesk, K., & McCabe, P. 1977. Isotope localization of infarcts in aphasia. *Archives of Neurology*, **34**, 590–601.
- Kersetz, A., Harlock, W., & Coates, R. 1979. Computer tomographic localization: Lesion size and prognosis in aphasic and nonverbal impairment. *Brain and Language* **8**, 34–50.
- Nasser, M. A., & Hayward, R. W. 1978. Lesion localization in aphasia with cranial computed tomography and the Boston Diagnostic Aphasia Exam. *Neurology*, **28**, 545–551.
- Yarnell, P., Monroe, P., & Sobel, L. 1976. Aphasia outcome in stroke—A clinical neuroradiological correlation. *Stroke*, **7**, 516–522.
- Zangwill, O. L. 1967. Speech and the minor hemisphere. *Acta Neurologica (Belgium)*, **67**, 1013–1020.