

## Psychometric and CT Scan Measurements in a Case of Crossed Aphasia in a Dextral

K. YORK HAALAND

*Veterans Administration Medical Center and University of New Mexico*

AND

FERNANDO MIRANDA

*Lovelace Medical Center and University of New Mexico Medical Center*

A case of crossed aphasia with lesion deep to the right supramarginal gyrus was studied to determine (1) if this patient behaved similar to patients with the same lesion site in the left hemisphere, (2) if visuospatial deficits were present, and (3) if the CT scan asymmetries were similar to those of other right-handers. Speech and language skills were similar to those patients with similar lesions in the left hemisphere. Visuospatial and arithmetic deficits were similar to those described after right-hemisphere and left-hemisphere damage. CT scan asymmetries were atypical. These results provide behavioral and neuroradiological confirmation of atypical hemispheric dominance.

### INTRODUCTION

The incidence of aphasia after right-hemisphere damage in right-handers is quite rare with estimates ranging from 1% (Gloning, Gloning, Haub, & Quatember, 1969) to 3.8% (Zangwill, 1967). Fifteen cases with no evidence of personal or familial left-handedness have been reported in some detail (Brown & Hecaen, 1976; Russel & Espir, 1961; Hecaen, Mazars, Ramier, et al., 1971; Foroglou, Assal, & Zander, 1975; Urbain, Seron, Remits, et al., 1978; Wechsler, 1973; Zangwill, 1979). Very few

This research was supported by the Albuquerque Veterans Administration Medical Center and parts of this paper were presented at the Academy of Aphasia, South Yarmouth, MA, October 7, 1980. We would like to thank Dr. Margaret Naeser and her colleague Jean M. Pieniadz for measuring the CT scans and reading the manuscript. We would also like to thank David Flaherty and Carol Christenson who administered many of the speech and language tests. Address reprint requests to Dr. K. Y. Haaland, Psychology Service, Veterans Administration Medical Center, Albuquerque, NM 87108.

of these reports have included extensive evaluation of cognitive skills using psychometric instruments. Since cases of crossed aphasia are relatively rare, it would be useful to have psychometric tests for comparison (1) across similar cases, (2) between right-handed patients with aphasia due to right- or left-hemisphere lesions, and (3) between crossed aphasia in dextrals and uncrossed aphasia in sinistrals, to determine if language deficits associated with right-hemisphere damage share certain characteristics. After a series is accumulated it would be possible to determine if the pattern of cognitive deficits is different in the crossed-aphasic patient.

Brown and Hecaen (1976) have suggested most of the cases of crossed aphasia in the literature report "speech has been agrammatic, repetition and naming fair and comprehension moderately impaired. . . . Reading comprehension may be superior to auditory comprehension, and writing superior to speech. Visuospatial ability may be intact or impaired and apraxia is uncommon." These statements, however, are all qualitative and there is no basis for direct comparison except in those cases seen by the same investigator and even then reliability must be questioned.

In addition, various studies have confirmed anatomical asymmetries between the left and right hemisphere using measurements of skull (LeMay, 1977), whole brain from autopsy (Geschwind & Levitsky, 1978; Rubens, Mahowald, & Hutton, 1976), arteriograms (LeMay & Culebras, 1972; Hochberg & LeMay, 1975; Ratcliff, Dila, Taylor, & Milner, 1980), pneumoencephalograms and ventriculograms (McRae, Branch, & Milner, 1968), and CT scan (LeMay & Kido, 1978). Some of these studies have separated the measurements based on the patient's handedness (LeMay & Culebras, 1972; LeMay & Kido, 1978) finding asymmetries to be less marked in left-handers. The asymmetries demonstrated in most of these studies have been associated with areas related to language and include longer left planum temporale (Geschwind & Levitsky, 1968) and larger left parietal operculum marked by less angulation of the left vs. right sylvian fissure (Rubens et al., 1976). However, individual subjects do demonstrate dissociation between morphologic asymmetry and behavioral asymmetry suggesting the relationship is not directly causal. There is also considerable variability of these neuroradiologic asymmetries in normal right-handers.

Radiological asymmetries have been reported in only one crossed aphasia patient. LeMay and Culebras (1972) report a case of a right-handed patient with aphasia secondary to right-hemisphere damage whose measures of asymmetry from arteriogram were not typical of right-handers. These results are suggestive of atypical or reduced asymmetry, but we need to know the relationship between the behavioral deficits and the anatomical asymmetries. Do crossed aphasic patients perform similarly to patients with uncrossed aphasia with similar lesions

and, more importantly, if a patient appears to be right-hemisphere dominant by behavioral criteria, are that patient's radiological symmetries atypical?

The purposes of this case presentation are (1) to describe the speech and language, visuospatial, psychometric intelligence, memory, and motor deficits in an individual with crossed aphasia, using primarily standardized tests, and (2) to compare hemispheric asymmetries from CT scan in a crossed aphasic patient with normative data in the literature.

### CASE REPORT

V.B. is a 67-year-old right-handed female executive secretary who had a syncopal episode and possibly a focal seizure with tonic-clonic movements on the left. On admission, the patient had a very mild left hyperreflexia, bilateral carotid bruits, and bilateral supraclavicular bruits. Angiography indicated an ulcerative plaque in the right internal carotid artery. After endarterectomy, the patient had a dense left hemiplegia and speech difficulties. She recovered gradually and at the four-month followup, her paresis was almost imperceptible.

The patient was evaluated by neuropsychology and speech pathology approximately 2, 9, and 13 weeks post-stroke. Perfunctory analysis of auditory comprehension, spontaneous speech, and repetition was done 8 months post-stroke. See Table 1 for behavioral tests administered. Data are provided from initial evaluation, but the focus of this report

TABLE 1  
TESTS ADMINISTERED

	Measures	Normative data
<b>A. Handedness</b>		
Oldfield Questionnaire (Oldfield, 1971)	Self-report	Normals
<b>B. Speech and language skills</b>		
Minnesota Test for the Differential Diagnosis of Aphasia (MTDDA) (Schuell, 1973)	Auditory comprehension, speech, visuomotor tasks	Aphasic patients, normals
Part of Boston Diagnostic Examination of Aphasia (Goodglass & Kaplan, 1972)	Spontaneous speech and repetition	Aphasic patients
Word Fluency (Borkowski, Benton, & Spreen, 1967)	Number of words said in 1 min beginning with s, c, p, t	Aphasic patients, normals
Boston Naming (Goodglass & Kaplan, 1978)	Name 85 pictures with phonemic and/or semantic cues	Normal males
Token Test (DeRenzi & Vignolo, 1962)	Auditory comprehension at various levels of complexity	Aphasic patients, normals

TABLE 1 (*continued*)

	Measures	Normative data
Verbal Section, Wechsler Adult Intelligence Scale (WAIS) (Wechsler, 1955)	Verbal responses to questions of general information, knowledge of social conventions, verbal categorization, digit span, vocabulary	Normals
Verbal Sections, Wechsler Memory Scale (Wechsler, 1945)	Verbal responses regarding current events, orientation, overlearned sequences, memory for paragraphs, word pairs and digit span	Normals
C. Arithmetic skills		
Arithmetic subtest, WAIS	Oral arithmetic with sections added to study impact of memory for problem, numeric manipulation, conceptualization of problem, and numeric manipulation skills	Normals
Arithmetic section, MTDDA	Written arithmetic	Aphasic patients, normals
D. Visuospatial skills		
Performance section, WAIS	Rapid symbol copying, identification of missing picture parts, block design, puzzle construction and arrangement of pictures in story sequence; memory for number-symbol associations of symbol copying task	Normals
Rey-Osterrieth form copying (Lezak, 1976)	Copy complex figure and draw 40 min after presentation using a different-colored pencil every 60 sec (Kaplan, personal communication)	Normals
E. Motor tests		
Finger tapping (Matthews & Klove, 1964)	Mean number of taps for right and left hand on 5 10-sec trials	Normals
Grip strength	Maximum strength on dynamometer in two trials with each hand	Normals
Grooved pegboard	Time to place 25 pegs in 25 notched holes with each hand	Normals
Limb apraxia (Haaland, Porch, & Delaney, 1980)	Fifteen imitations of nonrepresentational and representational movements	Normals

will be on the later evaluations, since there have been reports of diminished blood flow in the undamaged hemisphere within 3 weeks of stroke.

CT scan was performed on a Delta 20-20 Scanner 15 days after stroke and 8 months after stroke. See Fig. 1 for the CT scan performed 8 months after stroke which indicated infarction was in the white matter deep to the right supramarginal gyrus with no evidence of damage in the left hemisphere.

The CT scans were used to specify area of infarction and to measure hemispheric asymmetries. Four measurements were taken: frontal width and length (petalia) and occipital width and length (petalia) using published techniques (LeMay & Kido, 1978) further developed by Koff, Pieniadz, and Naeser and currently in use at the Aphasia Research Center, Boston Veterans Administration Medical Center (Koff, Naeser, Foundas, & Pieniadz, in preparation; Pieniadz, Naeser, Koff, & Levine, 1979; Naeser, Levine, Benson, Stuss, & Weir, 1981). All of the measurements for this case were done by Naeser's group. The frontal measures were taken on the lowest slice where the frontal horns were well shaped (butterfly shaped), above the sphenoid wing, and on three additional slices on which the frontal lobes were visualized. The occipital measurements were taken on the first slice above the tentorium. A millimeter ruler was used to make the width measurements. For the frontal measurements, the ruler was moved from the frontal pole posteriorly perpendicular to the interhemispheric fissure. When either the right or left inner table of the skull measured 10 mm from the midline interhemispheric fissure, right and left frontal measurements were taken. The same procedure was followed for the occipital measurements except the ruler was moved from the occipital pole anteriorly. Width differences of less than 1 mm were considered equal.

For the occipital and frontal length measurements, a clear plastic polar coordinate template was placed over the CT scan. The concentric circles on the template permitted visualization of the curved inner table of the skull both frontally and occipitally. If one occipital or frontal area reached one of the concentric circles before the other, the first was considered longer even if it was by less than 1 mm. For all width and length measurements, it was necessary to use scans imaged with bone windows so that the inner table of the skull could be clearly visualized.

Observations regarding the relative height of the sylvian fissures and the position of the glomi in the lateral ventricles were also made by Naeser.

## RESULTS

### *I. Behavioral Tests*

*A. Handedness.* All items on the Edinburgh Handedness Questionnaire (Oldfield, 1971) were reported as done with the right hand, and there

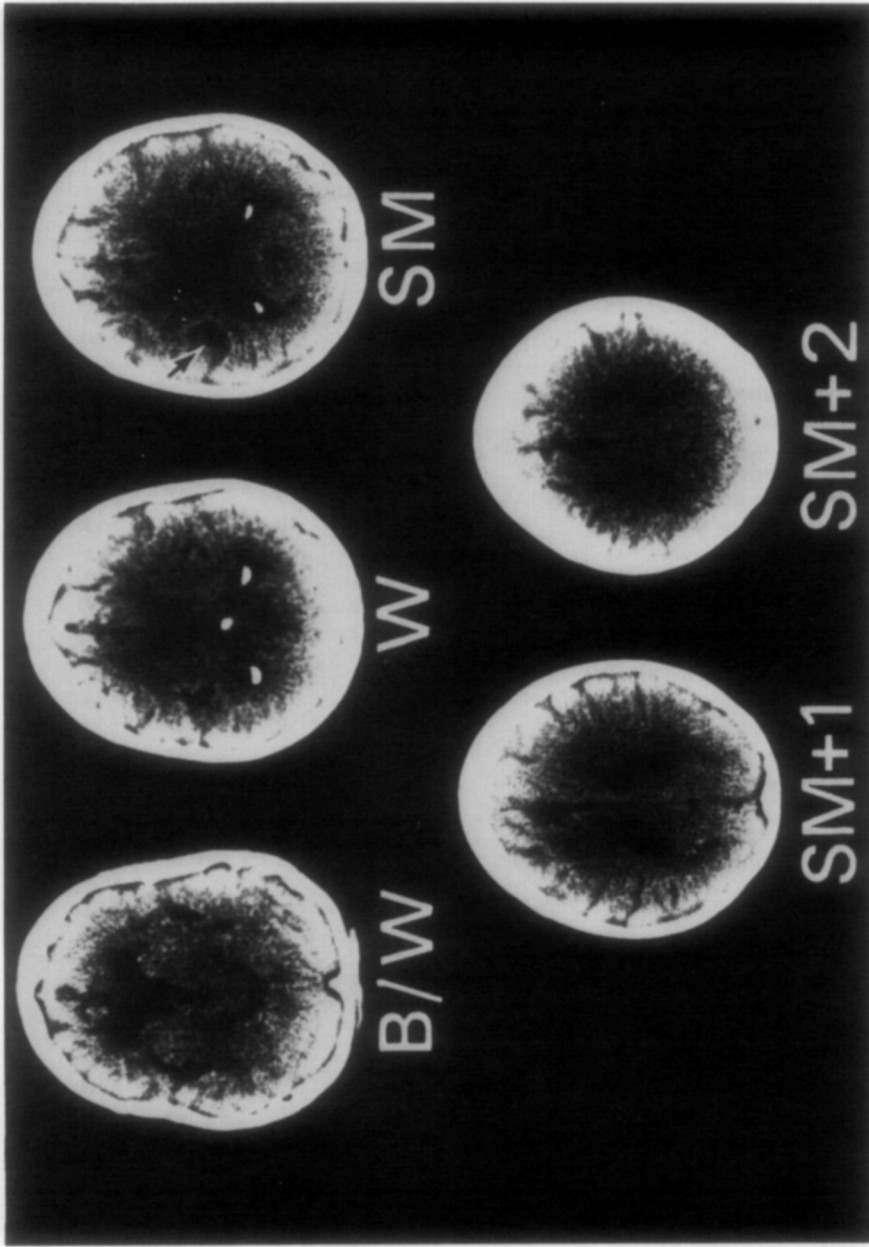


FIG. 1. CT scan sections obtained 8 months post-stroke. The right hemisphere is on the left. Labels refer to Naeser and Hayward's system (1978). B/W refers to Broca's/Wernicke's slice, SM to supramarginal gyrus slice, and SM + 1 and SM + 2 refer to one and two slices higher than the supramarginal slice. The infarct is seen primarily on slice SM, deep to the more anterior portion of the right supramarginal gyrus (see arrow). There is some minimal inferior lesion extension into the right planum temporale at slice W.

was no report of familial left-handedness. Childhood head injury or early use of the left hand was denied by the patient.

*B. Speech and language.* V.B. had greatest difficulty on tasks which required vocal output whether spontaneous, repeated, or read, and whether verbal or nonverbal (see Tables 2 and 3). Initially, she preferred to answer questions with a verbal "yes" or "no" or to write answers.

TABLE 2  
V.B.'s ERRORS ON THE MINNESOTA TEST FOR THE DIFFERENTIAL DIAGNOSIS OF APHASIA  
(SCHUELL, 1973)<sup>a</sup>

Tests	Post-CVA			Normals	
	2-3 weeks	10-11 weeks	16 weeks	Mean	SD
<b>A. Auditory disturbances</b>					
1. Recognizing common words	0	0	0	.00	.00
2. Discriminating between paired words	1	0	0	.13	.30
3. Recognizing letters	0	0	0	.00	.00
4. Identifying items named serially	0	0	0	.02	.14
5. Understanding sentences	2	0	0	.17	.38
6. Following directions	1	0	0	.02	.14
7. Understanding a paragraph	1	0	0	.42	.92
8. Repeating digits	2	0	1	.50	.71
9. Repeating sentences	2	0	0	.10	.36
<b>B. Visual and reading disturbances</b>					
1. Matching forms	0	0	0	.00	.00
2. Matching letters	0	0	0	.00	.00
3. Matching words to pictures	0	0	0	.00	.00
4. Matching printed to spoken words	0	1	0	.00	.00
5. Reading comprehension, sentences	2	0	1	.10	.30
6. Reading rate, sentences	0	0	0	.38	.70
7. Reading comprehension, paragraph	5	2	2	1.86	1.55
8. Oral reading, words	3	0	0	.08	.44
9. Oral reading, sentences	5	2	.5	.10	.44
<b>C. Speech and language disturbances</b>					
1. Imitating gross movements	2	0	1	.00	.00
2. Rapid alternating movements	5	3	4	.00	.00
3. Repeating monosyllables	4	0	1	.08	.31
4. Repeating phrases	7	1	1	.04	.20
5. Counting to 20	0	0	0	.00	.00
6. Naming days of week	0	0	0	.00	.00
7. Completing sentences	0	0	0	.00	.00
8. Answering simple questions	0	0	0	.00	.00
9. Giving biographical information	0	0	0	.00	.00
10. Expressing ideas	2	3	0	.02	.14
11. Producing sentences	1	0	0	.00	.00
12. Describing picture	2	0	0	.00	.00
13. Naming pictures	2.5	0	0	.00	.00
14. Defining words	3	2.5	2.5	.60	1.07
15. Retelling paragraph	2	0	4	.74	1.31

TABLE 2  
(continued)

Tests	Post-CVA			Normals	
	2-3 weeks	10-11 weeks	16 weeks	Mean	SD
D. Visuomotor and writing disturbances					
1. Copying Greek letters	1	0	0	.02	.14
2. Writing numbers	0	0	0	.00	.00
3. Reproducing wheel	3	1	3	.16	.47
4. Reproducing letters	0	0	0	.02	.14
5. Writing letters to dictation	1	0	0	.08	.27
6. Written spelling	2	0	0	.76	1.56
7. Oral spelling	7	2	1	.62	1.46
8. Producing written sentences	4	1	2	.52	.93
9. Writing sentences to dictation	4	2	1	.80	.64
10. Writing a paragraph	2	0	0	.26	.72
E. Disturbances of numerical relations and arithmetic processes					
1. Making change	0	0	0	.00	.00
2. Setting clock	4	0	0	.02	.14
3. Simple numerical combinations	1	1	0	.12	.44
4. Written problems (set up)	2	2	3	.36	.55

TABLE 3  
WECHSLER ADULT INTELLIGENCE SCALE<sup>a</sup>

	Post-CVA			Normals	
	2 weeks	9 weeks	13 weeks	Mean	SD
Verbal					
Information	11	11		10	3
Comprehension	8	11		10	3
Arithmetic	5	10		10	3
Similarities	12	9	13	10	3
Digit span	8	9	11	10	3
Vocabulary	12			10	3
Verbal IQ	96	97		100	15
Performance					
Digit symbol	11	13		10	3
Picture completion	11	16		10	3
Block design	7	8	11	10	3
Picture arrangement	11	14		10	3
Object assembly	7	9		10	3
Performance IQ	99	109		100	15
Full scale IQ	98	102		100	15

<sup>a</sup> Age scale scores.



However, even at this time, when coaxed to respond verbally, her speech was not telegraphic. Speech was hesitant and marked by pauses which were related to word finding difficulties. Grammatical form and phrase length was generally within normal limits. However, she made occasional sequencing errors in speaking and writing (e.g., "I'll put on my old, but serviceably still coat," "If I throw at you this paper, it won't hurt you").

At 16 weeks post-stroke V.B.'s description of Schuell's card (1973) C-12 was marked by semantic paraphasias (e.g., town for farmhouse), unfilled pauses and self-corrections:

there's a duck in the *swa* . . . pond and there's smoke coming out of the chinney.  
 . . . It's probably a *uh town no uh a farmhouse* . . .

Eight months post-stroke, V.B. described the cookie theft picture from the Boston Diagnostic Aphasia Examination (BDAE) with similar errors except repetition of initial phonemes was more apparent:

. . . the sink is overrunning . . . the boy is *st standing* on is *g gonna* topple over . . .

No naming deficits were noted on confrontation on the Minnesota Test, and at 9 weeks post-CVA percentage correct responses on the Boston Naming Test was within normal limits (83%), improved from 68% 2 weeks post-CVA. Performance was characterized by word searching behavior and pauses, semantic paraphasias (e.g., "squash" for asparagus), phonemic paraphasias (e.g., "sethoscope" for stethoscope, "candlelabial" for candelabra), self-corrections (e.g., "hatband, no, visor" for visor), and long delays. All of these errors occurred on all evaluations but were less frequent at 9 and 13 weeks post-CVA. Word fluency was also evaluated and performance was about halfway between the performance of an aphasic group (mean = 15.2, *SD* = 16) and a normal control group (mean = 44.3, *SD* = 26.1) (Wertz, Keith, & Custer, 1971).

Initially V.B. had difficulty repeating even single words. By 8 weeks post-stroke repetition of single words on the MTDDA was generally errorless, but sentence repetition was still impaired (e.g., "no *if*, ands or buts" for no ifs, ands or buts). Eight months post-stroke, she correctly repeated 6/8 high-probability and 4/8 low-probability sentences from the BDAE (e.g., "down to *urs*" for down to earth; "The lawyer's closing argu— convince— him" for The lawyer's closing argument convinced him). Errors were primarily at the end of words and in the latter sentence did not include the word root ("argu" for argument; "convince" for convinced). Her performance on spontaneous speech and sentence repetition of the BDAE was not inconsistent qualitatively from other reported cases of conduction aphasia (Goodglass & Kaplan, 1972).

Auditory comprehension skills were not impaired relative to controls, but, when more bits of information were presented on the Minnesota and Token Tests, errors increased. On the Token Test, V.B. made one error on the first 40 commands. On Part V, which consists of highly complex two-part commands (e.g., Before touching the yellow circle, pick up the red rectangle), she made five errors, which is not more than one standard deviation below the normal control group (age 65–69) (Wertz et al., 1971). Errors decreased to three, 10 weeks post-CVA. Reading comprehension skills were also not significantly impaired at 10 weeks post-CVA.

Writing errors were similar to speech errors except that there was frequent perseveration of looped letters (e.g., “mm” for m or “ll” for l). The relatively greater impairment of verbal vs. written output can be seen by the greater impairment of oral vs written spelling (Table 2). Graphic copying of linguistic material (e.g., numbers, letters) was not significantly impaired, but copying of words or sentences was not evaluated. Writing errors were present whether V.B. wrote sentences spontaneously or to dictation.

Expressive language impairment (particularly word-finding and word-sequencing difficulties) affected V.B.’s performance on the verbal section of the WAIS. Performance on verbal categorization and overlearned tasks such as general information and vocabulary were within normal limits. However, ability to verbally express appropriate social responses and repeat digit sequences were mildly impaired. Performance on all of these tests was within normal limits by the 9-week post-CVA test date.

Verbal Memory Skills were evaluated only at 9 weeks post-CVA and V.B.’s performance was within normal limits on all tests administered. This included performance on a focused concentration task requiring verbal recitation of Serial 3’s and a task requiring spontaneous recall of details from a paragraph.

*C. Arithmetic skills.* Oral arithmetic deficits decreased somewhat when V.B. was allowed to read the question rather than merely hear it. Further improvement was noted when she was given paper to set up and compute the calculation, and an additional correct response was obtained when the only incorrect problem was set up by the examiner. These results suggest that arithmetic deficits were associated with impairment of (1) language comprehension and/or memory, (2) numeric manipulation skills, and (3) conceptualization of the problem’s solution. On the numeric section of the Minnesota test, V.B. was able to add and subtract two-but not three-integer problems, and she could not solve any multiplication or division problems if two integers were involved. Errors were characterized as calculation errors, difficulty carrying numbers from one column to the next, some confusion with columnar organization, and poor understanding of even the most basic principles of long division.

These deficits improved significantly from 9 to 13 weeks post-stroke; errors at 13 weeks were associated with difficulty carrying and maintaining columnar organization and confusing an addition sign for a multiplication sign.

*D. Visuospatial skills.* Visuospatial deficits were noted on the Minnesota test (D3, E2, E4) at initial and follow-up testing. V.B. could not reproduce a wheel (D3) accurately at any time; she distorted the rim and did not intersect the spokes and the rim. Initially, on clock setting, she confused the long and the short hand, but no errors were made on follow-up. Visuospatial skills can also obviously affect writing and arithmetic performance which are described in previous sections. Scores on the Performance Section of the WAIS (see Table 3) further specified visuospatial deficits. While V.B.'s performance on rapid symbol copying and arranging pictures in story sequence was within normal limits, she demonstrated mild impairment on block design and puzzle construction tasks at 9 and 13 weeks post-CVA. On the Block Design subtest, she was able to specify when her constructions were incorrect. Some of her errors were similar to those seen with left- and some were similar to those seen with right-hemisphere damage (Goodglass & Kaplan, 1979). She made isolated orientation errors but did not always maintain the  $2 \times 2$  or  $3 \times 3$  matrix configuration of the design. Moreover, sometimes her performance improved when she was shown part of the design at a time, but sometimes it did not. Figure 2 illustrates V.B.'s copying skills on the Rey-Osterrieth figure. Although improvement was noted over the three testings, V.B. still demonstrated significant constructional difficulties even 13 weeks post-CVA. Deficits consisted of impaired organization of the drawing and poor integration of individual parts. She frequently repeated parts of the design and initially began on the right, rather than on the left side of the page.

On the Wechsler Memory Scale, administered 9 weeks post-stroke, immediate memory for figures on the Visual Reproduction Subtest was not impaired for her age. When retention was tested 30 min after presentation, she remembered only 25% of the visual details compared to recalling 88% and 53% of the details from two verbal memory tasks. She was able, however, to identify 50% of the pictures when given five possibilities to choose. When asked to recall number-symbol associations immediately after presentation on the Digit Symbol subtest, she recalled only 50%.

*E. Motor skills.* Only right-sided performance was evaluated at initial testing with mild impairment of grip and dexterity, but average finger-tapping skills. This pattern continued at 13 weeks with dexterity skills within the average range by 3 months post-CVA. Left-sided performance on all motor tasks was moderately to severely impaired at 13 weeks and 3 months post-CVA.

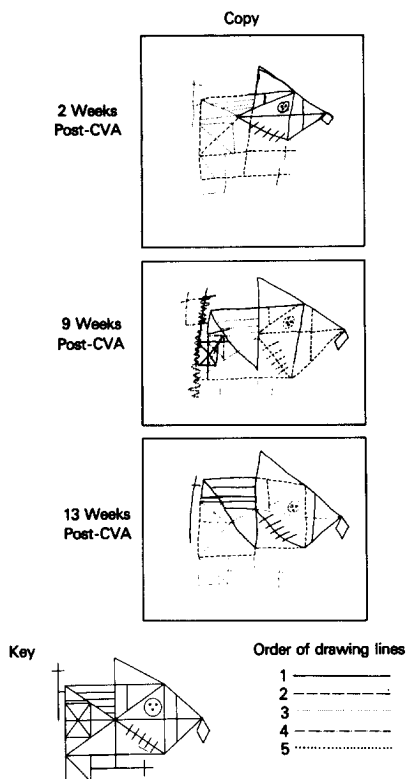


FIG. 2. V.B.'s Rey-Osterrieth figures from direct copy at three different times after stroke. The different types of line indicate the part of the figure V.B. drew in the first, second, etc., 60-sec periods.

No significant limb apraxia was noted to imitation of representational or nonrepresentational movements on either the left or right arm. She made errors on 3/15 trials, and errors were characterized by orientation and target errors with no body part as object errors.

## II. CT Scan Asymmetry Measures

Frontal measures were made on slice B/W (see Fig. 1) and on three additional frontal slices. In three out of four slices (including B/W), frontal measures were wider on the left than the right, and longer on the right than the left. On the lowest slice (two slices below B/W), the widths and lengths were equal. Greater right occipital width and length were observed on slice W (see Figs. 3 and 4). In addition, slice W from V.B.'s first scan (15 days post-stroke) revealed a lower right vs. left sylvian fissure, and a more posterior right choroid plexus than left. (Fig. 5). The lower right sylvian fissure may be compatible with right-hemisphere dominance since a *lower* sylvian fissure is more commonly

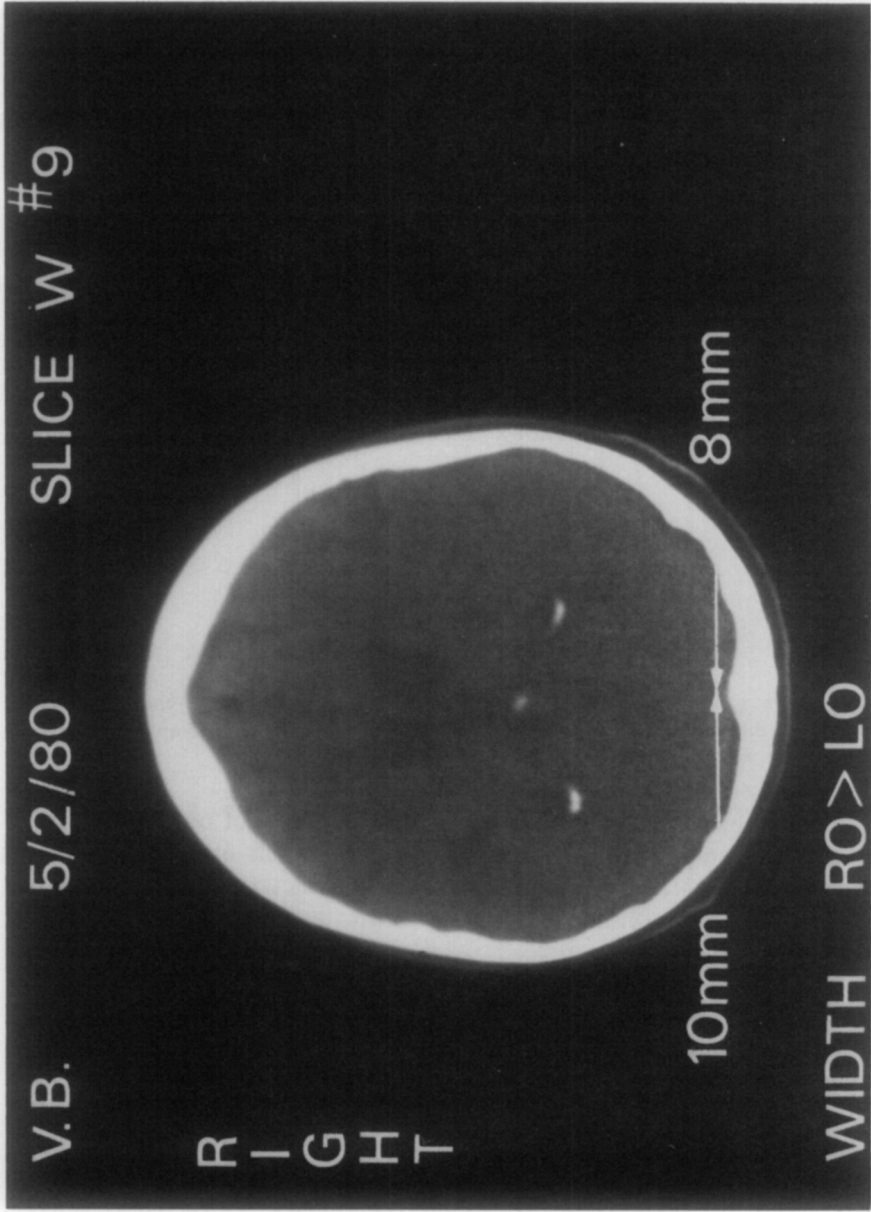


FIG. 3. Width of occipital areas on CT scan slice W, 8 months post-stroke. The right occipital width is greater than the left.

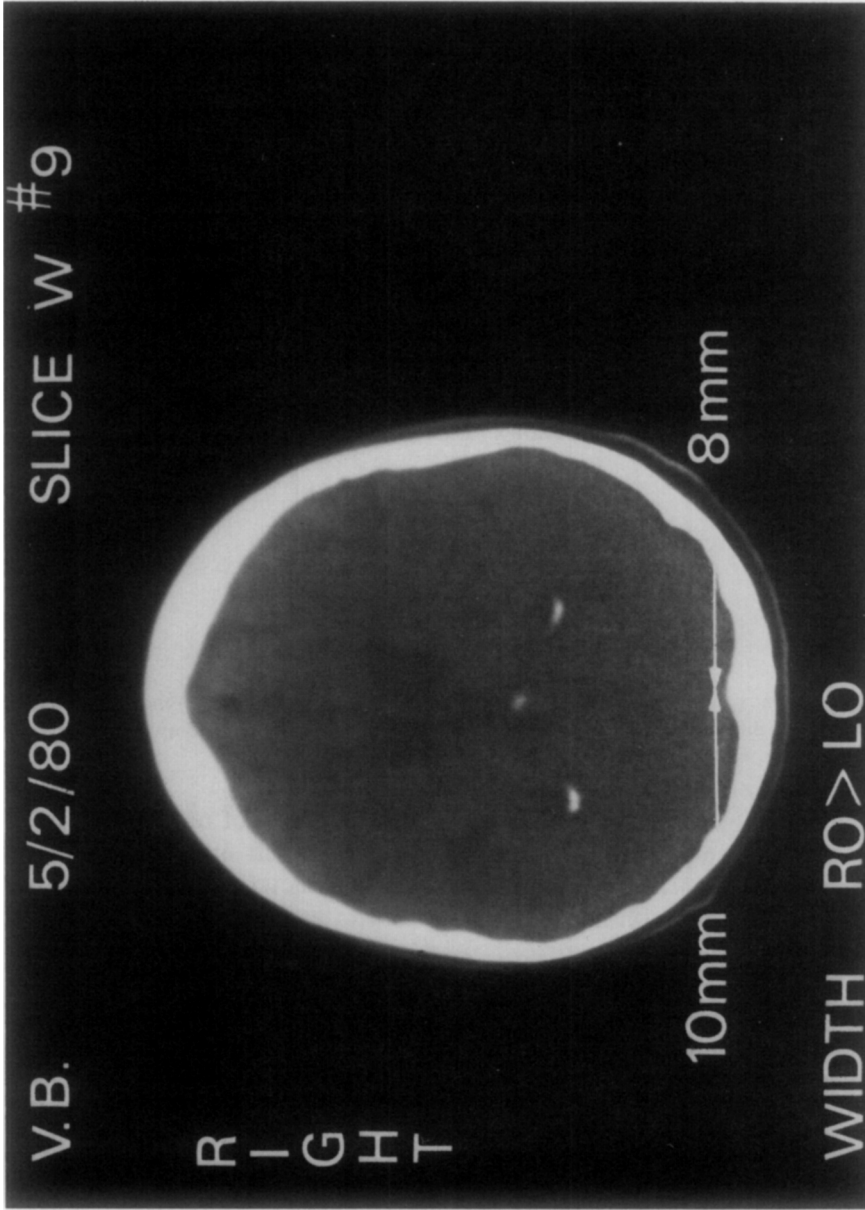


FIG. 4. The same CT scan section used in Fig. 3 is used to measure the relative lengths of the right and left occipital regions. An increased right occipital length (petalia) is demonstrated.

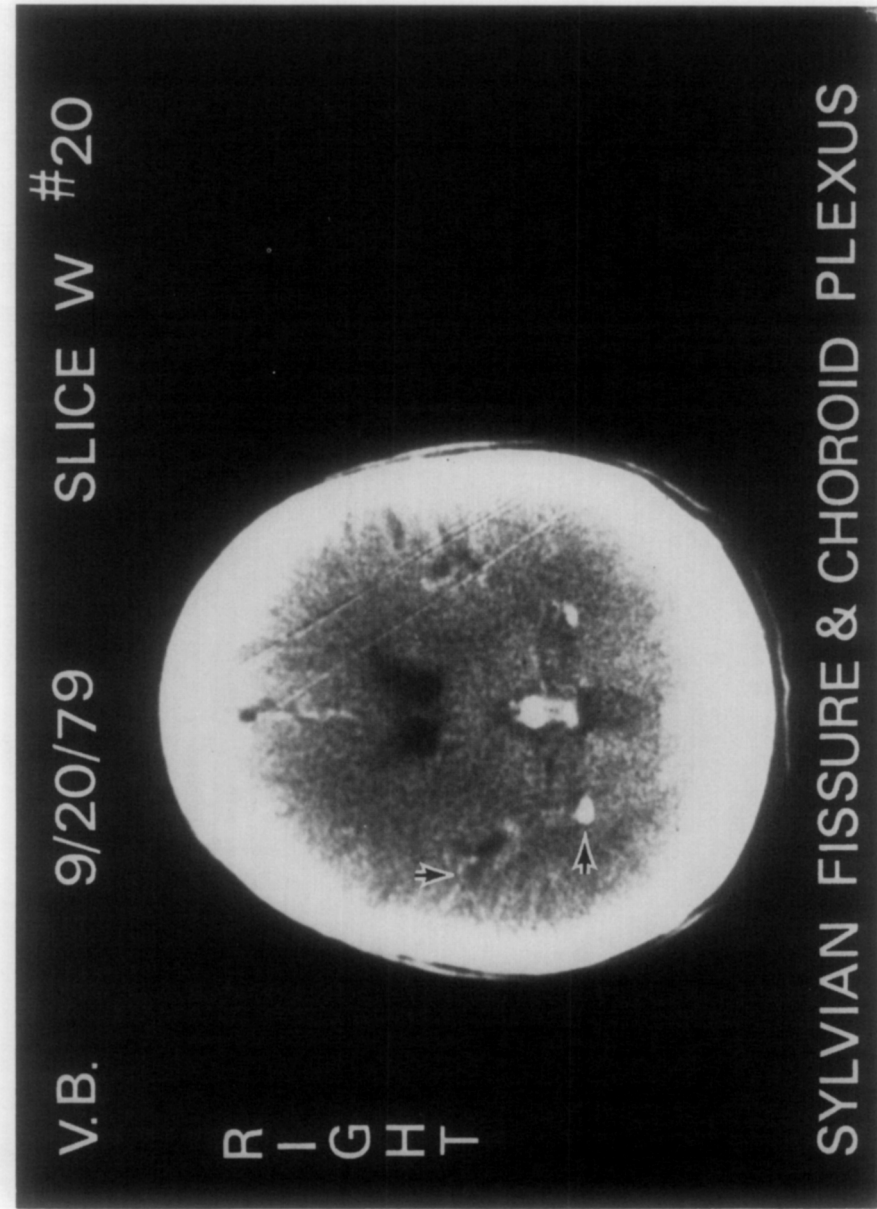


FIG. 5. Slice through the frontal and occipital horns (slice W) from CT scan taken 15 days post-stroke. The right sylvian fissure is lower than the left, and the right choroid plexus is more posterior than the left (see arrows).

observed on the *left*. The more posterior right calcified glomus may be compatible with a larger right thalamus (LeMay, personal communication).

### COMMENT

The test results from 2 weeks post-stroke will not be discussed since they may be associated with left as well as right-hemisphere dysfunction. Diminished cerebral blood flow has been reported in both hemispheres after unilateral stroke with maximum reductions seen in the undamaged hemisphere 1 week after stroke (Reivich, Ginsberg, Slater, Jones, Lovach, Greenberg, & Goldberg, 1978). Since the purpose of this case is to study the effect of right hemisphere damage alone, early data will not be discussed in detail.

Qualitatively, our patient's performance on speech and language tests is similar to that of patients with conduction aphasia as a result of lesions of the supramarginal area in the left hemisphere (Goodglass & Kaplan; 1979, Naeser & Hayward, 1978; Benson, Sheremata, Bouchard, et al., 1973; Geschwind, 1965). She also showed visuospatial deficits. She demonstrated intact auditory comprehension and impaired sentence repetition characterized by phonemic and semantic paraphasias. There was no evidence of articulatory groping or telegraphic speech commonly seen in nonfluent aphasic patients.

To fit the pattern of conduction aphasia, the patient must demonstrate intact comprehension and articulatory agility, but impaired repetition. At both 4 and 8 months post-stroke, V.B. demonstrated repetition deficits, but no significant impairment of spontaneous speech.

Using the classic descriptions of aphasia, one would not expect to see comprehension deficits after suprasylvian lesion. Comprehension deficits have been demonstrated in suprasylvian, infrarolandic lesions. However, the lesions in these patients were cortical rather than strictly subcortical and larger than in our case (Mohr, Pessin, Finkelstein, Duncan, & Davis, 1978).

If this patient's hemispheric dominance was completely bilateral, one would expect lesser deficits than seen in unilaterally dominant individuals. This does not appear to be the case. V.B. also continued to demonstrate the same pattern of deficits at 8-months post-stroke as at 9 weeks post-stroke.

This patient does not fit the description of crossed aphasia in a dextral emphasized by Brown and Hecaen (1976). She is older than the typical crossed aphasic patient, her speech was not telegraphic, comprehension was not moderately impaired, and repetition and naming were impaired, characterized by some phonemic paraphasias. Like their summary of the crossed aphasic patient, our patient's writing was superior to speech, and limb apraxia tested to imitation was not present.

Brown and Hecaen (1976) have suggested that the pattern of language



deficits seen in crossed aphasia is similar to that seen in children and left-handers whose hemispheric dominance is incomplete. However, when one looks at many of these individual cases, the pattern of deficits and abilities in the reported dextral crossed aphasic patients is not as similar as they suggest. In many cases, lesion locus is not well enough specified to allow comparison of crossed aphasia cases vs. noncrossed aphasia cases with similar lesion sites.

Many of the crossed aphasia studies in dextrals have reported visuospatial deficits. These deficits are reflected in our case by her scores and errors on all visuoconstructive tasks (for example, block design, wheel reproduction, Rey-Osterrieth figure copying, arithmetic calculations and writing). Her deficits were typically a combination of those associated with "dominant" and "nondominant" hemisphere damage in right-handers. For example, on the Block Design subtest of the WAIS, she made errors in (1) the orientation of single blocks, which has been described after left hemisphere damage, and (2) the external configuration of the blocks which has been reported after right-hemisphere damage (Goodglass & Kaplan, 1979). Errors on the Rey-Osterrieth (Fig. 2) were more typical of those reported clinically after right-hemisphere damage characterized by starting on the right, repeating parts of the design, and decreased ability to orient the parts of the design to each other. She also demonstrated atypical organization of the design, best fitting the strategy described by Rey where the subject copies discrete parts of the drawing without any semblance of organization. This pattern was never seen in normal adults or children past the age of 7 (Lezak, 1976). However, differential patterns of errors on the Rey figure have not been described in right-handers with left- vs. right-hemisphere damage.

The writing errors were associated both with visuospatial and language deficits. The visuospatial component was illustrated by V.B.'s tendency to repeat looped letters (e.g., mm for m; ll for l), which has been reported in patients with right-hemisphere damage but no language deficits (Hecaen & Sanguet, 1971). The language component was illustrated by occasional paraphasias and sequencing errors detailed in the results.

Calculation difficulty has been associated with alexia and agraphia for numbers, spatial disorganization of numbers, or general cognitive deterioration (Grewel, 1969; Levin, 1979). In this case, arithmetic errors were primarily associated with visuospatial deficits characterized by misalignment of numbers and difficulty carrying over digits. There was better performance with single-integer problems, and there was substitution of one operation for another (+ for  $\times$ ). Despite relative improvement on the oral arithmetic subtest of the WAIS from an age scale score of 5 to 10 at 3 to 9 weeks post-CVA, V.B. continued to demonstrate deficits in written calculations. Relatively intact oral calculation with impaired written calculation has been associated with acalculia of the

spatial type (Levin, 1979). In support of this observation, V.B. demonstrated no number dysgraphia or anarithmetria which has been associated with arithmetic difficulties secondary to left-hemisphere damage. Numeric dyslexia was not directly evaluated. It did not appear to be a significant problem, however, because she could perform written problems with single integers.

Lesion of the arcuate fasciculus in the dominant (usually left) hemisphere has been reported to produce ideomotor limb apraxia (Geschwind, 1965). Heilman, Coyle, Gonyea, and Geschwind (1973) have demonstrated ideomotor limb apraxia without aphasia in a left-handed patient with right-hemisphere damage. V.B. may be a limited example of the dissociation between limb apraxia and aphasia because, although she exhibited no limb apraxia to imitation, she did exhibit an aphasia. This is unusual with documented arcuate fasciculus lesion deep to supramarginal gyrus. Three cases have been reported (Benson et al., 1973) with perisylvian damage of the dominant hemisphere and conduction aphasia. The two patients with suprasylvian damage in the white matter of the parietal operculum, like V.B., demonstrated limb apraxia while the patient with infrasyllian damage did not. Since V.B. has suprasylvian damage only, the pattern of her results suggests she demonstrates relative right-hemisphere dominance for language, but left-hemisphere dominance for imitation of motor movement. This has been reported in most cases of crossed aphasia (Brown & Hecaen, 1976). Based on these findings, it seems reasonable to suggest that the hemisphere contralateral to the preferred hand (regardless of language dominance) is most often dominant for complex motor control. This also supports the contention that limb apraxia is not a manifestation of a general deficit in symbolic thought but is more specific to motor skills (DeRenzi, Motti, & Nichelli, 1980).

With the exception of limb praxis, this case demonstrates a pattern of speech, language, and visuospatial deficits which is suggestive of right-hemisphere dominance for all aspects of the neuropsychological functions which were measured. The behavioral data reflect performance deficits which have been reported after right- and after left-hemisphere damage in right-handers. At this point, there are not enough standardized recovery data in the literature to definitively say that V.B.'s recovery is the same or different from a patient with lateralized hemispheric dominance. However, her pattern of performance is similar enough to that of conduction aphasic patients due to left-hemispheric lesion and to that of patients with visuospatial deficits due to right parietal damage to suggest her right hemisphere is dominant for both language and visuospatial functions.

The CT scan asymmetry data may be consistent with the behavioral findings because five out of six of the asymmetry measures noted below were "atypical" for right-handed females (LeMay, 1977). V.B.'s pattern

of CT scan asymmetry is "atypical" when compared to female right-handers and more "typical" for the pattern described for female left-handers. Her scans indicated the following atypical asymmetries: (1) Left frontal width was greater than right frontal width, (2) and (3) right occipital width and length were greater than left occipital width and length, (4) the right sylvian fissure was lower than the left, and (5) the right calcified glomus was more posterior than the left. The only "typical" asymmetry for a right-handed female was that the right frontal length was greater than the left frontal length.

This is the first study to correlate crossed aphasia in a dextral with CT scan hemispheric asymmetry measurements. In view of the unusual behavioral *and* hemispheric asymmetry findings, it is recommended that future studies with crossed aphasia in dextrals do both detailed language and visuospatial testing as well as careful CT scan hemispheric asymmetry measurements. It is possible that patients with unusual or atypical hemispheric asymmetries can become aphasic and/or have a limb apraxia from lesions in *either* hemisphere. Recent research by Pieniadz et al. (1979) has shown that right-handed global aphasics with large left hemisphere lesions who have "atypical" CT scan asymmetries (right occipital widths) have better recovery than those global aphasics with "typical" asymmetry measurements. It is possible this right-handed aphasic with "atypical" asymmetries could also have become aphasic and/or had a limb apraxia from a left-hemisphere lesion and also had better recovery. It is recommended that aphasia cases with "atypical" hemispheric asymmetries (especially right occipital width and length) be studied more closely both for (1) incidence of aphasia and limb apraxia with right or left-hemisphere lesions and (2) *recovery* from aphasia and/or limb apraxia.

## REFERENCES

- Benson, D. F., Sheremata, W. A., Bouchard, R., et al. 1973. Conduction Aphasia: A clinicopathological study. *Archives of Neurology*, **28**, 339-346.
- Borkowski, J. G., Benton, A. L., & Spreen, O. 1967. Word fluency and brain damage. *Brain*, **90**, 501-510.
- Brown, J. W., & Hecaen, H. 1976. Lateralization and language representation. *Neurology*, **26**, 183-189.
- DeRenzi, E., Motti, F., & Nichelli, P. 1980. Imitating gestures: A quantitative approach to ideomotor apraxia. *Archives of Neurology*, **37**, 6-10.
- DeRenzi, E., & Vignolo, L. A. 1962. The Token Test: A sensitive test to detect receptive disturbances in aphasics. *Brain*, **85**, 665-678.
- Foroglou, G., Assal, G., & Zander, E. 1975. Une nouvelle observation d'aphasie croisee chez un droitier. *Archives Swisses Neurologique Psychiatrique*, **117**, 205-210.
- Geschwind, N. 1965. Disconnexion syndromes in animals and man. *Brain*, **88**, 585-644.
- Geschwind, N., & Levitsky, W. 1968. Left/right asymmetries in temporal speech region. *Science*, **161**, 186-187.
- Gloning, I., Gloning, K., Haub, G., & Quatember, R. 1969. Comparison of verbal behavior in right-handed and non-right-handed patients with anatomically verified lesions of one hemisphere. *Cortex*, **5**, 43-52.

- Goodglass, H., & Kaplan, E. 1972. *The Assessment of Aphasia and Related Disorders*. Philadelphia: Lea & Febiger.
- Goodglass, H., & Kaplan, E. 1978. *The Boston Naming Test*. Boston: The Boston Univ. Trustees.
- Goodglass, H., & Kaplan, E. 1979. Assessment of cognitive deficit in the brain-injured patient. In M. S. Gazzaniga (Ed.), *The Handbook of Behavioral Neurobiology: Neuropsychology*. New York: Plenum.
- Grewel, F. 1969. The acalculias. In P. J. Vincken, & G. W. Bruyn (Eds.); *Handbook of Clinical Neurology: Disorders of Speech, Perception and Symbolic Behavior*. New York: Wiley.
- Haaland, K. Y., Porch, B. E., & Delaney, H. D. 1980. Limb apraxia and motor performance. *Brain and Language*, **9**, 315-323.
- Hecaen, H., Mazars, G., Ramier, A., et al. 1971. Aphasie croisee chez un sujet droiter bilingue. *Revue Neurologique*, **124**, 319-323.
- Hecaen, H., & Sanguet, J. 1971. Cerebral dominance in left-handed subjects. *Cortex*, **7**, 19-48.
- Heilman, K. M., Coyle, J. M., Gonyea, E. F., & Geschwind, N. 1973. Apraxia and agraphia in a left hander. *Brain*, **96**, 21-28.
- Hochberg, F. H., & LeMay, M. 1975. Arteriographic correlates of handedness. *Neurology*, **25**, 218-222.
- Koff, E., Pieniadz, J. M., Naeser, M. A., York, A., Leimkuhler, E., & Foundas, A. Skull asymmetries and handedness in males and females. Manuscript in preparation.
- LeMay, M. 1977. Asymmetries of the skull and handedness. *Journal of Neurologic Science*, **32**, 243-253.
- LeMay, M., & Culebras, A. 1972. Human brain morphologic differences in the hemispheres demonstrable by carotid arteriography. *New England Journal of Medicine*, **287**, 168-170.
- LeMay, M., & Kido, D. K. 1978. Asymmetries of the cerebral hemispheres on computed tomograms. *Journal of Computer Assisted Tomography*, **2**, 471-476.
- Levin, H. 1979. In K. Heilman, & E. Valenstein (Eds.); *Clinical Neuropsychology*. New York: Oxford Univ. Press.
- Lezak, M. D. 1976. *Neuropsychological Assessment*. New York: Oxford Univ. Press.
- Matthews, C. G., & Klove, H. 1964. *Instruction Manual for the Adult Neuropsychology Test Battery*. Madison: Univ. of Wisconsin Medical School.
- McRae, D. L., Branch, D. L., & Milner, B. 1968. The occipital horns and cerebral dominance. *Neurology*, **18**, 95-98.
- Mohr, J. P., Pessin, M. S., Finkelstein, H. H., Duncan, G. W., & Davis, K. R. 1978. Broca aphasia: Pathologic and clinical. *Neurology*, **28**, 311-324.
- Naeser, M., & Hayward, W. 1978. Lesion localization in aphasia with cranial computed tomography and the Boston Diagnostic Aphasia Exam. *Neurology*, **28**, 545-551.
- Naeser, M. A., Levine, H. L., Benson, D. F., Stuss, D. T., & Weir, W. S. 1981. Frontal leucotomy size and hemispheric asymmetries on CT scans of schizophrenics with variable recovery. *Archives of Neurology*, **38**, 30-37.
- Oldfield, R. C. 1971. The assessment and analysis of handedness: The Edinburgh Inventory. *Neuropsychologia*, **9**, 97-113.
- Pieniadz, J. M., Naeser, M. A., Koff, E., & Levine, H. L. 1979. *CT scan cerebral hemispheric asymmetry measurements in stroke cases with global aphasia: Atypical asymmetries associated with improved recovery*. Paper presented to Academy of Aphasia Meeting, San Diego, CA.
- Ratcliff, G., Dila, C., Taylor, L., & Milner, B. 1980. The morphological asymmetry of the hemispheres and cerebral dominance for speech: A possible relationship. *Brain and Language*, **11**, 87-98.
- Reivich, M., Ginsberg, M., Slater, R., Jones, S., Lovach, A., Greenberg, J., & Goldberg,

- H. 1978. Alterations in regional cerebral hemodynamics and metabolism produced by focal cerebral ischemia. *European Neurologica*, **12**, 9-16.
- Rubens, A. B., Mahowald, M. W., & Hutton, J. T. 1976. Asymmetry of the lateral (sylvian) fissures in man. *Neurology*, **26**, 620-624.
- Russel, W. R., & Espir, M. L. E. 1961. *Traumatic Aphasia* (Case 27). London: Oxford Univ. Press.
- Schuell, H. 1973. *Differential Diagnosis of Aphasia with the Minnesota Test*. Minneapolis: Univ. of Minnesota Press.
- Urbain, E., Seron, X., Remits, A., et al. 1978. Aphasie croisee chez une droitier: A propos d'une observation, *Revue Neurologique*, **12**, 751-759.
- Wechsler, A. F. 1973. Crossed aphasia in an illiterate dextral. *Neurology*, **23**, 907-911.
- Wechsler, D. A. 1945. A standardized memory scale for clinical use. *Journal of Psychology*, **19**, 87-95.
- Wechsler, D. A. 1955. *The Wechsler Adult Intelligence Scale*. New York: The Psychological Corp.
- Wertz, R. T., Keith, R. L., & Custer, D. D. 1971. *Normal and aphasic behavior on a measure of auditory input and a measure of verbal output*. Presented at the American Speech and Hearing Association, Chicago.
- Zangwill, O. L. 1967. Speech and the minor hemisphere. *Acta Neurologica Psychiatrica Belgica*, **67**, 1013-1020.
- Zangwill, O. L. 1979. Two cases of crossed aphasia in dextrals. *Neuropsychologia*, **17**, 167-172.