

## Aphasia following a Right Thalamic Hemorrhage

ANDREW L. CHESSON, JR.

*Louisiana State University Medical Center and The Veterans  
Administration Medical Center, Shreveport*

A left-handed patient with a right thalamic hemorrhage and disordered speech is described. Sequential examinations and aphasia testing were done during a 1-year follow-up period and the results are reported. This case supports those authors who have described characteristics they feel are helpful in diagnosing disordered speech associated with thalamic lesions. Paucity of speech, reduced voice volume, anomia, some paraphasia, and severe dysgraphia were present, but comprehension and repetition were relatively preserved. She showed modest improvement with time. This case also confirms that thalamic involvement in speech is a dominant, rather than a specifically left hemispheric function.

### INTRODUCTION

The role of the thalamus in disorders of speech has been discussed and debated in the recent literature (Bugiani, Conforto, & Sacco, 1969; Cappa & Vignolo, 1979; Ciemins, 1968, 1970; Riklan & Cooper, 1975). Some authors feel the disordered speech may not represent a true aphasia. Thalamic lesions in association with disordered speech have been reported with tumors (Arseni, 1958; Cheek & Taveras, 1966; Smyth & Stern, 1938), abscesses (Panchal, Parikh, & Karapurkar, 1974), and vascular lesions (Bugiani, Conforto, & Sacco, 1969; Cappa & Vignolo, 1979; Ciemins, 1968, 1970; Fazio, Sacco, & Bugiani, 1973; Mohr, Watters, & Duncan, 1975; Reynolds, Harris, Ojemann et al., 1978; Reynolds, Turner, Harris et al., 1979). Vascular cases which have been well documented as limited to the thalamus have been hemorrhagic in nature (Ciemins, 1970; Samarel, Wright, Sergay et al., 1976), although the possibility of hemorrhagic infarction in two cases has been suggested (Mohr et al., 1975). Data regarding the role of the thalamus in speech has also been presented

The patient secretarial assistance of Nell Butts and Jerry Morse and the neuropsychological testing assistance performed by Pat Caskey and Ron Goebel, Ph.D., are acknowledged and appreciated. Please send requests for reprints to Dr. Andrew L. Chesson, Department of Neurology, LSU Medical Center, P.O. Box 33932, Shreveport, LA 71130.

from cases of thalamic stimulation (Cappa & Vignolo, 1979; Ojemann, 1977; Fedio & Van Buren, 1975) and from surgically induced thalamic lesions (Darley, Brown, & Swenson, 1975; Riklan & Levita, 1970; Ciemins, 1970; Guiot, Hertzog, Rondot et al., 1961; Waltz, Riklan, Stellar et al., 1966; Bell, 1968). Several authors have concluded that thalamic involvement with speech is a left hemispheric function (Cappa & Vignolo, 1979; Reynolds et al., 1978; Reynolds et al., 1979; Riklan & Cooper, 1975), although this is not accepted by others.

I have been unable to find a previously reported case of a right sided thalamic hemorrhage producing documented aphasia. The purpose of this paper is to report such a case, to provide additional evidence that a thalamic lesion can produce a persisting speech deficit, and to describe the results of testing such a patient at intervals during a 1-year period following her thalamic hemorrhage.

#### CASE REPORT

A 71-year-old, left-handed, black female with a ninth grade education was admitted to the Louisiana State University Medical Center. Her past medical history was significant only for 5 years of intermittently treated hypertension. On the morning of admission, while walking into church, she experienced a sudden onset of weakness involving her left arm and leg. She complained of nausea but denied headache, loss of consciousness, or visual disturbance. Her family described that she spoke very little and when she responded "her words didn't come out right." As she was brought to the hospital from an outlying community she was noted to become sleepy.

The patient was lethargic but easily arousable to verbal stimuli. She was oriented to name, location, month, and year. Her speech was sparse, hoarse sounding, reduced in volume, and mildly dysarthric. She had little spontaneous speech but answered direct questions. Her level of attentiveness fluctuated, but she was sufficiently alert to follow verbal commands. Occasional verbal paraphasic errors were present in her responses (i.e., "winder" instead of clasp, in requesting her watch to be removed). Bedside aphasia testing revealed intact comprehension for multistage commands and fair preservation of repetition. Naming was impaired for common objects, their component parts, colors, and body parts. Right-left orientation, one- and two-digit calculations, and drawing were all impaired. Writing was illegible.

Cranial nerve examination revealed small, minimally reactive pupils. In the resting position her eyes were conjugately deviated downward and to the left of midline. Extraocular movements were full horizontally but upgaze was absent and downgaze moderately limited. Lateral gaze produced horizontal nystagmus. A left hemianopic field cut was suspected by threat testing. A moderately severe left hemiparesis was present with arm and leg involvement greater than the facial weakness. Reflexes were

mildly hyperactive on the right. Plantar response was flexor on the right and extensor on the left. Sensory testing revealed loss of pain and to a lesser extent touch and vibration on the left, including the face and trunk.

An electroencephalogram revealed moderate amounts of right sided, irregular, polymorphic, low-voltage delta activity, most prominent in the posterior frontal and the temporal regions. A CT scan with and without contrast enhancement was performed and revealed a hemorrhage in the right thalamus. Follow-up scans performed 16 days later are also seen in Fig. 1.

The patient underwent aphasia testing using the aphasic screening test from the Halstead-Reitan neuropsychological test battery at 3 and 12 days and 6 and 12 months after the onset of symptoms. These results and the findings on serial neurologic examinations are described below. Selected results are noted in Fig. 2 and Table 1.

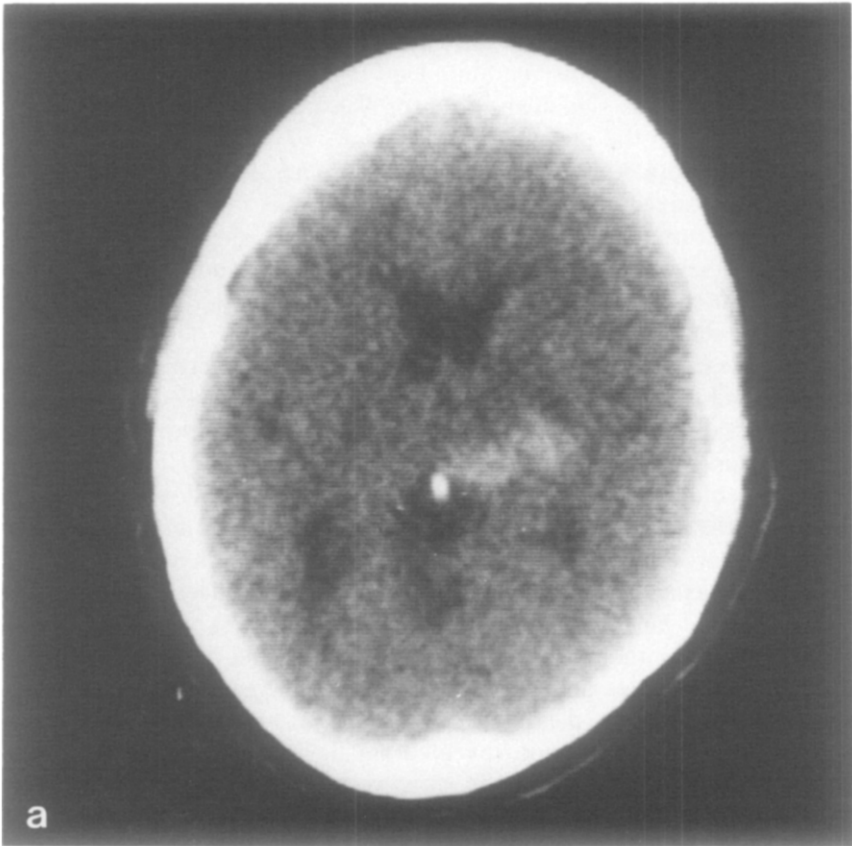


FIG. 1. These unenhanced CT scans, at the level of maximal extent of the hemorrhage, were performed on the 1st and 17th days posthemorrhage. Contrast enhancement performed with the second scan revealed no areas of enhancement beyond the area of the original hemorrhage. No additional lesions were visualized.

Clinically, by the third day the patient was beginning to show signs of improvement and increasing alertness. Pupils were larger and more briskly reactive to light. Nystagmus and ocular movement limitations remained. Her hemiparesis and reflex asymmetry was unchanged but the facial weakness was less pronounced. The first of the aphasia series was administered. A portion of the results are shown for comparison purposes in Table 1. She could name only two of six simple objects, repeat three of five words or phrases, and read virtually only single letters. When attempting to read words or phrases she read one letter at a time. Double digit subtraction and single digit multiplication were correct only in one of seven attempts. Other portions of the testing revealed left sided perceptual neglect, constructional apraxia and left-right confusion regarding commands and instructions. Her hand writing was severely dysgraphic and her drawings unrecognizable (Fig. 2).

Ten days later, by bedside testing, her language was clearly better, with a more normal voice volume. Ocular motility revealed some remaining upgaze limitation. Nystagmus had substantially diminished and a field

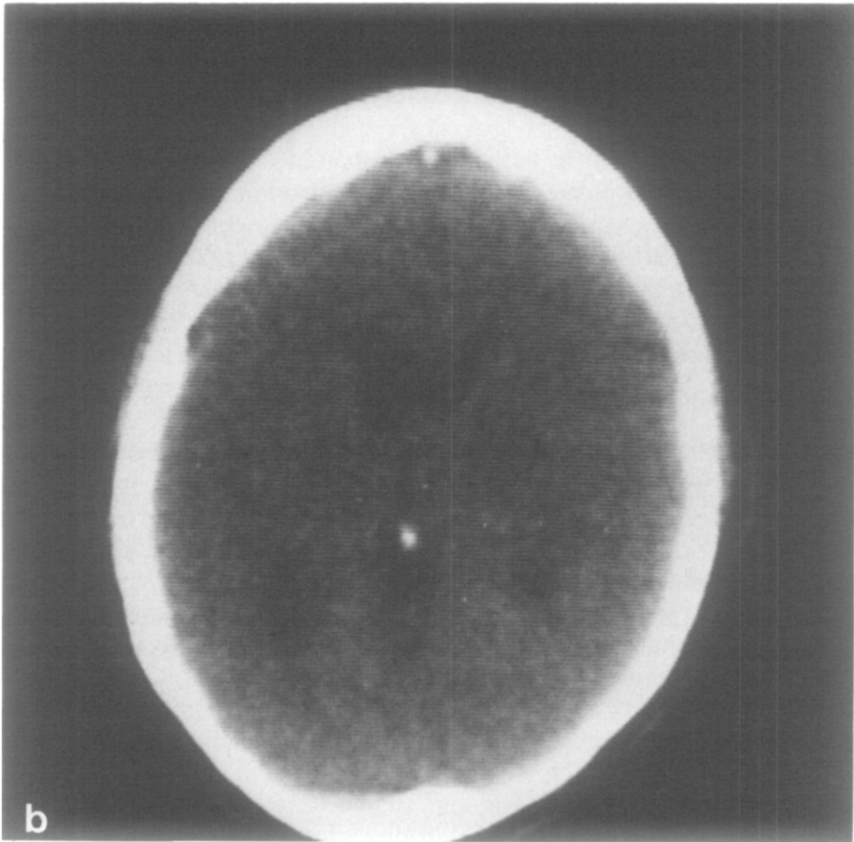


FIG. 1—Continued.




FIG. 2. Examples of the patient's ability to copy a square (top) and an old-fashioned key (bottom) at 3 days, 12 days, 6 months, and 12 months following a thalamic hemorrhage.

cut was no longer demonstrable. The motor weakness and hemisensory loss remained unchanged. Formal aphasia testing showed significant improvement in her use and comprehension of language symbols. Changes in naming, repetition, and reading ability are noted in Table 1. Her left-sided perceptual difficulty had also substantially decreased. Her handwriting and drawing continued to be severely impaired.

At 6 months, neurologic examination revealed normal extraocular motility, symmetric and reactive pupils, and no field cut or nystagmus. A moderate hemiparesis remained with leg and arm weakness being equal and more severe than facial weakness. The left-sided sensory loss remained and the hyperreflexia included sustaining clonus at the left ankle. The aphasia battery showed continued improvement in expressive language, as well as in drawing and writing skills. Some dyslexic errors remained but reading skills were better. There continued to be mild spelling and naming errors (Table 1). The handwriting had become recognizable and readable but with some dysgraphic errors still present. Some constructional apraxia persisted but the drawings were beginning to be recognizable (Fig. 2). At her 1-year follow-up the neurological examination showed no significant change over the preceding 6 months. Aphasia testing revealed some mild improvements in spelling and reading but some erroneous responses continued to be present. Handwriting was still dysgraphic and her drawings continued to reveal some evidence of impairment. The level of naming errors remained essentially as it was 6 months earlier. On confrontation naming and in conversational speech she continued to have difficulty with naming which resulted in pauses, some generalization and naming errors (i.e., watch winding stem was called "catch," a cloth watch band was called "chain," button called "hooker," etc.).

The findings on neurologic examination in patients with thalamic hem-

orrhage have clinically localizing value. Fisher's summary of findings in this disorder included predominance of sensory over motor deficits, ocular motor disturbances, small sluggish pupils, and significantly reduced alertness or even coma (Fisher, 1959). The ocular motor disturbances can include impairment of conjugate vertical gaze and often downward deviation of the eyes at rest. Fisher also noted a global dysphasia seen in dominant hemisphere lesions. Ciemins (1970) reported two additional cases with mixed aphasia and with autopsy findings of localized hemorrhage in the left thalamus. He concluded that "lesions in the dominant thalamus, and most particularly in the posterior portion, may produce aphasia," and that the aphasia is of a mixed motor and receptive type. Benson (1979), in his recent book, concluded that thalamic lesions producing speech abnormalities appear to be quite rare but have been described with some increasing frequency. Reports have most often involved hemorrhages (Bugiani et al., 1969; Cappa & Vignolo, 1979; Ciemins, 1968, 1970; Fazio et al., 1973; Mohr et al., 1975; Reynolds et al., 1978; Reynolds et al., 1979; Samarel et al., 1976) but have also included tumors (Arseni, 1958; Cheek & Taveras, 1966; Smyth & Stern, 1938), abscesses (Panchal et al., 1974), and possibly hemorrhagic infarcts (Mohr et al., 1975).

Some authors have, however, debated the existence of a specific type of aphasia associated with lesions restricted to the thalamus (Brown, 1974; Van Buren, 1975) and explanations for altered speech have included the concept that acute brain lesions involving a particular region can cause more extensive disturbances than accounted for by the local lesion alone (phenomenon of diaschisis) (Samarel et al., 1976). Other explanations have included: compression and edema affecting the adjacent temporal lobe pathways (Van Buren, 1975; Horenstein, Chung, & Brenner, 1978; Mohr et al., 1975), decreased alertness mimicking speech disturbances, and the possibility of an undetected cortical lesion located in one of the more classical speech areas.

Reports from series of postoperative thalamic lesions, performed as treatment of movement disorders, have also reviewed changes in speech patterns. Reduced voice volume which improves in the immediate postoperative period but which may persist when lesions involve the dominant hemisphere have been described (Bell, 1968; Hermann, Turner, Gillingham et al., 1966). Other authors have noted the occurrence of postoperative dysarthria and dysphasia (Bell, 1968; Waltz et al., 1966; Ojemann, 1977; Fedio & Van Buren, 1975; Ojemann & Ward, 1971). Bell (1968) reported reduced verbal output and disturbances in rhythm modulation which occurred despite normal repetition, characteristics he felt indicated an expressive rather than receptive type of dysphasia.

Hemispheric dominance in patients with aphasia is unclear in many reports. Bell's (1968) data and literature review suggests dysphasia only occurred after operation on the left hemisphere. However, one of their

TABLE 1  
RESULTS OF SELECTED PORTIONS OF THE REITAN-INDIANA APHASIA SCREENING TEST

Item	Time after hemorrhage when testing was performed			
	3 Days	12 Days	6 Months	12 Months
Spelling				
Cross	croos	croos	+	+
Triangle	tr...angle	trange	tryangle	traeager
Square	quair	squar	quer	squar
Naming				
Square	zero	box, square	box, square	box, square
Cross	square blocks <sup>a</sup>	+	+	x, star
Triangle	very square <sup>a</sup>	v,y,u	v, square	v, y
Baby	+	+	+	+
Fork	+	+	+	+
Key	flashlight, nail	a nail	+	+

Repeating					
Triangle					
Massachusetts	trying	+	+	+	
Methodist, Episcopal	+	+	+	+	phonetically close
He shouted the	—	—	—	—	phonetically close
warning	+	+	+	+	
Seven	+	+	+	+	
Reading					
7 six 2	six 2	+	+	+	
M G W	+	+	+	+	
seven	s..e..v..e..n	+	+	+	
See the black dog	s..e..c...t...c....	+	+	+	
	d...o...e	—	—	—	
He is a friendly animal,	g...e...female,				
a famous winner of	feminine				
dog shows					

*Note.* Comparison data for selected portions of the aphasia testing done 3 days to 1 year after the thalamic hemorrhage. +, Indicates correct response; — indicates no response.  
 " May reflect some element of perseveration as the request to spell "square" had shortly preceded naming of these two objects.



possibly left-handed patients, who was excluded from statistical analysis, had dysphasia which could have possibly been due to a hemorrhage around a cryogenic lesion in the right thalamus. Hermann (1966) noted dysphasia in right-handed patients occurred only after a left-sided lesion. Based on conclusions drawn from thalamic stimulation studies and post-operative thalamotomy data, as well as their own cases, some authors have gone as far as describing a specific left hemispheric thalamic function for speech (Reynolds et al., 1978; Reynolds et al., 1979). Most other authors who support the concept of thalamic aphasia are more traditional, and advocate a dominant hemisphere thalamic speech function. Although this latter approach would be consistent with that expected from other types of aphasia, right-sided lesions producing a thalamic aphasia are not documented. The data in this report, concerning a right thalamic lesion producing a persisting aphasia in a left-handed patient, supports the concept of dominant hemisphere localization.

Those authors who advocate a more specific type of "thalamic aphasia" have reported that in spontaneously occurring cases a constellation of features such as paucity of speech, fading voice volume, anomia, perseveration, and neologisms occur, while comprehension and word repetition remain intact (Reynolds et al., 1979). Cappa and Vignolo (1979) reported decreased spontaneous speech, relatively preserved repetition, varying degrees of impairment of auditory comprehension, marked inertia, and grossly defective writing. Benson (1979) described near mutism with eventual change to verbose, paraphasic jargon output and anomia which is often severe but with relatively preserved comprehension and repetition. He emphasized a generally transient time course of these deficits.

The present case provides support for those who advocate a more specific type of "thalamic aphasia" with characteristics different from Broca's and Wernicke's aphasia. The preservation of repetition, while helping to differentiate this from conduction aphasia, suggests similarities to transcortical motor and sensory dysphasias. This would not be surprising if retained repetition is a feature of a lesion which leaves an intact perisylvian language core. The preserved repetition would seem to imply preserved phonemic elements of language while the associated dysphasia suggests an impairment of semantic levels of language (Cappa & Vignolo, 1979).

The persistence of some of this patient's deficits for greater than a year after onset would be against the suggestion advocated by some that the aphasia in thalamic lesions is a transient deficit due to associated swelling in the area near the hemorrhage. This case would also support the speech dysfunction characteristics mentioned by others as being related to thalamic lesions including reduced spontaneous speech, low voice volume, severe dysgraphia, anomia that is frequently initially severe but shows rapid improvement, and relatively good preservation of com-

prehension and repetition. In this patient these latter two deficits also showed early improvement.

## REFERENCES

- Arseni, C. 1958. Tumors of the basal ganglia. *American Medical Association, Archives of Neurology and Psychiatry*, **80**, 18–26.
- Bell, D. S. 1968. Speech functions of the thalamus inferred from the effects of Thalamotomy. *Brain*, **91**, 619–638.
- Benson, D. F. 1979. Aphasia, alexia and agraphia. *Clinical Neurology and Neurosurgery Monographs*. Edinburgh: Churchill Livingstone. Pp. 93–100.
- Brown, J. W. 1974. Language, cognition and the thalamus. *Confinia Neurologica*, **36**, 33–60.
- Bugiani, O., Conforto, C., & Sacco, G. 1969. Aphasia in thalamic hemorrhage. *Lancet*, **1**, 1052.
- Cappa, S. F., & Vignolo, L. A. 1979. "Transcortical" features of aphasia following left thalamic hemorrhage. *Cortex*, **15**, 121–130.
- Cheek, W. R., & Taveras, J. M. 1966. Thalamic tumors. *Journal of Neurosurgery*, **24**, 505–513.
- Ciemics, V. A. 1968. Aphasia with thalamic disorders. *Neurology*, **18**(3), 307.
- Ciemics, V. A. 1970. Localized thalamic hemorrhage: A cause of aphasia. *Neurology*, **20**, 776–782.
- Darley, F. L., Brown, J. R., & Swenson, W. M. 1975. Language changes after neurosurgery for Parkinsonism. *Brain and Language*, **2**, 65–69.
- Fazio, C., Sacco, G., & Bugiani, O. 1973. The thalamic hemorrhage. An anatomoclinical study. *European Neurology*, **9**, 30–43.
- Fedio, P., & Van Buren, J. M. 1975. Memory and perceptual deficits during electrical stimulation in the left and right thalamus and parietal subcortex. *Brain and Language*, **2**, 78–100.
- Fisher, C. M. 1959. The pathologic and clinical aspects of thalamic hemorrhage. *Transactions of the American Neurological Association*, **84**, 56–59.
- Guiot, G., Hertzog, E., Rondot, P., et al. 1961. Arrest or acceleration of speech evoked by thalamic stimulation in the course of stereotaxic procedures for Parkinsonism. *Brain*, **84**, 363–379.
- Hermann, K., Turner, J. W., Gillingham, F. J., et al. 1966. The effects of destructive lesions and stimulation of the basal ganglia on speech mechanisms. *Confinia Neurologica*, **27**, 197–207.
- Horenstein, S., Chung, H., & Brenner, S. 1978. Aphasia in two verified cases of left thalamic hemorrhage. *Transactions of the American Neurological Association*, 193–198.
- Mohr, J. P., Watters, W. C., & Duncan, G. W. 1975. Thalamic hemorrhage and aphasia. *Brain and Language*, **2**, 3–17.
- Ojemann, G. A., & Ward, A. 1971. Speech representation in ventrolateral thalamus. *Brain*, **94**, 669–680.
- Ojemann, G. A. 1977. Asymmetric function of the thalamus in man. *Annals of New York Academy of Sciences*, **299**, 380–396.
- Panchal, V. G., Parikh, V. R., & Karapurkar, A. P. 1974. Thalamic abscesses. *Neurology India*, **22**(2), 106–110.
- Reynolds, A. F., Harris, A. B., Ojemann, G. A., et al. 1978. Aphasia and left thalamic hemorrhage. *Journal of Neurosurgery*, **48**, 570–574.
- Reynolds, A. F., Turner, P. T., Harris, A. B., et al. 1979. Left thalamic hemorrhage with dysphasia: A report of five cases. *Brain and Language*, **7**, 62–73.

- Riklan, M., & Cooper, I. S. 1975. Psychometric studies of verbal functions following thalamic lesions in humans. *Brain and Language*, **2**, 45-64.
- Riklan, M., & Levita, E. 1970. Psychological studies of thalamic lesions in humans. *Journal of Nervous and Mental Diseases*, **150**, 251-265.
- Samarel, A., Wright, T. L., Sergay, S., et al. 1976. Thalamic hemorrhage with speech disorder. *Transactions of the American Neurological Association*, **101**, 283-285.
- Smyth, G. E., & Stern, K. 1938. Tumors of the thalamus: A clinico-pathological study. *Brain*, **61**, 339-374.
- Van Buren, J. M. 1975. The question of thalamic participation in speech mechanisms. *Brain and Language*, **2**, 31-44.
- Waltz, J. M., Riklan, M., Stellar, S., et al. 1966. Cryothalamectomy for Parkinson's disease. *Neurology*, **16**, 994-1002.