

# SUBCORTICAL APHASIA: TWO CLINICAL-CT SCAN CORRELATION STUDIES

**Stefano F. Cappa, Giuseppina Cavallotti, Mario Guidotti, Costanza Papagno and Luigi A. Vignolo**

(Centro di Neuropsicologia, University of Milan)

## INTRODUCTION

Language disturbances following lesions confined to the subcortical structures of the cerebral hemispheres are still a matter for research and discussion. While aphasia following thalamic lesions is fairly well established (for a recent extensive bibliography see McFarling, Rothi and Heilman, 1982), the findings concerning the basal ganglia and internal capsule are rarer and more controversial. Naeser, Alexander, Helm, Levine and Laughlin (1982) have described nine cases of "putaminal aphasia", in which, however, other structures, not only subcortical (such as the internal capsule, corona radiata and temporal isthmus), but also cortical (such as the insula and other cortical areas buried in *sulci*) were damaged. Some of these cases resemble those described by Mazzocchi and Vignolo (1979) as Broca's and global aphasia associated with "deep" lesions, i.e. lesions that do not reach the hemispheric surface but cannot be considered strictly "subcortical" since they involve the cortex buried in sulci. The deep vs. subcortical distinction is essential, we believe, in any classification of the lesions that are not visible on the hemispheric convexity.

Several authors have described language defects (with or without articulation and phonation defects) associated with lesions focused on the putamen, the caudate nucleus and the anterior limb of the internal capsule (Sterzi and Vallar, 1978; Cambier, Elghozi and Strube, 1979; Alexander and Loverme, 1980; Barat, Mazaux, Bioulac, Giroire, Vital and Arné, 1981; Damasio, Damasio, Rizzo, Varney and Gersh, 1982). The welter of data, to be discussed later in some detail, has prompted the present clinical-CT scan studies.

Two opposite but complementary approaches have been used. In Study 1, all brain damaged patients who underwent the CT scan within a given lapse of time and were found to harbor a vascular lesion confined to the basal ganglia were subsequently given a standard language examination, while in Study 2 all patients referred to our Aphasia Unit within a

given time period and submitted to the standard language evaluation and the CT scan were considered: among them, those with strictly subcortical lesions on the CT scan were selected for investigation.

It should be noted that the second approach is the one usually employed in studies correlating aphasia to the underlying lesion: aphasia is evaluated first, and subsequently the CT scan lesion is examined. By contrast, the opposite course was followed in Study 1, in which all patients with a particular CT scan lesion were selected in the first place, and were subsequently evaluated for presence/absence of language defects. This was done in order to obtain an estimate, however approximate, of the frequency of language disorders associated with a stable, subcortical lesion detectable by the CT scan.

#### STUDY 1 (FROM THE CT SCAN LESION TO THE LANGUAGE DEFECT)

##### *Subjects*

Our initial survey of the CT scans included 30 records of patients hospitalized in several Neurological, Neurosurgical and Medical Departments in Milan from November 1980 to June 1981, which showed a deep cerebrovascular lesion (either infarction or spontaneous intracerebral hematoma of either hemisphere). Those cases were selected which showed strictly "subcortical" lesions confined to the following structures: basal ganglia, centrum semiovale, internal and external capsule. Eighteen cases were excluded because (a) the CT scans were incomplete, showed bilateral lesions or belonged to left-handed or ambidextrous patients; (b) the clinical history disclosed other cerebrovascular accidents (either more than one complete stroke or more than three transient ischemic attacks); (c) patients were on a language rehabilitation program: the effects of the lesion in these patients could have been hidden by the functional compensation enhanced by the treatment.

We were left with 12 patients, 6 with a left hemisphere lesion and 6 with a right hemisphere lesion. Eleven were male, 1 female. Mean age was 63.3 (left) and 57.3 (right) years (S.D. 35.5 L; 31.4 R) and mean educational level 9.0 (left); 8.0 (right) years (S.D. 9.4 L; 7.2 R).

##### *Procedure*

The 12 patients underwent a complete neurological work-up. The CT scan had been performed in all of them within a period ranging from 10 to 42 days post stroke, and the site of the lesion was checked with reference to the atlas by Matsui and Hirano (1976). The assessment of aphasia was made from 15 to 44 days post stroke by means of a comprehensive

standard language examination currently used at our Aphasia Unit, designed to test different aspects of oral and written language; it yields both a series of quantitative scores and a record of the quality of language output. The examination is supplemented by the Token Test (De Renzi and Vignolo, 1962) in the 36 item version (De Renzi and Faglioni, 1978). Non-verbal intelligence was evaluated by means of two tests, Raven's Progressive Matrices (PM) 38 (norms available in Colonna and Faglioni, 1966) and Weigl's Color-Form Sorting Test (as modified by De Renzi, Faglioni, Savoirdo and Vignolo, 1966).

### Results

The main clinical features for the left and right group are summarized in Table I. None of the 6 patients in the right group had any linguistic or speech defect. Of the 6 patients with left subcortical lesions only 2 were aphasic. A detailed description of these two cases follows.

#### Case 1

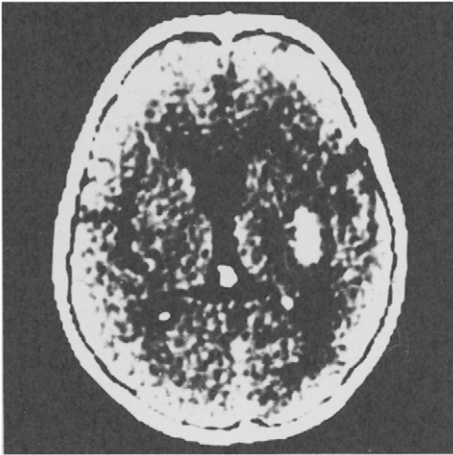
A 60 years old retired man suddenly experienced weakness of the face and right leg; speech was slurred and he occasionally used "wrong words". On admission the same day he had a right hemiparesis and aphasia (unspecified). The CT scan, performed 10 days later, showed an intracerebral hematoma of the left hemisphere, destroying the putamen and the posterior limb of the internal capsule, and encroaching upon the temporal isthmus and the cortex of the posterior part of the insula (Figure 1 A). The neurological examination performed 21 days

TABLE I

*Study 1: Main Clinical Features of Patients with Left and Right Subcortical Lesions*

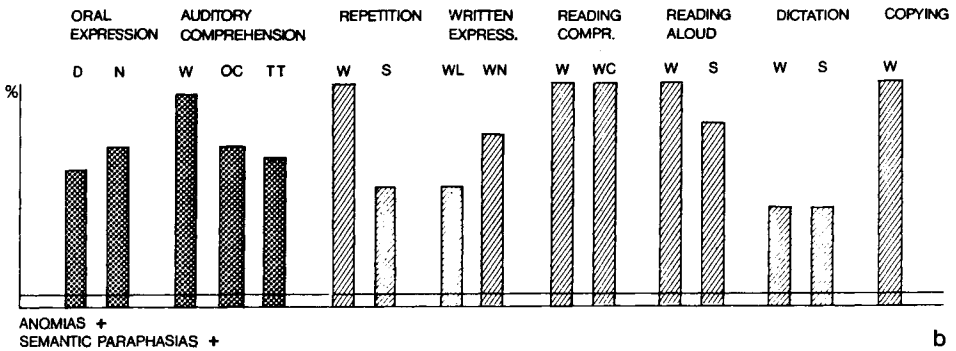
Patient N°	1	2	3	4	5	6	7	8	9	10	11	12
Side of the lesion	L	L	L	L	L	L	R	R	R	R	R	R
Age (years)	60	78	36	78	58	70	47	57	78	40	53	69
Sex	M	M	M	M	M	M	M	F	M	M	M	M
Etiology	H	I	I	I	I	H	H	I	I	I	I	H
Time from stroke to language examination (days)	21	22	22	29	22	22	25	23	44	38	23	15
Times from stroke to CT scan (days)	11	12	11	15	14	16	10	10	42	37	16	12
Disturbance of consciousness	-	-	-	-	-	-	-	-	-	-	-	-
Aphasia	+	+	-	-	-	-	-	-	-	-	-	-
Dysarthria	-	-	-	-	-	-	-	±	-	-	-	-
Visual field defect	-	-	-	-	+	-	-	+	-	-	-	-
Hemiparesis	+	+	+	+	+	+	+	+	+	+	+	+
Hemianesthesia	+	-	-	-	-	-	+	-	-	-	-	+

R = right; L = left; I = infarction; H = hemorrhage; + = presence; - = absence; M = male; F = female.



a

Fig. 1 (Case 1, Study 1) — A. CT scan: hematoma involving the posterior limb of the internal capsule and the putamen, with posterior extension towards the temporal isthmus. B. Language examination profile. The scores obtained on the main subtests are expressed as percentage of maximum score (100%). D = description of an event; N = oral naming; W = words; OC = oral commands; TT = Token Test; S = sentences; WL = writing a letter; WN = written naming; WC = written commands.



b

post onset showed a right hemiparesis with facial involvement, right hemisensory loss and ideomotor apraxia.

The standard language examination gave the following results (see Figure 1 B). Description of an event (how to shave with a hand razor) was fair, but the patient needed prompting by the examiner. There was some loss of content words and usage of "passe-partout" expressions (such as the verb "to do"). On visual naming, he made verbal paraphasias and circumlocutions ("one who paints" for "painter" and "a thing where gas is put inside, there's a flame, and it heats" instead of "stove"). He could dictate automatic series without errors (numbers from 1 to 10, days of the week, months of the year). Auditory comprehension of single words was slightly better for unrelated than for semantically related words (95 vs. 70 per cent). Carrying out oral commands was mildly impaired; the Token Test score was 23/36. Repetition was impaired for sentences and especially for neologisms (only 20 per cent correct). Writing was performed with the right hand, the signature was preserved, and he could copy and convert print to script without problems. Written naming was mildly impaired, while spontaneous writing was scarce but correct. Dictation was impaired (except for single letters and syllables). Reading aloud and reading comprehension were virtually perfect.

On Raven's PM 38 the patient scored 22/30 in 10 minutes. On Weigl's test he sorted according to shape, but then he started using the blocks to make constructions. Repeating the instructions had no effect: when the examiner grouped the blocks and asked the patient to find out the criterion, he understood only color. The score was 4/15.

In conclusion, the patient had a mild fluent aphasia, with anomias, circumlocutions and semantic paraphasias, mildly impaired repetition and auditory comprehension, and slight writing disturbances. Non-verbal sorting performance was poor.

Case 2

A 78 years old man experienced a sudden severe motor deficit in the right half of the body and difficulty in finding names of objects. On admission the next day he had a right hemiparesis with brachial predominance, unspecified speech disturbances and good comprehension. The CT scan, performed 15 days later, showed an area of ischemic hypodensity near the putamen and posterior limb of

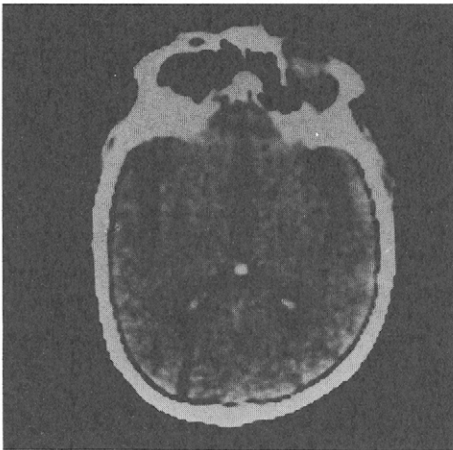
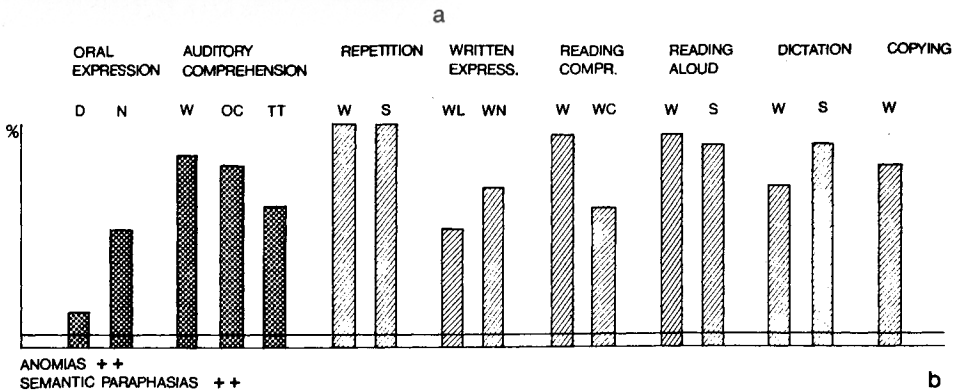


Fig. 2 (Case 2, Study 1) — A. CT scan: small ischemic lesion involving the putamen and the posterior limb of the internal capsule. B. Language examination profile (legend as in Fig. 1).



the left internal capsule. This was confirmed by a repeated CT scan one month later (Figure 2 A). Twenty-two days post onset the motor deficit was unchanged.

On standard language examination (see Figure 2 B) he gave the following results. Description of an event was fluent but poorly informative, consisting mainly of semantically vague words combined in syntactically correct, but complicated and often unfinished sentences. Naming was impaired, with anomias, verbal paraphasias (often in the same semantic sphere) and circumlocutions: sometimes the errors had a visual agnosic quality (e.g., "bowl" for "mushroom").

Automatic sequences were preserved. Auditory comprehension was mildly impaired: the Token Test score was 22/36. Repetition was perfect. The patient wrote with his left hand. Writing was mildly impaired, both spontaneously and to dictation. Copy and conversion from print to script were fair. Reading aloud was impaired only for neologisms; reading comprehension was better for unrelated than for semantically related words (95 vs. 70 per cent); he performed correctly 60 per cent of written orders.

The Raven's PM score was 27/32 in 10 minutes. On Weigl's test he could not make any arrangements, despite several trials; he kept talking to himself while manipulating the blocks. When the arrangements were made by the examiner he could not find any criterion. He said: "Well, here's a triangle, a circle and a square, and they are different". His score was 0/15.

In conclusion, the most salient feature of this patient's aphasia was his fluent "empty" speech, with milder disturbances in the other language modalities. Nonverbal sorting performance was remarkably poor.

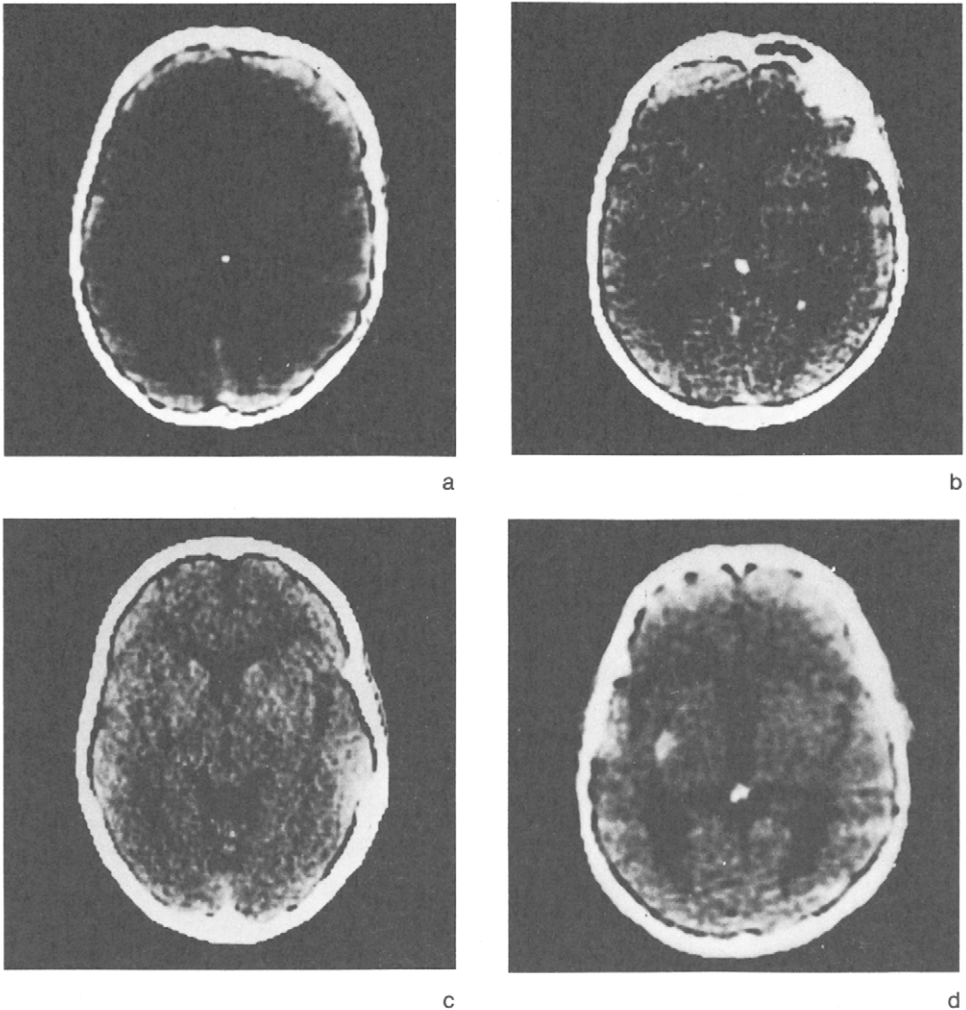
The CT scans of the four non aphasic patients are reproduced in Figure 3.

Table II shows the performance of the three groups (left aphasic, left non-aphasic, right) on the non verbal intelligence tests, as well as the mean scores of each group. On Raven's PM, the right groups performance is worse than that of the left, both aphasic and non aphasic. By contrast, the lowest scores on Weigl's test are obtained by the aphasic patients. The results are in agreement with previous findings from our laboratory (Colonna and Faglioni, 1966; De Renzi et al., 1966).

## STUDY 2 (FROM THE LANGUAGE EVALUATION TO THE CT SCAN)

### *Subjects*

The clinical records of all patients examined at our Aphasia Unit in the period 1976-1981 were scrutinized. Two hundred and fifty cases with a CT scan lesion similar to the one sought in Study 1 were selected. We found 32 cases, 26 of whom had to be excluded (a) for the reasons described for Study 1, (b) because they underwent language examination outside the time period elapsing between 2 and 10 weeks post onset, or the CT scan was made earlier than 10 days post onset. When these requirements are met, we feel that the clinical-CT scan correlation is sufficiently reliable.



**Fig. 3 (Case 3, Study 1) — A. CT scan: small ischemic lesion involving the putamen and the posterior limb of the internal capsule. B. (Case 4, Study 1) CT scan: small ischemic lesion, involving the putamen and the posterior limb of the internal capsule. C. (Case 5, Study 1) CT scan: small ischemic lesion, involving the putamen and the posterior limb of the internal capsule. D. (Case 6, Study 1) CT scan: small hemorrhagic lesion, centered on the external capsule and the antero-lateral lenticular nucleus.**

### *Procedure*

Both the standard language evaluation and the CT scan were available for all the 6 patients under study.

TABLE II

*Study I: Number of Patients Obtaining a Given Score on Raven's PM 38 and Weigl's Test, and Mean Scores of Each Group*

## Raven' PM 38

Scores	Right (N = 6)	Left, aphasic (N = 2)	Left, non aphasic (N = 4)
31			1
29			2
28	1	1	
27			
23	2		
22		1	
20	1		
14	1		
12			1
7	1		
Mean	19.2	24.5	25.3

## Weigl's Test

Scores	Right (N = 6)	Left, aphasic (N = 2)	Left, non aphasic (N = 4)
15	1		
12	1		
10	1		2
9	1		2
4		1	
3	2		
0		1	
Mean	8.7	2	9.5

### Results

Four patients were aphasic on the standard language examination, while two, referred to the Aphasia Unit because their physician suspected the presence of language disturbances, were found not to be aphasic at the time of formal language assessment. The main clinical features of the 6 patients are summarized in Table III. Mean age was 56.0 years (S.D. 35.5), mean educational level was 8.8 years (S.D. 13.9). A brief description of the 4 aphasic cases follows.

#### Case 1

Non fluent aphasia with phonemic errors and no articulatory disturbances. Repetition and auditory comprehension were impaired. Agraphia was present. The CT scan showed an infarction involving the head and part of the body of the caudate nucleus, the internal capsule and perhaps the anterior portion of the thalamus; the lesion extended upwards in the white matter.

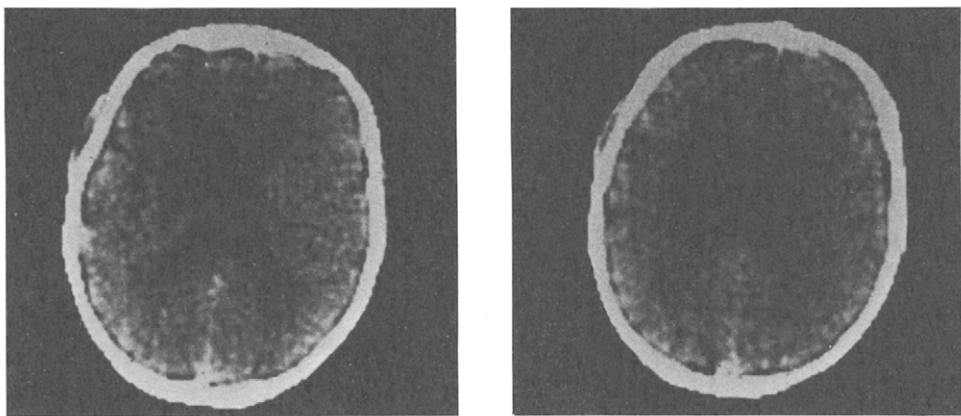


TABLE III  
Study 2: Main Clinical Features of Patients with Left Subcortical Lesions

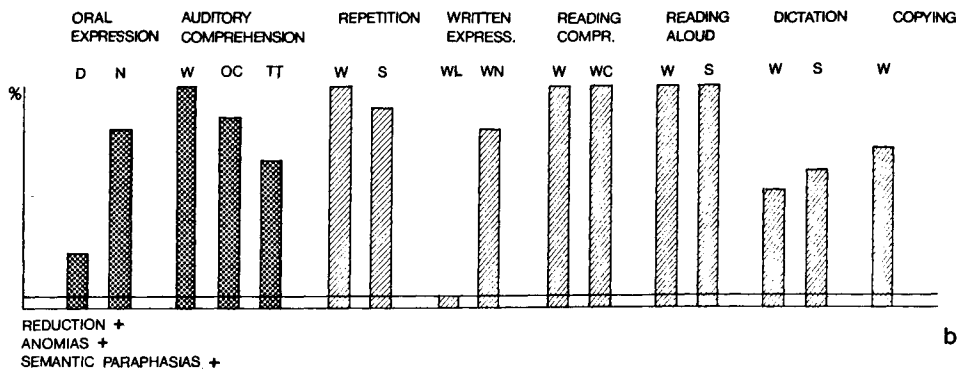
Age (years)	71	41	65	66	59	31
Sex	M	M	F	F	F	M
Etiology	I	H	H	I	H	I
Time from stroke to CT scan (days)	71	60	60	20	15	57
Time from stroke to language examination (days)	65	29	20	15	19	57
Disturbances of consciousness	-	-	-	-	-	-
Aphasia	+	+	+	+	-	-
Dysarthria	-	-	-	-	-	-
Visual field defect	-	-	-	-	-	-
Hemiparesis	+	+	-	-	-	+
Hemianesthesia	-	+	-	-	-	-

I = infarction; H = hemorrhage; + = presence; - = absence; M = male; F = female.

Fig. 4 (Case 1, Study 2) — A. CT scan: infarction involving the head and part of the body of the caudate nucleus, the internal capsule and the anterior portion of the thalamus; superior extension in white matter. B. Language examination profile (legend as in Fig. 1).



a



b

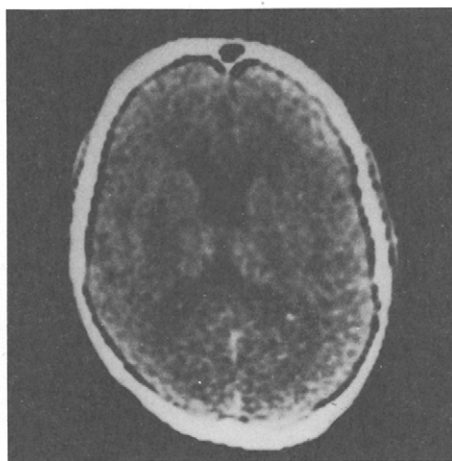
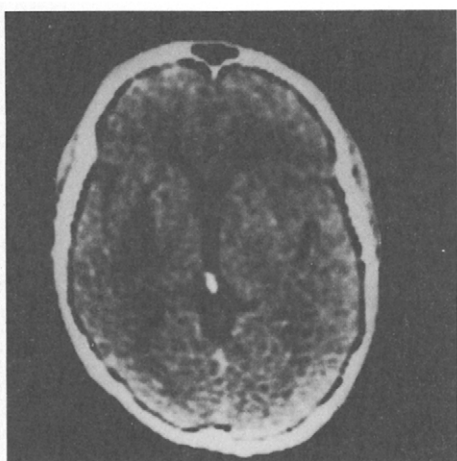
Case 2

Mild fluent aphasia with impaired repetition, agraphia, mild alexia. The CT scan showed a hematoma involving the putamen and the posterior limb of the internal capsule, with extension towards the temporal isthmus.

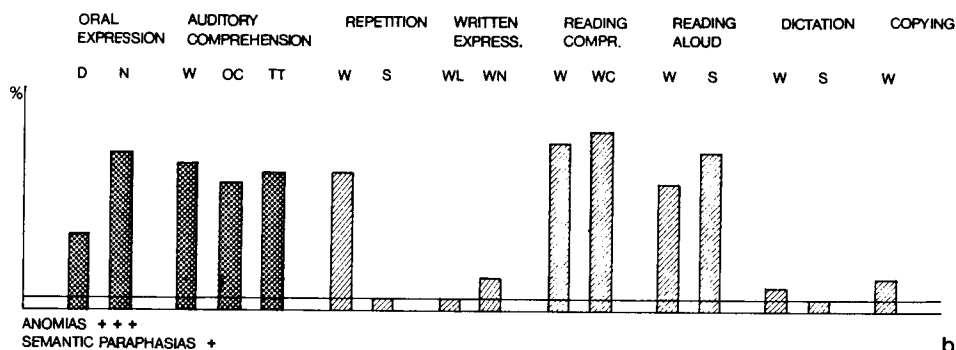
Case 3

Mild non fluent aphasia, no dysarthria, excellent repetition and mild agraphia. The CT scan showed a small hematoma involving the head of the caudate nucleus and the anterior limb of the internal capsule.

Fig. 5 (Case 2, Study 2) — A. CT scan: hematoma (hypodense - 60 days post onset) involving the putamen, the posterior limb of the internal capsule, with posterior extension towards the temporal isthmus. B. Language examination profile (legend as in Fig. 1)



a



b

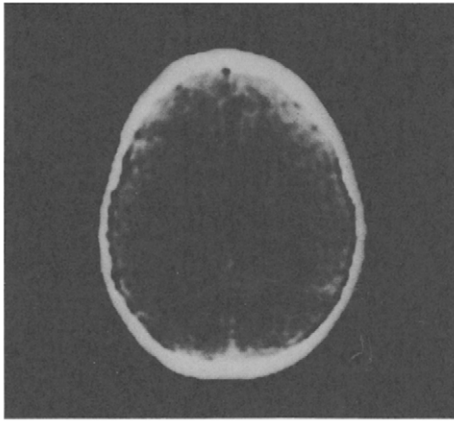
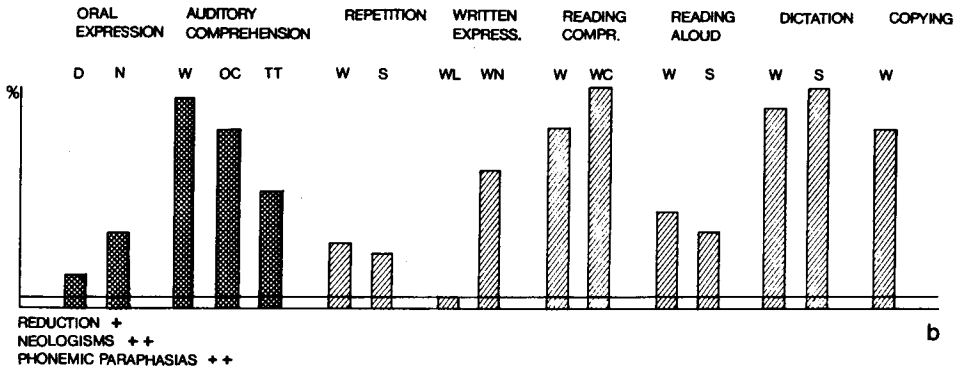


Fig. 6 (Case 3, Study 2) — A. CT scan: hematoma (hypodense - 60 days post onset) involving the head of the caudate nucleus and the anterior limb of the internal capsule. B. Language examination profile (legend as in Fig. 1).

a



b

### Case 4

Mild fluent aphasia with agraphia. The CT scan showed a small ischemic lesion of the putamen only after contrast enhancement.

The CT scans of the two non aphasic patients are shown in Figure 8.

## DISCUSSION

The findings of Study 1 suggest that aphasia occurs only in a minority (2 out of 6) of patients harboring a strictly subcortical lesion confined to the basal ganglia region of the left hemisphere.

The question then arises as to what are the possible factors that bring about aphasia in some of these cases. One may tentatively look for an

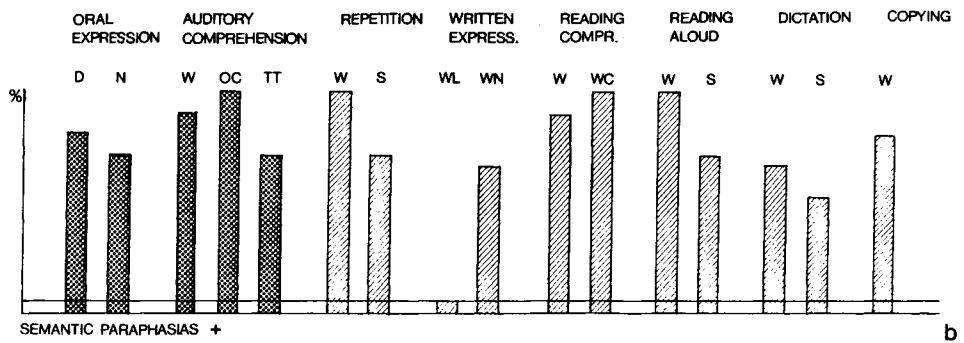
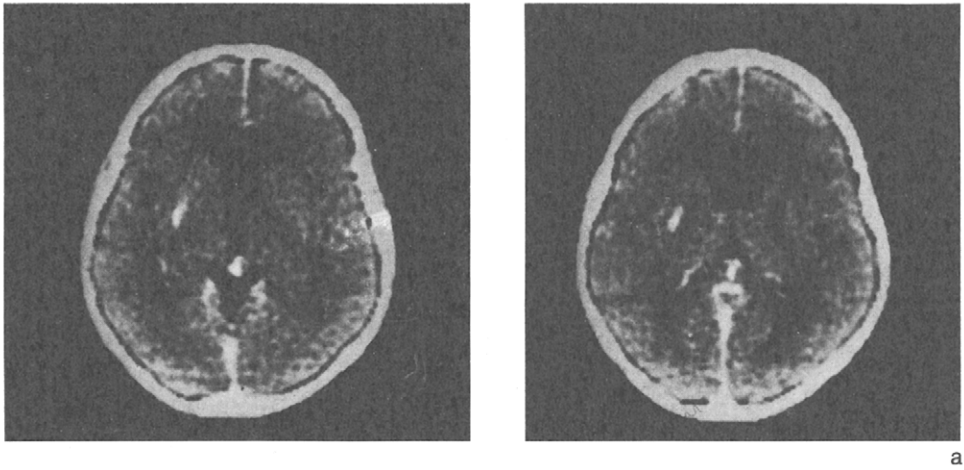


Fig. 7 (Case 4, Study 2) — A. CT scan: small ischemic lesion (contrast enhancement) of the putamen. B. Language examination profile (legend as in Fig. 1)

answer by considering the patients of both studies, and comparing the lesions of the aphasic (N=6) and non aphasic (N=6) groups.

The *nature* of the lesion (hemorrhage vs. infarction) has been thought to be crucial by some authors, suggesting that deep hemorrhagic lesions can produce aphasia by means of a pressure effect on the cortical language areas (for a discussion, see Alexander and Loverme, 1980).

Our data do not support this view, as in our series there is an equal number of hematomas and infarctions both in the aphasic and in the non aphasic group. As to the *size* of the lesion, we find a trend for the largest lesions to be associated with aphasia, but there are some remarkable exceptions: case 5, Study 2 (Figure 8) had a large hematoma and no language defects on standard testing, whereas a fluent aphasia was found in case 4, Study 2 (Figure 7), where the ischemic lesion was so small as to

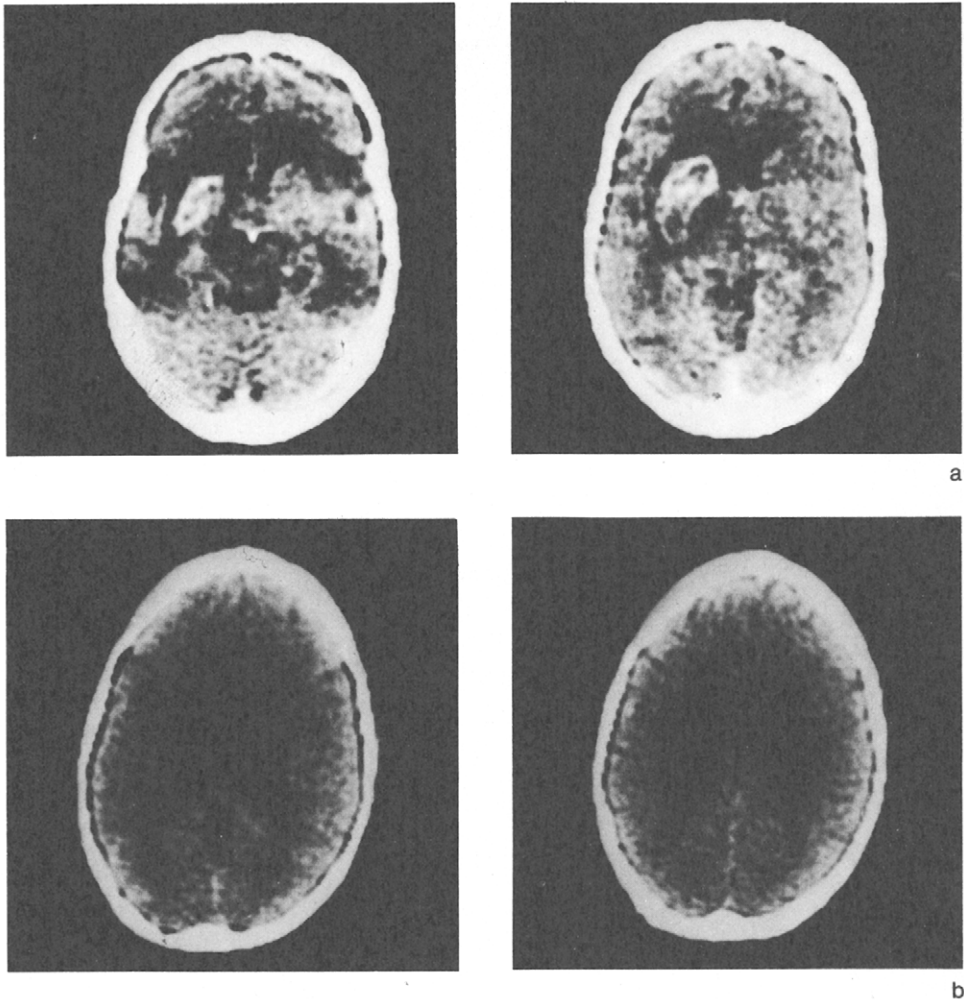


Fig. 8 (Case 5, Study 2) — A. CT scan: large hematoma of the capsulo-lenticular region surrounded by edema (contrast enhancement). B. (Case 6, Study 2) CT scan: infarction involving the head of the caudate nucleus, the anterior putamen and the anterior limb of the internal capsule with superior extension in the white matter.

be detected only after contrast enhancement. This suggests that the crucial factor is not perhaps the lesion size per se, but probably its interaction with one or several critical lesion sites. The findings of Damasio et al. (1982) suggest the hypothesis that such critical lesion sites are the putamen and the anterior limb of the internal capsule. A few case-reports support this interpretation (Sterzi and Vallar, 1978; Cambier et al., 1979; Barat et al., 1981). In particular, the case described by Barat et al. is remarkable, as it is the only recent report with post-mortem findings. Our

data lend only partial support to this hypothesis. In our series the patients with lesion sites similar to those which, according to Damasio et al., are crucial, are four in total, all from Study 2 (Cases 1, 3, 5 and 6). Case 6 from Study 1 had an anterior, but more lateral lesion. Of these, two had non fluent aphasia without articulation disturbances (Cases 1 and 3), while two (Cases 5 and 6) were not aphasic on formal testing, and probably had shown only transient language defects immediately post stroke. The patient with an anterolateral lesion (Case 6, Study 1) was not aphasic.

On the other hand, we found 7 patients with posterior subcortical lesions, centered on the putamen and the posterior limb of the internal capsule (Cases 1, 2, 3, 4, 5 of Study 1 and 2, 4 of Study 2). Of these, 4 had a mild fluent aphasia (Cases 1, 2 of Study 1 and 2, 4 of Study 2), while 3 were not aphasic (Cases 3, 4, 5 of Study 1).

In conclusion, at the present state of research on subcortical aphasias, the significance of our findings must be evaluated with caution. In a general way, we believe that they support a distinction between *anterior* subcortical lesions (putamen and anterior limb of the internal capsule), sometimes associated with atypical non fluent aphasias, and *posterior* subcortical lesions (putamen and posterior limb of the internal capsule), sometimes associated with mild fluent aphasias. This brings to mind the dichotomy proposed by Naeser et al. (1982) between anterior and posterior capsular-putaminal aphasias. In our cases the lesions were smaller, presumably sparing the cortex and involving a lesser amount of white matter: this can probably account for the difference in the clinical picture, which tended to be less severe and rather atypical if compared to the classical cortical aphasic syndromes.

The anatomical basis of the subcortical aphasias still leaves several problems unresolved. For example, one is led to speculate which could be the relative contribution of subtle differences in lesion site, or, on the other hand, of different individual patterns of localization of cerebral language mechanisms (Ojemann and Whitaker, 1978) in the causation of aphasia in strictly subcortical lesions. The combination of different research strategies, such as reports based on larger series, post-mortem verification of single cases and the use of the more recent localizing techniques, such as Positron Emission Tomography (Metter, Wasterlain, Kuhl, Hansen and Phelps, 1981) would seem to be necessary to clarify the matter further.

#### ABSTRACT

Two clinical-CT scan studies were undertaken in order to investigate the frequency and the characteristics of aphasia following strictly subcortical left hemisphere lesions. In Study 1, all patients whose CT scan, carried out within a

given period, showed subcortical lesions in both hemispheres, were evaluated for presence and type of aphasia; conversely, in Study 2 the records of all patients referred to our Aphasia Unit for language evaluation within a given period, were examined for presence of subcortical lesions on the CT scan.

In Study 1 aphasia was found in two out of six patients. In Study 2 stabilized, strictly subcortical lesions of the left hemisphere were found in six out of 250 patients referred to the Aphasia Unit; 4 out of 6 were aphasics. Closer scrutiny of the type of language disorder in the aphasics from both studies (N = 6) suggests the possibility of differentiating two types of defect: an atypical non fluent aphasia, sometimes associated with anterior capsular-putaminal lesions, and a mild fluent aphasia, sometimes associated with posterior capsular-putaminal lesions.

#### REFERENCES

- ALEXANDER, M.P., and LOVERME, S.R. Aphasia after left hemispheric intracerebral hemorrhage. *Neurology*, 30: 1193-1202, 1980.
- BARAT, M., MAZAUX, J.M., BIOULAC, B., GIROIRE, J.M., VITAL, C., and ARNÉ, L. Troubles du langage de type aphasique et lésions putamino-caudées. *Revue Neurologique*, 137: 343-356, 1981.
- CAMBIER, J., ELGHOZI, D., and STRUBE, E. Hémorragie de la tête du noyau caudé gauche. *Revue Neurologique*, 135: 763-774, 1979.
- COLONNA, A., and FAGLIONI, P. The performance of hemisphere-damaged patients on spatial intelligence tests. *Cortex*, 2: 293-307, 1966.
- DAMASIO, A.R., DAMASIO, H.D., RIZZO, M., VARNEY, N., and GERSH, F. Aphasia with non hemorrhagic lesions in the basal ganglia and internal capsule. *Archives of Neurology*, 39: 15-20, 1982.
- DE RENZI, E., FAGLIONI, P., SAVOJARDO, M., and VIGNOLO, L.A. The influence of aphasia and of hemispheric side of the cerebral lesion on abstract thinking. *Cortex*, 2: 399-420, 1966.
- DE RENZI, E., and FAGLIONI, P. Normative data and screening power of a shortened version of the Token Test. *Cortex*, 14: 41-49, 1978.
- DE RENZI, E., and VIGNOLO, L.A. The Token Test: a sensitive test to detect receptive disturbances in aphasia. *Brain*, 85: 665-678, 1962.
- MATSUI, T., and HIRANO, A. *An Atlas of the Human Brain for Computerized Tomography*. Tokyo: Igaku-Shoin, 1978.
- MAZZOCCHI, F., and VIGNOLO, L.A. Localization of lesions in aphasia: clinical CT-scan correlations in stroke patients. *Cortex*, 15: 627-654, 1979.
- McFARLING, D., ROTH, L.J., HELLMAN, K.M. Transcortical aphasia from ischemic infarcts of the thalamus: a report of two cases, *Journal of Neurology, Neurosurgery and Psychiatry*, 45: 107-112, 1982.
- METTER, E.J., WASTERLAIN, C.G., KUHLE, D.E., HANSEN, W.R., and PHELPS, M.E. (1981) 18 FDG positron emission computed tomography in aphasia. *Ann. Neurol.*, 10: 173-183, 1981.
- NAESER, M.A., ALEXANDER, M.P., HELM, N.A., LEVINE, H.L., LAUGHLIN, S.A. and GESCHWIND, N. Aphasia with predominantly subcortical lesion sites; description of three capsular putaminal aphasia syndromes. *Archives of Neurology*, 39: 1-14, 1982.
- OJEMANN, G.A., and WHITAKER, H.A. Language localization and variability. *Brain and Language*, 6: 239-260, 1978.
- STERZI, R., and VALLAR, G. (1978) Frontal lobe syndrome as a disconnection syndrome: report of a case. *Acta Neurologica*, 33: 419-425, 1978.