

Short communication

Pain and hyperpathia in pontine haemorrhage

I. Regev, A. Avrahami, N. Bornstein, and A. D. Korczyn

Department of Neurology, Ichilov Hospital, and the Department of Physiology and Pharmacology, Sackler School of Medicine, Tel Aviv University, Ramat Aviv, Israel

Summary. A 56-year-old man had acute onset of left sided weakness, spontaneous pain and hyperpathia in the left limbs. CT demonstrated a small pontine haemorrhage, in the floor of the fourth ventricle.

Key words: Pain – Hyperpathia – Pontine haemorrhage

Zusammenfassung. Bei einem 56jährigen Mann traten akut eine linksseitige motorische Schwäche, spontaner Schmerz sowie Hyperpathie der linksseitigen Extremitäten auf. Eine kleine Tonsblutung unterhalb des Bodens des vierten Ventrikels konnte im CT nachgewiesen werden und war dann vier Wochen später nicht mehr nachweisbar.

Until recently, a pontine haematoma was thought to have extremely grave implications. The clinical manifestations were well defined [1, 2] and included loss of consciousness, abnormal eye movements, miotic pupils, bilateral involvement of the corticospinal tracts and pontine nuclei and respiratory abnormalities. The introduction of computed tomography (CT) resulted in the recognition of lesions more limited in extent and symptomatology [1–5]. We have encountered a case of pontine haemorrhage, the clinical manifestations of which included transient unilateral paresis, pain and hyperpathia, sparing the face. As far as we know, this is the first description of pain and hyperpathia secondary to pontine haemorrhage.

Case report

A previously healthy 56-year-old man was admitted to the department of neurology suffering from acute dizziness, followed by weakness and a burning sensation in the left limbs. Consciousness was not lost. On admission, the patient was alert. His blood pressure was 190/

Offprint requests to: Amos D. Korczyn, M. D., M. Sc., Department of Physiology and Pharmacology, Tel Aviv University Medical School, Ramat Aviv 69978, Israel

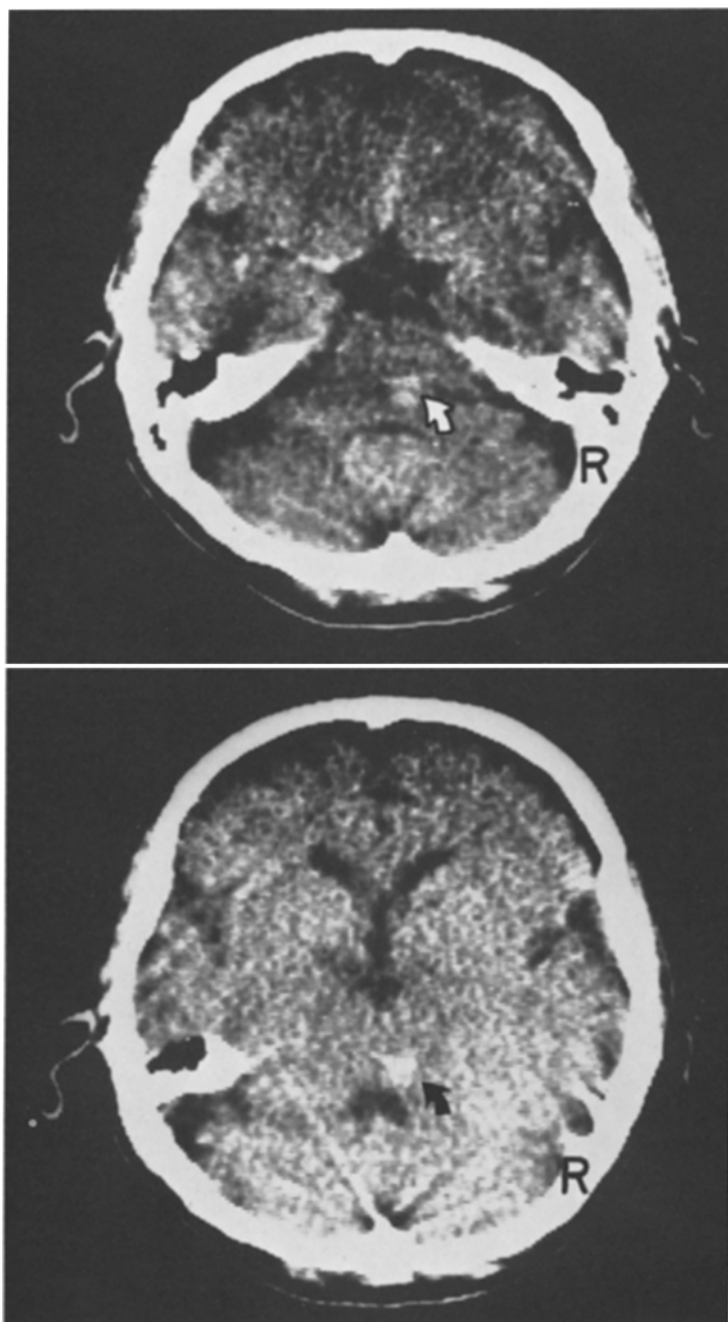


Fig. 1. CT of the posterior fossa (axial view, unenhanced). A haematoma is clearly seen in the pons (*arrow*), involving the posterior part on the right, just below the floor of the fourth ventricle. The diameter of the haematoma is 2.5 cm

110 mm Hg in both arms with rapid regular pulse (100/min). General physical examination was unremarkable. On neurological examination, there was flaccid left hemiparesis and Babinski sign. Increased sensitivity to touch, pin-prick and temperature in the left limbs and trunk were impressive, and even a mild touch on that side was unpleasant. Cranial nerves were intact, including facial sensation. There was dysmetria, disidiadochokinesia and intense tremor on the left. Electrocardiogram showed left ventricular enlargement. Skull radiograms and electroencephalogram were normal. Brain CT demonstrated a small haemorrhage in the pons, just below the floor of the cranial part of the fourth ventricle on the right (Fig. 1). The clinical course was benign, but the patient continued to complain of pains and burning sensation in his left limb. These subsided gradually and completely over several weeks. Neurological examination 6 weeks after the insult demonstrated only mild left hyper-reflexia. A repeat CT examination performed 4 weeks after the first showed resolution of the haematoma.

Discussion

Autopsied cases of small pontine haemorrhages are rare in the literature and documentation of non-fatal cases is even less common. However, the recent introduction of CT has enabled detection of small intrapontine haemorrhages, which do not cause loss of consciousness. Thus, Kase et al. [5] have studied two cases with small, largely unilateral haematomas of the pons and mid-brain. The clinical manifestations included ocular bobbing, complex forms of ophthalmoplegia, Cheyne-Stokes breathing and pyramidal tract signs. The "typical" manifestations like coma, pin-point pupils and hyperthermia were absent. In our case, the patient was alert, without ocular abnormalities. He had normal rhythmic respiration and the paresis was limited to his left side. However, the most unusual symptoms were spontaneous pain, sensation of burning hyperpathia and hyperalgesia, limited to the left limbs and left side of the trunk. Facial sensation was spared and the pain and hyperpathia were part of the initial presentation, rather than occurring during the recovery phase, as frequently seen in the Dejerine-Roussy syndrome. However, acute onset of similar dysaesthesia has also been described in vascular lesions of the brain-stem [6].

The damage in this case was unilateral, and was situated just below the floor of the fourth ventricle in its rostral portion. Its medial extension could not have quite reached the midline or it would have produced internuclear ophthalmoplegia. Its lateral extension could not have reached the trigeminal nucleus. Therefore, it must have damaged the central tegmental tract. This tract is thought to be part of the brain-stem reticular formation connecting *inter-alia* to the intralaminar nuclei of the thalamus. We speculate that the involvement of the central tegmental tract released the thalamus from tonic inhibition by the reticular formation, thus lowering the threshold and giving rise to hyperpathia.

References

1. Dhopes VP, Greenberg JO, Cohen MM (1980) Computed tomography in brainstem hemorrhage. *J Comput Assist Tomogr* 4: 603-607
2. Dinsdale HB (1964) Spontaneous hemorrhage in the posterior fossa. *Arch Neurol* 10: 200-217

3. Kase CS, Maulsby GO, Mohr JP (1980) Partial pontine hematomas. *Neurology (Minneapolis)* 30 : 652-655
4. Muller C, Wuthrich R, Wiggli U, Hunig R, Elke M (1975) The contribution of computerized axial tomography to the diagnosis of cerebellar and pontine hematomas. *Stroke* 6 : 467-475
5. Payne HA, Maravilla KR, Levinstone A, Heuter J, Tindall RS (1978) Recovery from primary pontine hematomas. *Ann Neurol* 4 : 557-558
6. Soffin G, Feldman M, Bender MB (1968) Alterations of sensory levels in vascular lesions of lateral medulla. *Arch Neurol* 18 : 178-190

Received July 7, 1983