

## Neuropsychological Analysis of a Case of Crossed Dysphasia Verified at Postmortem

NARINDER KAPUR

*Wessex Neurological Centre, Southampton*

AND

BRIAN DUNKLEY

*Institute of Psychiatry, University of London*

A case is reported of crossed dysphasia in a right-handed monolingual patient, where neuropathological verification of the unilateral site of the lesion was obtained within a year of detailed neuropsychological assessment. The patient's pattern of language impairment was characterized by agrammatic speech and relatively preserved naming ability. In addition, the patient had good repetition, poor comprehension, and marked impairment on visuospatial tasks. Neuropathological investigations showed a large area of infarction affecting cortex, white matter, and subcortical structures in the right hemisphere. The possibility is discussed of a distinction between two types of crossed dysphasia with either dissociated or simultaneous language and visuospatial deficits due to reversed representation of hemispheric specific functions or transfer of most cognitive functions to the right hemisphere.

### INTRODUCTION

The occurrence of dysphasia after right-hemisphere damage in right-handed patients with no history of left-handedness or early brain damage

Part of this work was carried while N.K. was at the Atkinson Morley Hospital, London. We are grateful to Miss D. Moir for carrying out the Boston Diagnostic Aphasia Examination, and to Dr. A. Coughlan for the stimulus pictures used in the assessment of J.S.'s expressive dysphasia. We would like to thank Dr. I. Janota for advice and help in the neuropathological investigations, Dr. Misch and Dr. Hensman for assistance with the postmortem procedures, and the patient's family for providing permission to carry out postmortem investigations. We are also grateful to Dr. C. Colbourn and to anonymous referees for their comments on the manuscript. Send requests for reprints to Dr. N. Kapur, Wessex Neurological Centre, Southampton General Hospital, Southampton, England.

is a rare phenomenon with the incidence being placed at between 1 and 2% (Zangwill, 1979). The identification of pure cases of crossed dysphasia is made difficult by the possibility that a small undetected lesion may be present in the left hemisphere. In addition it has been argued (Boller, 1973) that in some cases secondary effects from a space-occupying lesion in the right hemisphere may help to produce dysphasic symptoms. Only a few cases of crossed dysphasia with postmortem verification of the lesion site have been documented (April & Han, 1980; Assal, Perent, & Dervaz, 1981; Brust, Plank, Burke, Guobadia, & Heaton, 1982; Trojanowski, Green, & Levine, 1980), and in some of these detailed neuropsychological information was not reported. In this paper, we report a case of crossed dysphasia where the existence of a unilateral vascular lesion was verified both by neuroradiological investigations while the patient was alive and by postmortem neuropathological investigations which were carried out less than a year after neuropsychological assessment. We were also able to systematically test previous observations (Zangwill, 1979; Carr, Jacobson, & Boller, 1981) that in crossed dysphasia written and oral expression may be differentially impaired.

#### CASE REPORT

Patient J.S., a 57-year-old aeronautical engineer, suffered a right-hemisphere cerebrovascular accident in May 1978. He was right-handed for all activities, had no personal or family history of left-handedness nor any previous history of early brain damage. On admission to hospital he had marked dysphasia and a left hemiplegia. He was later admitted to a rehabilitation center for a period of intensive rehabilitation in April 1979, at which time he still had marked language impairment and left-sided weakness. In addition, he was noted to have diminished sensation in the left upper and lower limbs and a left temporal hemianopia to confrontation testing. Computerized tomography (CT) (Fig. 1) showed a large area of low density in the region of the middle cerebral artery. (Because of the size of J.S.'s vascular lesion, possible CT scan asymmetries were not explored in view of potential measurement artifacts). After several months of rehabilitation, he was discharged home, and died suddenly of a cardiac arrest in February 1980.

Psychological assessment (May–June 1979) on nine subtests of the Wechsler Adult Intelligence Scale revealed both J.S.'s dysphasia and his visuospatial difficulties—he obtained a Verbal IQ of 94, a Performance IQ of 78, and a Full Scale IQ of 86. Age-scaled subtest scores are given in Table 1. These scores represented a considerable drop from his premorbid intellectual level, which was estimated to be 121 on the basis of an adult reading test (Nelson & O'Connell, 1978). As can be seen, J.S. performed poorly on visuospatial tasks, especially the WAIS Block Design subtest. On this test he could only complete 1 of the 10 items, and this at the

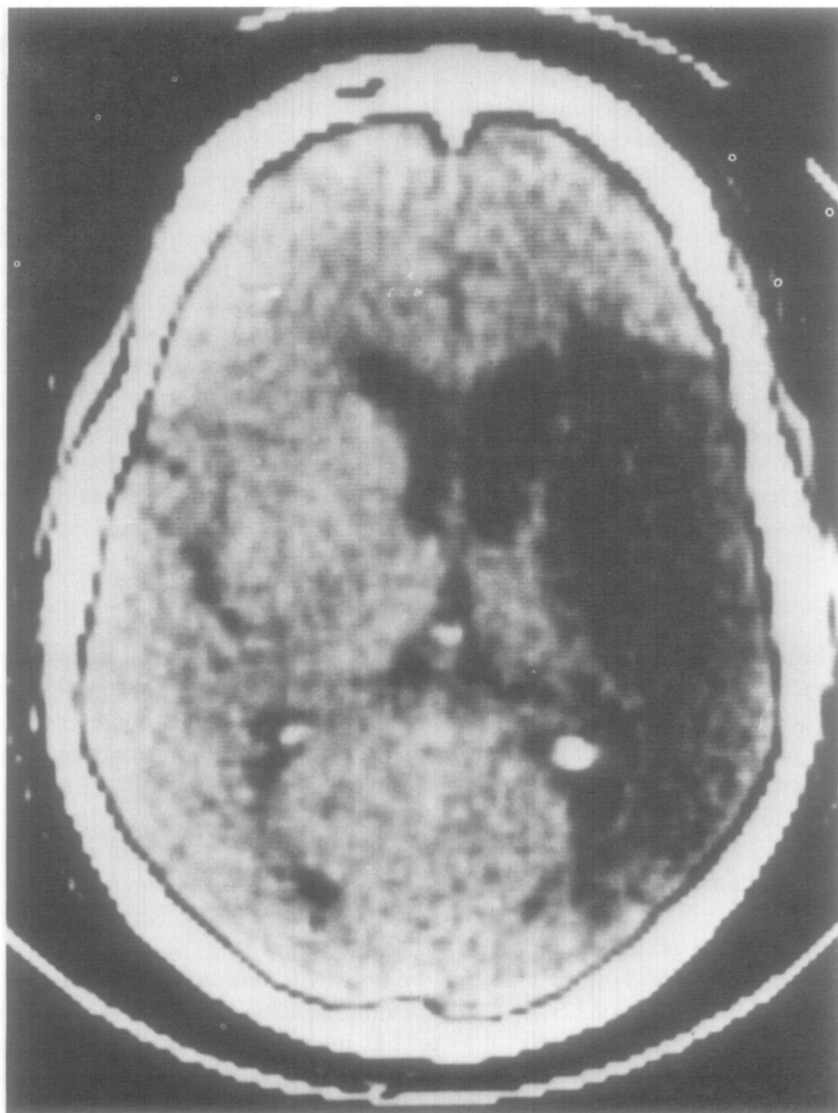


FIG. 1. CT scan of J.S. showing right-hemisphere infarct.

second attempt, indicating a degree of impairment typically associated with right- rather than left-hemisphere lesions. In the case of the WAIS Digit Symbol subtest (which was not scored) J.S. was unable, even after repeated demonstration, to understand what was involved in the task—presumably due to a combination of his visuospatial difficulties and language comprehension deficit. J.S.'s copy of the Rey–Osterrieth figure was impaired (25/36 points) and on a simple test of visual neglect (Albert, 1973)

TABLE 1  
J.S.'s WAIS SUBTEST AGE-SCALED SCORES

Verbal IQ		Performance IQ	
Information	13	Picture completion	8
Comprehension	8	Block design	3
Arithmetic	6	Picture arrangement	6
Similarities	8	Object assembly	6
Digit span	13		

he showed evidence of left-sided inattention. The Standard Progressive Matrices test was attempted but had to be discontinued after three parts had been completed as J.S. was consistently neglecting response alternatives on the left-hand side. He also showed moderate impairment on a nonverbal (faces) recognition memory test (Warrington, 1974). In view of his previous occupation as a highly qualified aeronautical engineer, the visual nonverbal deficits which J.S. displayed represent a marked degree of impairment.

The Boston Diagnostic Aphasia Examination (Goodglass & Kaplan, 1972) was administered in full and the relevant *z*-score profile is shown in Fig. 2. J.S.'s conversational speech was telegraphic with many omissions of indefinite articles and auxiliaries, and some errors in verb tense and verb endings. Within the limits of his expressive speech, he used a wide variety of intonation patterns. Speech comprehension was moderately impaired with deficits on a wide range of tasks ranging from execution of complex commands to understanding passives, possessives, and prepositions. Comprehension of left-right statements was also poor. Oral reading was intact, and comprehension of single words was unimpaired. He did, however, have considerable difficulty in understanding written connected discourse. Serial writing and writing to dictation were good. Narrative writing was somewhat telegraphic and errors were evident in plural and verbal endings. On a verbal (words) recognition memory test (Warrington, 1974) J.S.'s performance was markedly impaired (31/50). There was no evidence of any significant limb or buccofacial apraxia, as tested by J.S.'s ability to simulate certain actions, and he could also copy hand postures (testing was restricted to the right side in view of his left-sided hemiplegia).

An experiment was carried out to test previous observations (Zangwill, 1979; Carr et al., 1981) that in crossed dysphasia written expression may be relatively spared compared to oral expression. J.S. was shown eight sets of pictures (Byrne, 1967) which varied in complexity from a simple scene to a sequence of related scenes. On one occasion J.S. was asked to provide oral and written descriptions of the event being depicted in the picture(s), with oral descriptions being required for four of the items



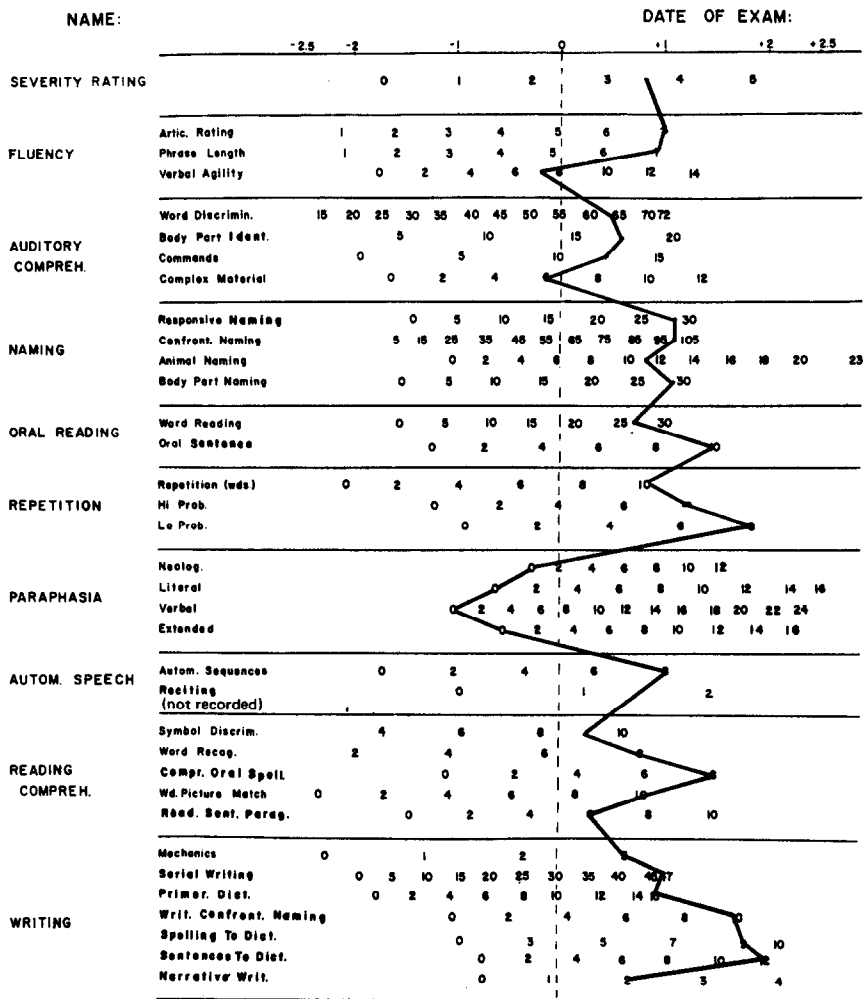


FIG. 2. z-Score profile of scores on Boston Diagnostic Aphasia Examination.

and written descriptions for the remaining four items. Three days later J.S. was asked to respond to the same set of stimuli with the output mode counterbalanced from that used previously. The transcriptions of J.S.'s oral and written responses were assessed by two qualified speech therapists who were asked to indicate, for each set of oral and written responses, which was more grammatically correct and which more accurately reflected the content of the pictures. Both therapists were "blind" to the response mode of the transcription and to each other's responses. Both therapists rated J.S.'s oral output as more accurately reflecting the content of the pictures, whereas his written output was found to be more

grammatically correct. Neither written nor oral expression, however, was rated as being consistently better than the other on both measures.

After several months of speech therapy, there was some improvement in certain areas of J.S.'s language function, such as oral and written comprehension, but no significant change occurred in the overall pattern of dysphasia which he displayed.

### NEUROPATHOLOGICAL FINDINGS

The brain weighed 1268 g. Macroscopic examination of the brain showed asymmetrical cerebral hemispheres, the right being smaller than the left (Figs. 3-7). There was an area of softening in the right cerebral hemisphere around the Sylvian fissure, including postero-inferior frontal lobe, superior

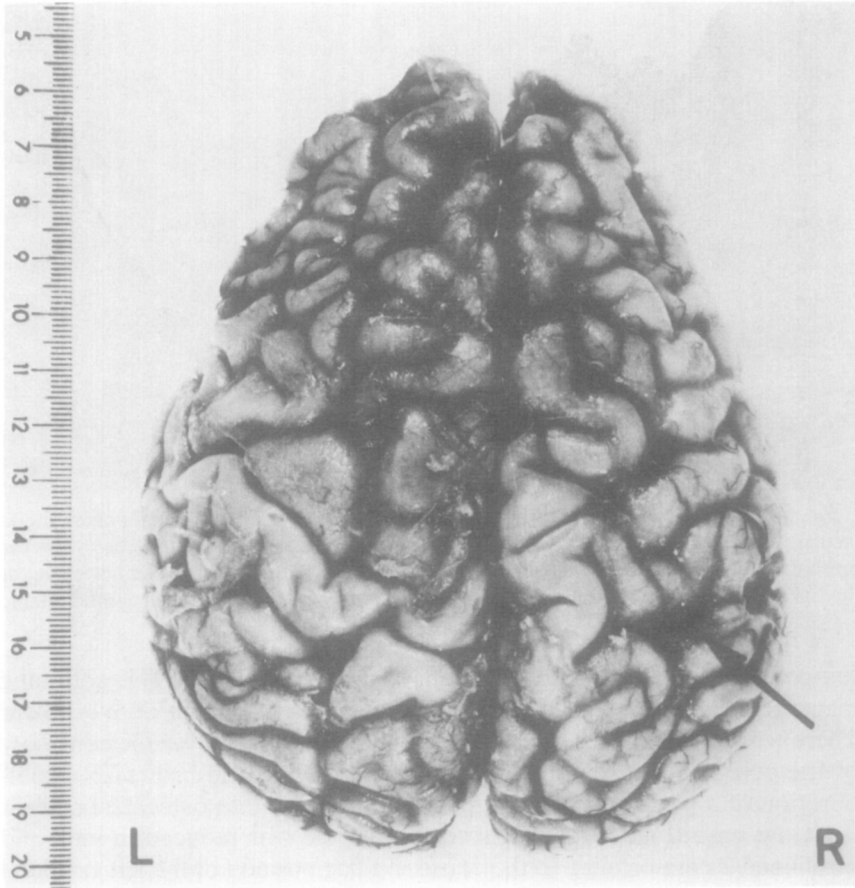


Fig. 3. Convexities of the cerebral hemispheres: the right is smaller than the left. There is little visible surface abnormality in the right hemisphere apart from narrowing and discoloration of a parietal gyrus indicated by the arrow.

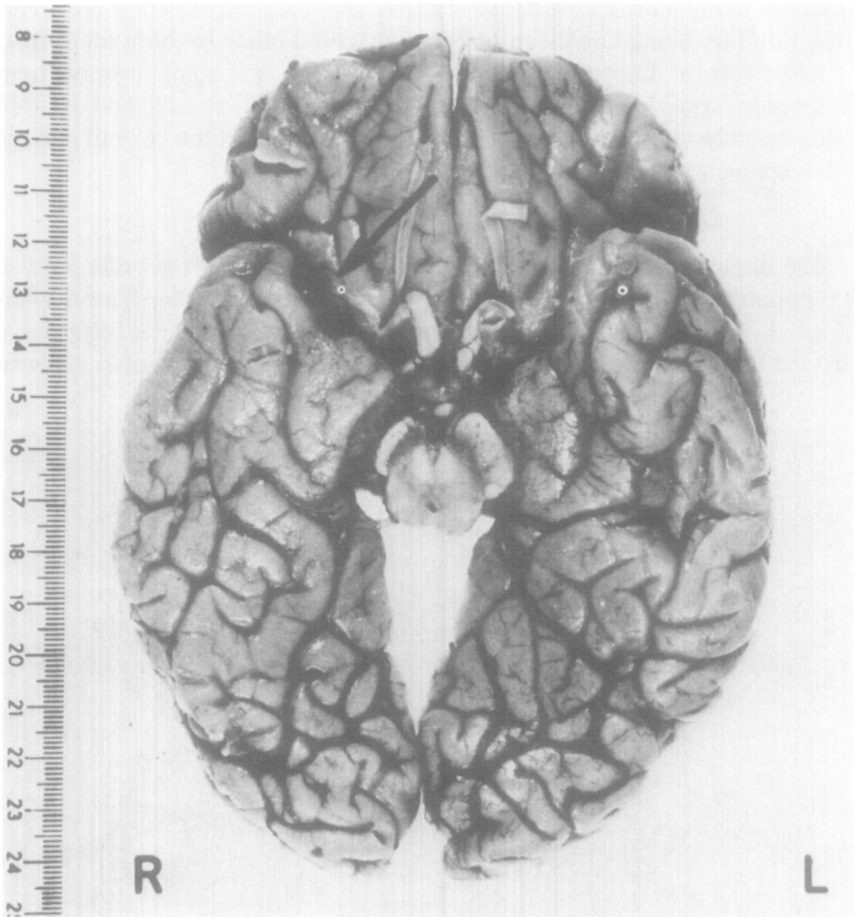


FIG. 4. Undersurface of cerebral hemispheres there is loss of bulk of right anterior and medial temporal lobe. A cavity in the orbital surface of the right frontal lobe (arrow) is present. The right cerebral peduncle is smaller than the left. Occlusion and narrowing of the right internal carotid artery contrasts with the widely patent left internal carotid artery.

temporal gyrus, and postcentral area of the parietal lobe. This softening measured some 10 cm anteroposteriorly and 4 cm from above down. There was however little surface abnormality to be seen over the convexity of the cerebral hemispheres except for narrowing and brownish discoloration of a parietal gyrus just posterior to the right postcentral sulcus.

At the base (Fig. 4), the right temporal pole was reduced in bulk and positioned 2 cm posterior to the corresponding position of the left temporal pole. There was a cavity 2 cm diameter in the posterolateral part of the orbital surface of the right frontal lobe. The optic nerves, chiasma and tracts, and pituitary infundibulum and stalk appeared normal. The right

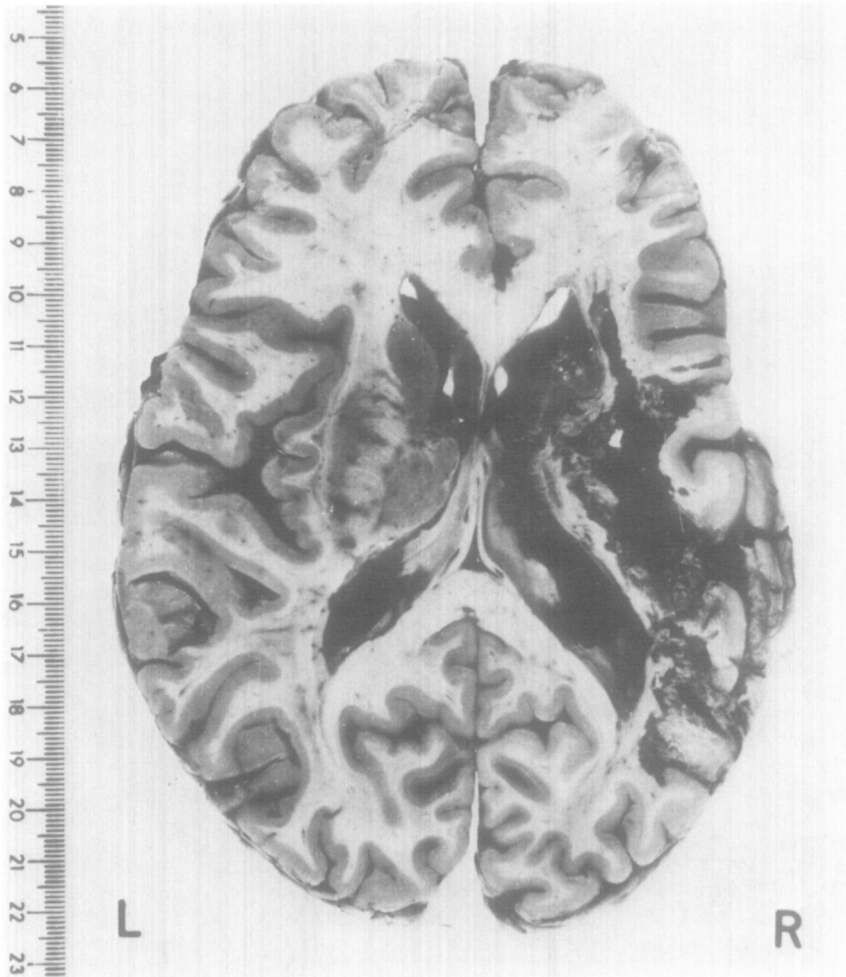


FIG. 5. Horizontal slice of the cerebral hemispheres viewed from above showing the extent of the infarct.

mammillary body was much smaller than the left which appeared of normal size.

The right cerebral peduncle and right medullary pyramid were smaller than those of the left. No external abnormality of the pons or cerebellum was seen.

The arteries of the base of the brain showed several abnormalities. The left internal carotid artery (ICA) showed uncomplicated atheroma and was somewhat ectatic (Fig. 4). Its anterior cerebral branch divided into two anterior cerebral arteries approximately at the point where the anterior communicating artery should be present.

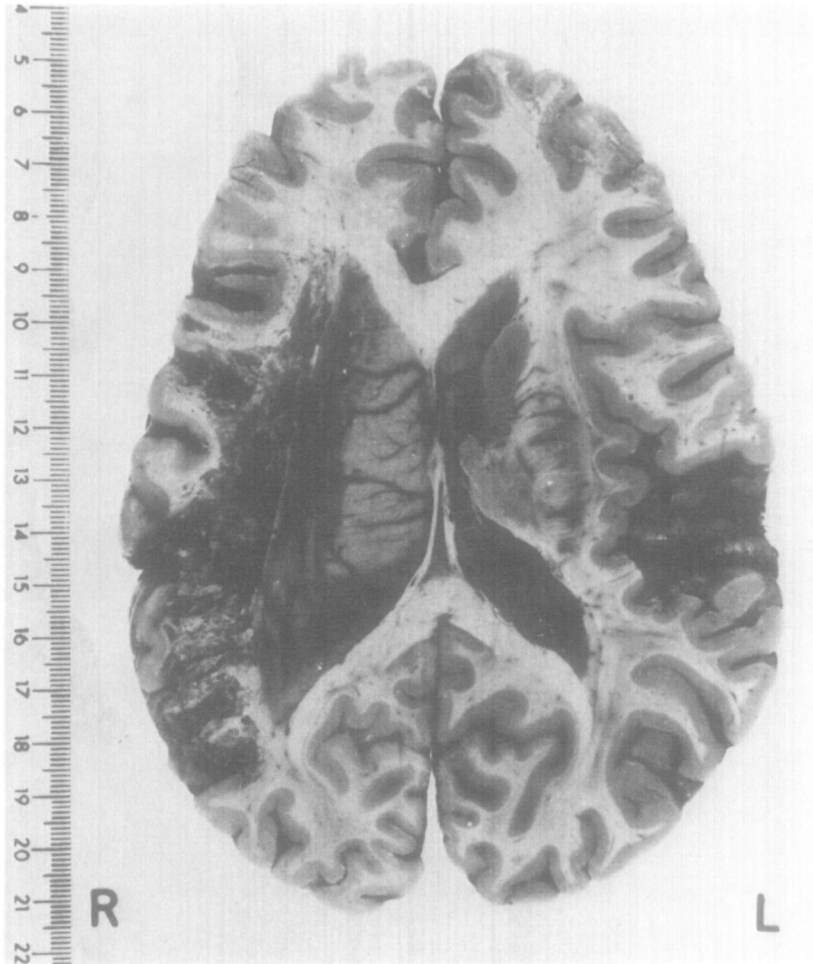


FIG. 6. Horizontal slice viewed from below showing upward extension of infarct cavity and asymmetry of ventricular dilatation.

The first part of the right anterior cerebral artery (between right ICA and usual site of anterior communicating artery) was represented by a very narrow thread-like channel. The right posterior communicating artery was also very small. The right ICA was narrow and occluded by organized thrombus; the right middle cerebral artery was thin and its lumen narrowed by concentric thickening of its wall. The posterior cerebral arteries were unequal in size, the right being smaller than the left, but both were patent.

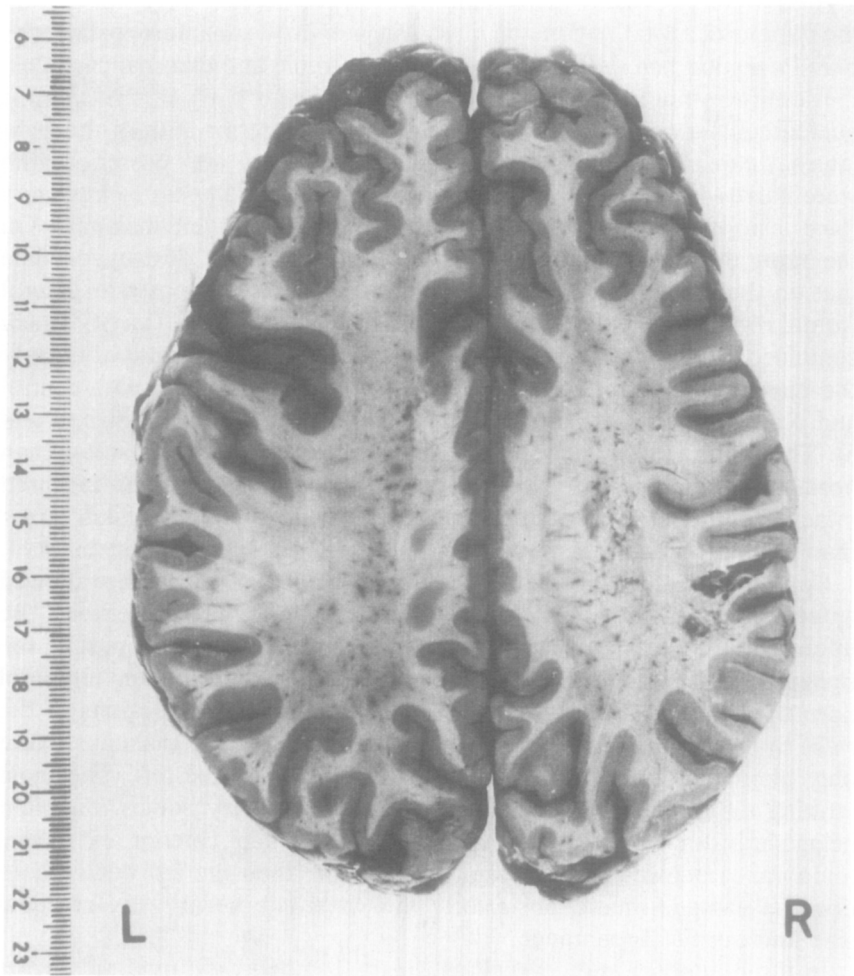


FIG. 7. Horizontal slice of cerebral hemispheres viewed from above showing softened white matter above infarct cavity and part of upward extension of cavity producing parietal lesion seen in Fig. 3.

In the vertebro-basilar artery system the lower end of the basilar artery was dilated, tortuous, and atheromatous as was the left vertebral artery. The right vertebral artery was much narrower than the left.

The cerebral hemispheres above and just below the Sylvian fissures were sliced in horizontal planes (Figs. 5-7) for comparison with CT scan pictures. The basal parts of the cerebral hemispheres were cut coronally.

Horizontal slices: these showed an old cavitated infarct within the territory of the right middle cerebral artery supply and underlying the softening palpable on the lateral aspect of the right cerebral hemisphere.

The cavity was large (Figs. 5 and 6) extending from the frontal lobe to the parieto-occipital region and measuring about 10 cm anteroposteriorly. This infarction had destroyed the insula, extreme and external capsules, the lentiform nucleus, and much of the head and body of the caudate nucleus of the right cerebral hemisphere. The anterior limb of the right internal capsule was also destroyed, and the genu and posterior limb were narrow and gliotic. The right thalamus did not appear to have any focal lesions in it but was about half the size of the left thalamus. On the right the planum temporale had been completely destroyed while that on the left appeared small. The cortex in the right posterior lateral frontal region was undermined by an extension of the infarct cavity which continued through to the orbital surfaces as described previously. Similarly the upward extension of the cavity had undermined much para-central and parietal cortex with small areas of cortical destruction (Figs. 4 and 5). The white matter adjacent to the infarct cavity also felt softer than normal, but the corpus callosum and forceps major and minor appeared intact. The superior part of the right lateral ventricle was much larger than that on the left—at more basal levels this difference is less marked.

Coronal slices through the basal parts of the cerebral hemisphere showed anterior commissures and columns of fornix to be well preserved. The inferomedial border of the infarct cavity involved the upper part of the right amygdaloid nucleus and extended to the roof of the dilated temporal horn of the right lateral ventricle. There were no visible lesions of the right hypothalamus and subthalamus but these, like the thalamus, were only about half the size of the same structures on the left. The most striking difference was in the size of the mammillary bodies, the right being shrunken. The right pes hippocampus, like other anterior and medial temporal structures in this brain, was smaller than the left but without obvious damage—more posteriorly the Ammon's horns were of equal size and normal appearance.

In the brainstem and cerebellum, apart from the right pyramidal tract degeneration, no other abnormality was found.

Microscopic examination confirmed the lesion to be an old cavitated infarct with surrounding fibrillary gliosis. The cortex of the right hemisphere, other than that destroyed by infarction, showed no abnormality. In particular, the cortex "undercut" by extension of the infarct cavity in the subjacent white matter did not show any morphological change by routine neuropathological staining methods, although one might surmise that at least some of its connections had been interrupted. No histological abnormalities of the cortex of the left cerebral hemisphere were found. No further vascular lesions were found and no abnormality was found in those structures which appeared smaller in the right cerebral hemisphere than in the left.

In summary, the brain showed a large old cavitated infarct of most of the territory of the right middle cerebral artery, associated with occlusion by thrombosis of the right internal carotid artery. Extensive damage to cortex, deep grey matter, and white matter had resulted, the cortical damage being a combination of direct vascular damage and effective "undercutting" by extension of the infarct cavity within the white matter. In the right hemisphere cortical areas equivalent to Broca's and Wernicke's areas were damaged by the infarct and the planum temporale was totally destroyed. Thalamocortical and geniculostriate connections were damaged in addition to the motor pathways within the infarcted region.

The findings of a general smallness of right-sided cerebral arteries and reduction of bulk of some right cerebral hemisphere grey masses which were apparently undamaged by the infarct suggest a congenital inequality of the cerebral hemispheres and make interpretation of any hemisphere asymmetries (sometimes related to functional differences) unreliable. However, it is of note that a similar asymmetry in the size of the cerebral hemispheres has been noted in a case of developmental dyslexia (Galaburda & Kemper, 1979).

#### DISCUSSION

Neuropathological investigations confirmed the presence of a unilateral right-hemisphere lesion in our right-handed patient who displayed marked dysphasia. His conversational speech was nonfluent and telegraphic, with spared repetition and confrontation naming. Oral reading was excellent and writing was mechanically sound, but reading comprehension and writing of sentences was impaired. There was no evidence of a dissociation between oral and written expression. In addition to his language deficits, our patient showed significant left-sided neglect and impaired performance on a number of visuospatial tasks.

Language and visuospatial functions can each be represented in either cerebral hemisphere in full, in part, or not at all, and there is consequently scope for a number of possible varieties of hemispheric specialization. Some of these possible varieties have been outlined by Kreindler, Fradis, and Sevastopol, (1966), and it remains to be established whether the organization of cerebral functions in crossed dysphasia differs significantly from other forms of atypical hemispheric specialization or simply represents a continuum from these. While it is only by on-line monitoring of brain metabolism during verbal and nonverbal cognitive activity in crossed dysphasics that it will be possible to definitively exclude the possibility of some residual left-hemisphere involvement in verbal or nonverbal functions, it would seem from the clinical evidence with regard to intact and impaired visuospatial function that in crossed dysphasia two main types of representation may occur: one (Type A) where most verbal and visuospatial functions appear to be "concentrated" into the right hem-



isphere (Haaland & Miranda, 1982) and a second type (Larrabee, Kane & Rogers, 1982) where there is a true "crossover" of hemisphere-specific psychological functions. In Type A crossed dysphasics, right-hemisphere damage may result in both verbal and nonverbal deficits, as in the patients reported here, whereas in Type B patients, dysphasia alone may be evident following a right-hemisphere lesion. The question remains as to which cognitive functions, if any, are subserved by the left hemisphere in Type A crossed dysphasics. (It is of note that our patient, in common with a number of reported cases, did not have limb apraxia, suggesting that left-hemisphere specialization for this area of functioning is independent of that for language and visuospatial skills.)

The present study afforded a unique opportunity for us to compare lesion distribution as seen on CT scan with that found on neuropathological investigation. In general there was a high degree of concordance between the two sets of measurements with the area of infarction on the CT scan corresponding closely to that found postmortem. A few lesions were, however, only evident on neuropathological investigation, especially those affecting limbic system structures. In particular the mammillary body on the right side was markedly reduced in size and the fact that our patient showed a moderate degree of generalized memory impairment is of note in view of the importance of mammillary body lesions in disorders such as Korsakoff's syndrome. These observations highlight the possible role of subcortical damage in contributing towards the memory difficulties which have sometimes been reported in dysphasic patients.

Numerous questions remain to be answered regarding the organization of psychological functions in crossed dysphasia. We do not know the distinctiveness or otherwise of the language impairment seen in crossed dysphasia compared to that found in either right-handed dysphasic patients with left-hemisphere lesions or left-handed dysphasic patients with right-hemisphere damage. It is possible that some dissociations between aspects of language function may occur more frequently in crossed dysphasics—e.g., our patient had agrammatic speech but good repetition and relatively preserved naming ability. It is also possible that dissociations between language and other functions may be more common in crossed dysphasia—e.g., our patient, in common with a number of previously reported cases, did not have significant limb or buccofacial apraxia. In addition, we do not know whether the pattern of language impairment differs in the two types of crossed dysphasia which we have postulated and whether visuospatial deficits, when they are present, differ from those typically found after right-hemisphere damage. At the neuroanatomical level, the relationship between size and site of lesion and the degree and type of language deficits may differ from that found in other dysphasic patients—it is of note that in our case there was considerable involvement of subcortical structures (cf. Habib, Joanelte, Ali-Cherif, & Poucet, 1983)

and there was also a contrast between the area and depth of lesion and the relatively mild extent of some aspects of his dysphasia. Finally, the study of crossed dysphasia may help to offer pointers to the limits of cerebral plasticity, since it would appear that language and visuospatial abilities in a normal individual can be controlled by a single hemisphere, without detriment to the level of functioning in either set of skills.

## REFERENCES

- Albert, M. L. 1973. A simple test of visual neglect. *Neurology*, **23**, 658–664.
- April, R. S., & Han, M. 1980. Crossed aphasia in a right-handed bilingual Chinese man. *Archives of Neurology*, **37**, 342–346.
- Assal, G., Perent, S. E., & Dervaz, J. P. 1981. Crossed aphasia in a right handed patient. *Archives of Neurology*, **38**, 455–458.
- Boller, F. 1973. Destruction of Wernicke's area without language disturbance. A fresh look at crossed dysphasia. *Neuropsychologia*, **11**, 243–246.
- Brown, J. W., & Wilson, F. R. 1973. Crossed aphasia in a dextral. *Neurology*, **23**, 907–911.
- Brust, J., Plank, C., Burke, A., Guobadia, M., & Heaton, E. 1982. Language disorder in a right hander after occlusion of the right anterior cerebral artery. *Neurology*, **32**, 492–497.
- Byrne, D. 1967. *Progressive picture compositions: Pupils' book*. London: Longman.
- Carr, M. S., Jacobson, T., & Boller, F. 1981. Crossed aphasia: Analysis of four cases. *Brain and Language*, **14**, 190–202.
- Galaburda, A. M., & Kemper, T. L. 1979. Cytoarchitectonic abnormalities in developmental dyslexia: A case study. *Annals of Neurology*, **6**, 94–100.
- Goodglass, H., & Kaplan, E. 1972. *The assessment of aphasia and related disorders*. Philadelphia: Lea & Febiger.
- Haaland, K. Y., & Miranda, F. 1982. Psychometric and CTscan measurements in a case of crossed dysphasia in a dextral. *Brain and Language*, **17**, 240–260.
- Habib, M., Joanelte, Y., Ali-Cherif, A., & Poucet, M. 1983. Crossed aphasia in dextrals: A case report with special reference to site of lesion. *Neuropsychologia*, **21**, 413–418.
- Kreindler, A., Fradis, A., & Sevastopol, N. 1966. La partition des dominances hemispheriques. *Neuropsychologia*, **4**, 143–149.
- Larrabee, G., Kane, R., & Rogers, J. 1982. Neuropsychological analysis of a case of crossed aphasia: Implications for reversed laterality. *Journal of Clinical Neuropsychology*, **4**, 131–142.
- Nelson, H., & O'Connell, A. 1978. Dementia: The estimation of premorbid intelligence levels using a new adult reading test. *Cortex*, **14**, 234–244.
- Trojanowski, J. Q., Green, R. C., & Levine, D. N. 1980. Crossed aphasia in a dextral: A clinicopathological study. *Neurology*, **30**, 709–713.
- Warrington, E. 1974. Deficient recognition memory in organic amnesia. *Cortex*, **10**, 289–291.
- Zangwill, O. 1979. Two cases of crossed aphasia in dextrals. *Neuropsychologia*, **17**, 167–172.