

Clinical Section

TOPOGRAPHIC ELECTROENCEPHALOGRAPHIC STUDY OF TRANSIENT ISCHEMIC ATTACKS

KEN NAGATA *, KAZUTA YUNOKI **, GORO ARAKI ** and MASAHIRO MIZUKAMI **

* *Department of Neurology, University of Colorado, Health Sciences Center, Denver, CO 80262 (U.S.A.)* and ** *Department of Neurology and Neurosurgery, Institute of Brain and Blood Vessels, Mihara Memorial Hospital, Iseaki, Gunma (Japan)*

(Accepted for publication: April 22, 1984)

A transient ischemic attack (TIA) is defined as an acute, evanescent neurological deficit which clears completely within 24 h (Millikan et al. 1975) and may serve a prodromic symptom or a warning sign that a completed stroke might occur (Loeb 1980). Much of the clinical data concerning TIAs is based on historical information gathered from the patients and their families. Such data may be inaccurate (Toole and Patel 1974). Moreover it may be difficult to carry out various clinical and laboratory examinations during the attacks because they are so short-lived.

Many attempts have been made to clarify the pathophysiological mechanism of TIA. The relationship between atherosclerosis of the cerebral vessels and TIA was studied using cerebral angiography (Alajouanine et al. 1960; Toole et al. 1975), however, the severity of atherosclerosis did not always correspond to the clinical symptomatology of TIAs. Although TIA was believed to occur without causing cerebral infarction, more recent CT studies often suggested that infarctions had occurred (Candelise et al. 1979; Araki et al. 1983). Furthermore regional cerebral blood flow (rCBF) studies demonstrated that the cerebral circulation was persistently impaired in some patients with TIAs even in their symptom-free period (Rees et al. 1970; Wong et al. 1973; Yonekura et al. 1981). Conventional reading of EEG showed abnormali-

ties in some TIA patients (Meyer et al. 1956; Kreindler et al. 1966; Enge et al. 1980). In the studies cited above, the evidence suggests that cerebral electrical activity does not recover completely within 24 h even though the clinical signs and symptoms of TIA had resolved.

However, the EEG and the rCBF measurements have shown correlations in ischemic cerebrovascular disease between cerebral electrical activity and cerebral circulation (Obrist et al. 1963; Ingvar 1967; Mosmans et al. 1973). Still, in comparison with CT, the results of conventional EEG reading were neither objective nor quantitative (Gevins et al. 1975).

Since Walter and Shipton (1951) reported their toposcope studies, many efforts have been made to obtain an objective, topographic, quantitative image of EEG data. Lehmann (1971) introduced a method of studying the multichannel topography of an alpha field using a general purpose computer with 48 electrodes. Equipotential contour lines were sketched by hand. Multichannel power spectral analysis was shown to help localize supratentorial lesions (Gotman et al. 1973). A ratio of slow wave activities to alpha and beta activities (as calculated from the power spectral data) was applied to the topographical representation of 'canonograms' (Gotman et al. 1975). Matsuoka et al. (1978) introduced a topographic display of slow wave activities with equipotential contour lines drawn by a computer. Duffy et al. (1979) introduced a color topographic image of the EEG power spectrum and evoked potential data. Modern quantitative

Corresponding address: Ken Nagata, M.D., Department of Neurology, B-182, University of Colorado, Health Sciences Center, 4200 East Ninth Avenue, Denver, CO 80262, U.S.A.

EEG analyses have been studied and compared with rCBF measurements in stroke patients (Ingvar et al. 1976; Tolonen and Sulg 1981). The present authors' previous study (Nagata et al. 1982) presented a method for topographic display of the EEG power spectrum which we called 'computed mapping of EEG' (CME). The results correlated well with CT and rCBF studies when applied to aphasic patients with ischemic cerebrovascular disease. We have shown that the CME gives additional useful information when correlated with rCBF measurements and CT in ischemic cerebrovascular disease.

The purpose of the present study is two-fold: (1) to investigate the brain electrical activity in TIA following the symptom-free period (special affection is paid to the reversibility of the cerebral function, correlating the CME with rCBF measurements using the ^{133}Xe intracarotid injection method); (2) to a comparison between the results of CME with those of conventional EEG interpretation.

Subjects and Methods

This study is based on 25 patients with TIAs out of 2000 cases who underwent conventional and topographic EEG examination at the Institute of Brain and Blood Vessels, Mihara Memorial Hospital. All 25 patients had TIAs limited to the internal carotid arterial system. Their mean age was 57 (33–78) years. In all patients who were admitted to the hospital a CT scan, cerebral angiography, platelet aggregation studies, along with conventional EEG studies and topographic displays of EEG using the CME were performed. Regional cerebral blood flow (rCBF) studies were also done on 10 patients simultaneously with cerebral angiography. Anti-platelet aggregation therapy (ticlopidine or aspirin) was started immediately after these examinations. No patient developed further TIAs or a completed stroke after this therapy was started.

The CME-100 (Japan System/Nissei Sangyo) consists of a computer, a color monitor and a printer. This unit is interfaced with a 17-channel EEG polygraph (1A56 San-ei Sokki) which in turn

is connected to the patients. A special 16-lead montage based on the International 10-20 system is used which omits T3, T4 and Cz and utilizes the chin or both ear lobes as the reference. This configuration allows the recording of a conventional EEG tracing and the computation of a CME.

The CME provides a two-dimensional topographic color coded display of the average power associated with 6 separate segments of the EEG frequency spectrum between 2.0 and 29.5 Hz. To eliminate contamination by eye movement artefact, slow (delta) activity below 2.0 Hz was excluded from the analysis. The frequency spectrum is divided into the following categories: delta (2.0–3.5 Hz), theta (4.0–7.5 Hz), α_1 (8.0–9.5 Hz), α_2 (10.0–12.5 Hz), β_1 (13.0–19.5 Hz) and β_2 (20.0–29.5 Hz). The power spectrum for each of these frequency categories is divided into 11 color-coded levels, the lowest power shown in blue and the highest in red. The power differential between two successive levels ranged from 1.0 to 2.0 μV . Thus if the power differential is set at 1.0 μV , then red areas designate values excess of 10.0 μV and dark blue ones indicate 0 μV . In this study, asymmetrical power depression of background activity by more than 3 levels at two corresponding areas was regarded as an abnormal asymmetry of background activity in the CME.

The CME acquires data from the 16 leads over 120 sec in sixty 2 sec epochs. This procedure for data acquisition provided good reproducibility as shown in our previous report (Nagata et al. 1982). The Fast Fourier Transform (FFT) is used on-line to calculate the average power spectra for each of the frequency categories.

The interpolated power data between electrodes are generated according to the modified method of Ueno and Matsuoka (1976). After sampling EEG data the system requires 1 sec for processing and 7 sec to display all 6 two-dimensional topographic maps in terms of color-coded isopower areas in color TV screen.

Hard copies were made photographically as well as with the on-line monochromatic printer which fills in the isopower areas of the maps with 11 different characters representing the 11 different colors.

Conventional reading of the EEG was carried

out by an electroencephalographer who was 'blind' to the clinical data save for the patients' age. Subsequently the results of conventional reading were compared with those of the CME, both of which were then compared to the clinical data for the appropriateness of lateralization. Ten patients had rCBF studies using the ^{133}Xe intracarotid injection method and a 16-channel scintillation detector system (Cerebrograph Meditronic). The initial flow values were calculated according to the initial slope index (ISI) method in the analysis. Normal flow value in this system averaged 62.3 ml/100 g/min with a standard deviation of 11.8 ml/100 g/min.

Illustrative case report

Case I.K. This 44-year-old office worker suddenly noticed a weakness of his right arm and leg while driving to his office in the morning. His right hemiparesis improved and disappeared within 1 h. When first seen at the hospital, he displayed no neurological deficit and his speech was normal. His grasping power was 45 kg in both hands. A CT scan demonstrated no abnormality. However, cerebral angiography performed 4 h after the attack revealed a mild stenotic lesion at the intracavernous portion of the left internal carotid artery. Regional cerebral blood flow measurement performed simultaneously with the angiography showed the mean left hemispheric flow to be 62 ± 8.2 ml/100 g/min (within normal limit) as well as normal regional values. However, the topographic EEG by CME, taken 6 h after the attack, showed an asymmetrical distribution of the α_1 activity with power depression on the left side relative to the right. This was felt to indicate an impairment of brain electrical activity in the left hemisphere. Ticlopidine, 200 mg daily, was given to prevent further attacks. The patient has been free from further TIAs since therapy began and had not developed a completed stroke. A series of CMEs revealed an asymmetrical distribution of depression of power in the α_1 and α_2 components over the left hemisphere when tested 10 days, 29 days and 61 days after the attack. The CME became normal with a symmetrical distribution of power over both hemispheres 149 days following the TIA (Fig. 1).

Results

Clinical and neuroradiological data of TIAs

Eighteen patients (72%) experienced a transient right hemi- or monoparesis, two of whom (8%) also had a transient dysphasia; 7 (28%) presented with a transient left hemiparesis. Eight patients (32%) experienced only one attack of TIA. Cerebral angiography was carried out in all patients. No abnormality was seen in 14 patients (56%). Six patients (24%) had a stenosis of the middle cerebral artery, and 2 patients (8%) were found to have an occlusion of the internal carotid. A stenosis of the internal carotid artery, a stenosis of the anterior cerebral artery and an unruptured aneurysm were found in 1 patient (4%), respectively. These angiographic abnormalities were appropriately lateralized to the side of TIAs. Twenty-three patients (92%) showed normal CT finding; 2 patients (8%) had a small infarct of the basal ganglia also appropriate to the clinical lateralization.


Comparison of the results of conventional reading of EEG and CME (Table I)

Both methods of EEG interpretation demonstrated symmetrical alpha activity, symmetrical low voltage beta activity, and diffuse theta (slow alpha) activity without lateralization, in 2 patients (8%), 1 patient (4%), 2 patients (8%), respectively. Slow wave (theta) foci were detected in 8 patients (32%) by both methods, 6 of whom showed appropriate lateralization to the side of TIAs. Conventional reading of the EEG revealed sporadic theta activity in 2 patients (8%), which was not

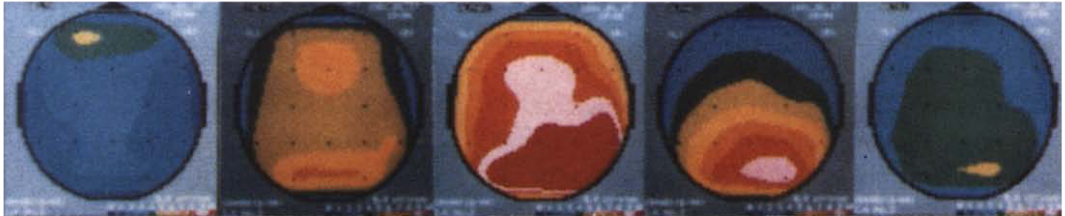TABLE I

Comparison of the results of conventional EEG reading and CME. Numbers in parentheses indicate patients in whom the results were appropriately correlated with the side of TIAs.

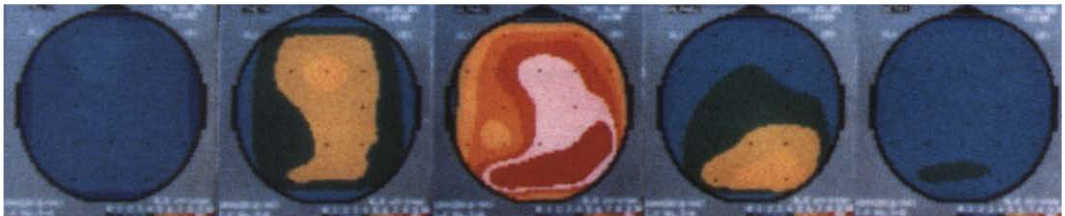Findings	Conventional CME EEG reading	
Symmetrical alpha	2 (0)	2 (0) cases
Low voltage beta	1 (0)	1 (0)
Diffuse theta	2 (0)	2 (0)
Asymmetrical depression of alpha	10 (9)	12 (10)
Slow wave foci	8 (6)	8 (6)
Sporadic theta	2 (1)	0 (0)
	25 (16) 64%	25 (17) 68%

6 hours
after TIA

10 days



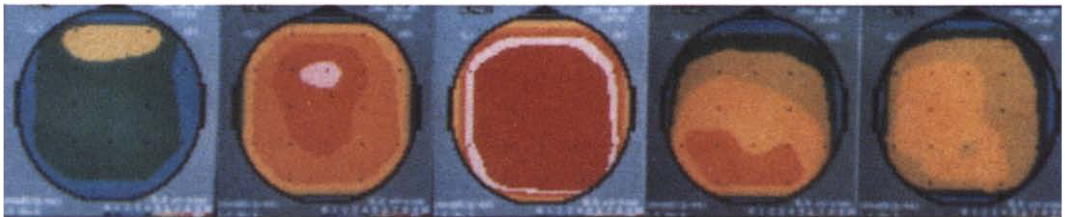
29 days



61 days



49 days



Delta

Theta

Alpha 1

Alpha 2

Beta 1

Fig. 1. Time course of CME findings in a patient with TIA of right hemiparesis (Case I.K.). An asymmetrical depression of power in α_1 and α_2 components is shown over the left hemisphere 6 h, 10 days, 29 days and 61 days after the TIA. The CME became normal with a symmetrical distribution of power over both hemispheres 149 days after the TIA.

detected by CME. The CME demonstrated asymmetrical distribution of alpha activity with power depression in 12 patients (48%), and in 10 of them the unilateral depression of alpha power corresponded to the side of TIAs. In the conventional EEG interpretation asymmetrical alpha activity was shown in 10 patients (40%). There was an agreement among the interpreters that the asymmetry of the background activity was more consistently obvious in the CME than in the conventional tracings. Consequently, the unilateral abnormalities were appropriate to the side of TIAs in 16 patients (64%) in the conventional reading of EEG whereas the CME demonstrated appropriate lateralization in 17 patients (68%).

Relationships between the lateralization in CME, and the frequency of TIAs, the angiographic data, CT findings and the timing of examinations (Table II)

The appropriate lateralization of the CME findings to the side of TIAs was seen in 63%, 71% and 70% of patients with only one TIA, those with 2 TIAs, and those with more than 3 TIAs, respectively. There were no CME findings that specifi-

TABLE II

Relationship between unilateral abnormalities in CME, and the frequency of TIAs, angiographic findings, CT findings, and the timing of the CME examination. Appropriateness of lateralization in CME is compared among above factors.

	Number of patients with appropriate lateralization	Total number of patients	
<i>Frequency of TIAs</i>			
One	5	8	63%
Two	5	7	71%
More than three	7	10	70%
<i>Angiographic findings</i>			
Normal	8	14	57%
Abnormal	9	11	82%
<i>CT findings</i>			
Normal	15	23	65%
Small infarction	2	2	100%
<i>Timing of examination</i>			
Within 2 weeks	7	8	88%
Later than 2 weeks	10	17	59%

cally related to the frequency of TIAs. The patients with angiographical abnormalities showed higher incidence of the appropriate lateralization (82%) than those with normal angiogram (57%). Each of the two patients (100%) with a small infarction on CT showed appropriate lateralization which dropped to 65% in those with normal CT findings. The patients who were tested within 2 weeks of the last TIA showed higher incidence of the appropriate lateralization (88%) than those tested more than 2 weeks after the last TIA (59%). There was a tendency that unilateral abnormalities in CME might correspond to the side of TIAs, when the patients were tested within 2 weeks of the last attack, or when they showed abnormalities on angiogram or CT scan.

Correlation between CME and rCBF

Table III shows a list of 10 patients who had both CME and rCBF studies. These studies were performed from 6 h to 54 days after the last attack. Eight patients out of 10 had occlusive lesions on their angiogram, but none of them showed abnormal CT findings. Of this group of patients unilateral abnormalities on CME were found in 7 of the 10, all of which appropriate to their TIA symptoms. The mean hemispheric blood flow was normal in 7 patients, 6 of whom were examined more than 5 days after the last attack. Three patients including two who had dysphasia in addition to hemiparesis showed mild to moderate reduction of cerebral blood flow (58–69% of the normal flow value) over the appropriate hemisphere. These same 3 patients had a stenotic lesion of the middle cerebral artery as well as the corresponding abnormalities on CME.

Discussion

Unilateral EEG findings commonly seen with acute cerebral infarction are polymorphic delta activity and asymmetrical distribution of background activity with ipsilateral voltage depression (Van der Drift 1972). We analyzed the relationship between the side of the unilateral EEG and CME abnormalities and the side of the lesions suspected on clinical grounds. Sixty-eight percent of the pa-

TABLE III
A list of 10 TIA patients with angiography, CT, rCBF and CME findings.

Case	Age/sex	Symptoms of TIAs	Frequency of TIAs	Timing of exam	Angiographic findings	CT findings	Mean rCBF	Lesion side on CME
1	44/m	right hemiparesis	1	6 h	left ICA stenosis	normal	62 ± 8.2	left (alpha asymmetry)
2	44/m	right hemiparesis *	4	6 h	left MCA stenosis	normal	43 ± 7.5	left (alpha asymmetry)
3	58/m	left hemiparesis	2	3 days	right MCA stenosis	normal	42 ± 5.0	right (alpha asymmetry)
4	78/f	right monoparesis *	many	4 days	left MCA stenosis	normal	36 ± 5.2	left (alpha asymmetry)
5	50/f	left hemiparesis	1	4 days	normal	normal	64 ± 7.4	normal symmetrical alpha
6	52/m	left hemiparesis	3	9 days	right MCA stenosis	normal	63 ± 5.8	left (alpha asymmetry)
7	44/m	right hemiparesis	2	28 days	left MCA stenosis	normal	59 ± 2.8	left (alpha asymmetry)
8	42/m	left hemiparesis	2	37 days	normal	normal	61 ± 5.1	right (theta focus)
9	47/m	left hemiparesis	2	50 days	right ICA stenosis	normal	57 ± 5.8	low voltage beta
10	46/m	left hemiparesis	2	54 days	right MCA stenosis	normal	54 ± 9.0	diffuse theta
	51 ± 11 years			19 ± 21 days			54 ± 10.0 ml/100 g/min	

* Right hemiparesis (monoparesis) with aphasic syndrome.

ICA, internal carotid artery; MCA, middle cerebral artery; mean rCBF, mean hemispheric blood flow in the lesion side.

tients with TIAs showed unilateral abnormalities on CME corresponding with their clinical symptoms in spite of the fact that they were completely free of any neurological deficits. Eighty-eight percent of those who were examined within 2 weeks of the last TIA showed corresponding unilateral CME abnormalities. This figure dropped to 50–67% two or more weeks after the last TIA. The above results show that EEG abnormalities could be found in high percentage of patients having had a TIA even after the clinical symptoms have disappeared completely.

Similar data were obtained in previous studies of TIA patients using the conventional method of the EEG interpretation. Ott et al. (1980) reported that there was a high incidence (71.4%) of EEG slow wave activity in 14 TIA patients. Ottonello et al. (1980) found ipsilateral EEG abnormalities, including delta activity, background depression and theta activity, in 80.1% of 15 patients with TIAs. In the study of 295 TIA patients by Enge et al. (1980), 56.3% of patients had abnormal EEG findings, including 12 patients with generalized and 140 patients with focal EEG changes in their symptom-free period. These facts suggest that an impairment of brain electrical activity persists long after the clinical signs and symptoms have resolved.

However, in the early literature when the concept of TIA was ambiguous such that patients with persistent neurological deficits might be included in a study on TIAs, fewer EEG abnormalities were found as compared to more recent reports. For instance, 57% of the patients with carotid insufficiency studied by Meyer et al. (1956) showed a normal resting EEG record; the EEG was normal in 71% patients with recurrent cerebral ischemic attacks reported by Birchfield et al. (1959) and 62% of those with recurrent focal cerebral ischemic attacks showed normal EEG, according to Paddison and Ferriss (1961). There is thus a discrepancy between these early reports and the present study.

When in the present study, CME was compared with conventional EEG interpretation symmetrical findings, including normal symmetrical alpha activity, symmetrical low voltage beta activity, and diffuse theta activity without localization were detected with equal frequency with both methods.

A focus of slow wave activity (mostly theta) was recognized in 8 patients by both methods of interpretation. These slow wave foci correlated with the side of the lesions in 6 of the 8 patients and the slow wave foci appeared on the opposite side of the lesion in the remaining 2 patients. Two patients showed appropriately lateralized sporadic theta activity in the conventional EEG tracing which was not recognized in the CME. In CME sporadic or transient activities with low amplitude tend to be lost in the 120 sec domain of accumulation used for power spectral analysis. With regard to the detection of sporadic activities, the conventional reading of the EEG was considered to be superior to the CME. On the other hand, an asymmetrical distribution of alpha (background) activity was found in 12 patients on CME while it was found in only 10 patients on conventional EEG tracing. Both methods identified one patient with voltage depression of background activity on the side opposite that predicted by the clinical symptoms. Power spectral analysis was found to be more sensitive for detecting voltage asymmetry of background activity than was the conventional EEG, a result is in agreement with the previous report by Matoušek and Petersén (1973). It must be emphasized, however, that corresponding unilateral abnormalities were found in 68% and 64% of the patients by the CME and by conventional EEG reading respectively, i.e., both methods give comparable results in terms of simply identifying non-transient unilateral EEG abnormalities. Using the CME system, the EEG data can be represented as an objective, quantitative and topographic image which provides the same or more useful information as the conventional EEG interpretation by a skillful reader.

There is still a controversy concerning the pathogenesis of TIAs. Denny-Brown (1951) stressed the role of hemodynamic factors and introduced the term 'cerebrovascular insufficiency.' Millikan et al. (1955) suggested that TIAs were caused by microemboli due to ulcerated plaques. This concept has been widely accepted. With either microemboli or non-embolic hemodynamic factors, focal cerebral ischemia might occur in superficial cortical branches of cerebral arteries.

In our results, 10 of 23 patients who had nor-

mal CT findings showed atherosclerotic lesions in their major cerebral arteries. The suspicion was that transient ischemia in these patients was secondary to microemboli such as described by Adams and Gross (1981). Eight of these 10 patients showed asymmetrical depression of alpha activity in CME. On the other hand, CT revealed a small infarction in the basal ganglia of 2 patients who had no atherosclerotic lesion in their major cerebral arteries. They were suspected of having focal cerebral ischemia deep in the brain. As we reported previously (Araki et al. 1983), the results of these two patients suggest that small deep infarcts can present clinically as TIAs. Both of these patients showed theta activity on the side of the lesion on CME, which was considered to be a slowing of the background activity. Although focal or unilateral EEG abnormalities do not establish the nature of the underlying pathology, they may ultimately prove helpful in differentiating between pathogenetic mechanisms of TIA, as more data are collected.

The relationship between depth of the lesions and changes on the EEG has been studied both in clinical and laboratory settings. Roseman et al. (1952) initially suggested that the delta activity may indicate a more superficial lesion and that an asymmetrical distribution of background activity may reflect a deeper lesion. Contrary to this, Gloor et al. (1977) demonstrated in animal studies, that localized lesions of the subcortical white matter produce typical polymorphic delta activity as a result of unspecified cortical deafferentation, and that purely cortical lesions cause amplitude depression of the background activity. A similar conclusion was drawn by Goldensohn (1979) based on a clinico-pathological study of patients with brain tumors. Continuous focal polymorphic delta activity was thought to indicate a destructive lesion in cerebral white matter. However, Ottonello et al. (1980) reported that the incidence of delta activity was higher in superficial than in deep infarctions in patients with acute cerebrovascular lesion. Furthermore, large infarctions involving the cerebral cortex on CT correlated with delta foci on CME, and asymmetrical depression of alpha activity was seen in both large cortical infarctions and in subcortical infarctions on the topographic EEG

study of aphasic patients (Nagata et al. 1982). The authors did not find a simple relationship between the depth of the lesions and resulting EEG abnormalities in patients with cerebral infarction. In the present study, patients who were suspected of having ischemia near the surface of the brain showed asymmetrical depression of background activity. The tendency that depression of background activity correlates with cortical lesions was clearly demonstrated also in the CME. Two patients with small infarcts in the basal ganglia showed theta activity on the side of the lesion, and no patient displayed polymorphic delta activity. A mild slowing of background activity was found to correlate with subcortical lesions. This result was in accordance with the EEG findings associated with lacunar infarcts (Caplan and Young 1972).

In experimental studies posts ischemic blood flow appears important for the recovery of neuronal function (Hossmann and Kleihues 1973). However, a chronic disturbance of cerebral circulation was found in TIA patients who had recovered completely from neurological deficits (Rees et al. 1970; Wong et al. 1973; Yonekura et al. 1981). From observations in 12 TIA patients with the ^{133}Xe intracarotid rCBF method, Skinhøj et al. (1970) demonstrated that the cerebral circulation may recover well after the clinical symptoms disappear in TIA. Bruens et al. (1960) also pointed out that an impending decompensation of cerebral circulation may cause further ischemic episodes in patients with TIAs.

In our study, 3 patients who underwent rCBF studies within 4 days of the last attack had reduced cerebral blood flow as well as an asymmetric depression of alpha activities in CME, in spite of their normal CT findings. The two patients whose TIA symptoms included an aphasic syndrome in addition to hemiparesis were among those who had reduced cerebral blood flow. There was a good correlation between reduction of cerebral blood flow and ipsilateral depression of background EEG activity in the absence of CT lesions. It has been accepted that slowing of background activity correlates with reduction of cerebral blood flow in cerebral ischemia in human (Mosmans et al. 1973; Ingvar et al. 1976). However, experimental studies by Tulleken et al. (1978)

showed that reduction of rCBF correlated with decrease in the EEG power spectra over the ischemic region, and that the decrease in power was greater for the faster frequencies than for the slower frequencies. Our results are in agreement with their observation.

The mean hemispheric flow values in our 3 patients with hypoperfusion ranged from 58% to 69% of normal flow values. These values were higher than the critical flow levels which are assumed to cause neuronal dysfunction (Kawase et al. 1980). In these 3 patients a residual impairment of cerebral circulation and electrical dysfunction remained in the wake of a transient ischemic event even after the neurological deficits had cleared.

In contrast to the above observation, 4 of 7 patients with normal rCBF values and normal CT finding showed unilateral abnormalities in CME; the relationship between cerebral blood flow and brain electrical activity was poor in these cases. Ott et al. (1980) reported that 92.8% of TIA patients showed a focal disturbance of cerebral circulation which included mainly disturbance in focal autoregulation following hyperventilation, and that 71.4% of the patients showed EEG slow wave activity. In their study, a good correlation between reduced rCBF and focal EEG abnormalities was found in 50% of their TIA patients. Based on the limited number of patients subjected to both EEG and rCBF studies in this report, it appears that electrical dysfunction, not focal hypoperfusion, is the more likely 'foot print' left in the wake of a TIA, though admittedly autoregulatory responses were not tested.

Summary

Twenty-five patients with TIAs in the carotid artery distribution were studied by means of computed mapping of EEG (CME) and conventional EEG. In addition, CT scan and cerebral angiography, and in 10 patients rCBF measurements were performed. The CME provided topographic maps of the average power spectra for each of 6 frequency bands from 2.0 to 29.5 Hz which were displayed two-dimensionally in a color-coded isopower format. EEG abnormalities were analyzed

and the results of the two different methods of EEG interpretation were compared.

Sixty-eight percent of the patients showed unilateral abnormalities on CME appropriately lateralized to the clinical symptoms even after these symptoms had cleared completely. Furthermore, 88% of those who were examined within 2 weeks of last TIA showed corresponding CME abnormalities. Only 3 out of 10 TIA patients who had rCBF studies showed reduction of blood flow on the appropriate hemisphere, whereas 7 of the 10 patients had corresponding CME abnormalities.

Comparing the results of the CME and of conventional EEG reading revealed the CME to be slightly more sensitive in detecting asymmetrical voltage depression of background activity than the conventional reading of the EEG, while the latter detected low amplitude sporadic activities which were missed by CME. Both methods were equally sensitive in detecting slow wave foci and non-transient symmetrical changes.

The two most significant points of this report are the following: first, 68% of the TIA patients studied had residual unilateral abnormalities in CME in their symptom-free period. In the subset of patients subjected to rCBF studies only 30% showed residual flow aberrations, whereas 70% of the same subset demonstrated unilateral abnormalities in CME. Second, though conventional EEG reading by an experienced electroencephalographer can nearly match the performance of CME the CME format makes subtle but useful EEG findings readily available to the uninitiated. The CME also quantifies the data making objective comparisons more amenable to software manipulations for further studies.

Résumé

Etude électroencéphalographique topographique après attaque ischémique transitoire

Vingt-cinq patients avec ischémie passagère de la distribution artérielle carotidienne ont été étudiés en utilisant la cartographie EEG computerisée ainsi que l'EEG conventionnel. De plus,

un scanner et une angiographie cérébrales et chez 10 patients, des mesures du débit sanguin cérébral local ont été effectués. La cartographie de l'EEG fournit la répartition topographique de la moyenne du spectre de puissance pour chacune des 6 bandes de fréquence de 2,0 à 29,5 Hz; ces cartes sont présentées en deux dimensions et avec un code des couleurs pour les zones de même puissance. Les anomalies EEG ont été analysées et les résultats des deux différentes méthodes d'interprétation de l'EEG ont été comparées.

Soixante-huit pour cent des patients ont présenté des anomalies unilatérales de leur cartographie EEG, latéralisées en fonction des symptômes cliniques, même après la disparition complète de ces symptômes. De plus, 88% de ceux qui ont été examinés dans les 2 semaines suivant leur dernière ischémie ont présenté des anomalies correspondantes de leur cartographie EEG. Trois seulement des 10 patients avec ischémie qui avaient subi des mesures de débit sanguin cérébral ont témoigné d'une réduction de ce débit dans l'hémisphère correspondant alors que 7 de ces 10 patients présentaient des anomalies EEG correspondantes.

La comparaison des résultats de la cartographie sur ordinateur et de la lecture de l'EEG conventionnel a révélé une sensibilité légèrement plus grande de la première méthode pour la détection d'une baisse asymétrique d'amplitude de l'activité de base, alors que l'EEG conventionnel a détecté des activités sporadiques de basse amplitude négligées par la cartographie. Les deux méthodes se sont révélées de sensibilité équivalente pour la détection de foyers d'ondes lentes et de modifications symétriques durables.

Les deux points les plus significatifs de ce travail sont les suivants: premièrement, 68% des patients avec ischémie artérielle passagère ont présenté des anomalies unilatérales résiduelles dans leur cartographie EEG au cours de période sans symptôme clinique. Dans le sous-groupe de patients ayant subi des mesures de débit sanguin cortical, 30% seulement ont montré des anomalies persistantes de leur flux alors que 70% de ce même sous-groupe présentaient des anomalies unilatérales de leur cartographie EEG. Deuxièmement, bien que la lecture de l'EEG conventionnel par un EEGiste expérimenté puisse à peu près atteindre la perfor-

mance de la cartographie EEG effectuée sur ordinateur, des données EEG subtiles mais utiles peuvent être aisément mises en évidence par cette dernière méthode et sont ainsi disponibles pour le non initié. Cette cartographie quantifie également les données rendant les comparaisons objectives plus faciles à établir lors d'études ultérieures.

References

- Adams, H.P. and Gross, C.E. Embolization distal to stenosis of the middle cerebral artery. *Stroke*, 1981, 12: 228–230.
- Alajouanine, T.H., Lehermitte, F. and Gautier, J.C. Transient cerebral ischemia in atherosclerosis. *Neurology (Minneapolis)*, 1960, 10: 906–914.
- Araki, G., Mihara, H., Shizuka, M., Yunoki, K., Nagata, K., Yamaguchi, K., Mizukami, M., Kawase, T. and Tazawa, T. CT and angiographic comparison of patients with transient ischemic attacks, correlation with small infarction of basal ganglia. *Stroke*, 1983, 14: 276–280.
- Birchfield, R.I., Wilson, W.P. and Heyman, A. An evaluation of electroencephalography in cerebral infarction and ischemia due to arteriosclerosis. *Neurology (Minneapolis)*, 1959, 9: 859–871.
- Bruens, J.H., Gastaut, H. and Giove, G. Electroencephalographic study of the signs of chronic vascular insufficiency of the Sylvian region in aged people. *Electroenceph. clin. Neurophysiol.*, 1960, 12: 283–295.
- Candelise, L., Perrone, P. and Scotti, G. Computer tomographic findings in TIA patients. In: J.S. Meyer, H. Lechner and M. Revich (Eds.), *Cerebral Vascular Disease 2*, 9th Salzburg Conference. Excerpta Medica, Amsterdam, 1979: 81–86.
- Caplan, L.R. and Young, R.R. EEG findings in cerebral lacunar stroke syndrome. *Neurology (Minneapolis)*, 1972, 22: 403.
- Denny-Brown, D. The treatment of recurrent cerebrovascular symptoms and the question of vasospasm. *Med. Clin. N. Amer.*, 1951, 35: 1457–1474.
- Duffy, F.H., Burchfield, J.L. and Lombroso, C.T. Brain electrical activity mapping (BEAM): a method for expanding the clinical utility of EEG and evoked potential data. *Ann. Neurol.*, 1979, 5: 309–321.
- Enge, S., Lechner, H., Logar, C.H. and Laduener, G. Clinical value of EEG in transient ischemic attacks. In: H. Lechner and A. Aranibar (Eds.), *EEG and Clinical Neurophysiology*. Excerpta Medica, Amsterdam, 1980: 173–180.
- Gevins, A.S., Yeager, C.L., Diamond, S.L., Spire, J., Zeitlin, G.M. and Gevins, A.H. Automated analysis of the electrical activity of the brain (EEG): a progress report. *Proc. IEEE*, 1975, 63: 1382–1399.
- Gloor, P., Ball, G. and Schaul, N. Brain lesions that produce delta waves in the EEG. *Neurology (Minneapolis)*, 1977, 27: 326–333.
- Goldensohn, E.S. Use of the EEG for evaluation of focal intracranial lesions. In: D.W. Klass and D.D. Daly (Eds.), *Current Practice of Clinical Electroencephalography*. Raven Press, New York, 1979: 307–341.
- Gotman, J., Skuce, D.R., Thompson, C.J., Gloor, P., Ives, J.R. and Ray, W.F. Clinical application of spectral analysis and extraction of features from electroencephalograms with slow waves in adult patients. *Electroenceph. clin. Neurophysiol.*, 1973, 35: 225–235.
- Gotman, J., Gloor, P. and Ray, W.F. A quantitative comparison of traditional reading of the EEG and interpretation of computer-extracted features in patients with supratentorial brain lesions. *Electroenceph. clin. Neurophysiol.*, 1975, 38: 623–639.
- Hossmann, K.A. and Kleihues, P. Reversibility of ischemic brain damage. *Arch. Neurol. (Chic.)*, 1973, 29: 375–384.
- Ingvar, D.H. The pathophysiology of occlusive cerebrovascular disorders related to neuroradiological findings, EEG and measurements of regional cerebral blood flow. *Acta neurol. scand.*, 1967, 43 (Suppl. 31): 93–107.
- Ingvar, D.H., Sjölund, B. and Ardo, A. Correlation between dominant EEG frequency, cerebral oxygen uptake and blood flow. *Electroenceph. clin. Neurophysiol.*, 1976, 41: 268–276.
- Kawase, T., Mizukami, M., Araki, G. and Nagata, K. Critical flow level in cerebral ischemia. I. Occlusive cerebrovascular disease. *Brain Nerve (Tokyo)*, 1980, 32: 1247–1255.
- Kreindler, A., Pollici, I. and Marinchesu, M. Electroencephalographic study of cerebral transient ischemic attacks. *Confin. neurol. (Basel)*, 1966, 28: 385–398.
- Lehmann, D. Multichannel topography of human alpha fields. *Electroenceph. clin. Neurophysiol.*, 1971, 31: 439–449.
- Loeb, C. Protracted transient ischemic attacks. *Europ. Neurol.*, 1980, 19: 1–11.
- Matoušek, M. and Petersén, I. Automatic evaluation of EEG background activity by means of age-dependent EEG quotients. *Electroenceph. clin. Neurophysiol.*, 1973, 35: 603–612.
- Matsuoka, S., Aragaki, Y., Numaguchi, K. and Ueno, S. Effect of dexamethasone on electroencephalograms in patients with brain tumor. *J. Neurosurg.*, 1978, 48: 601–608.
- Meyer, J.S., Leiderman, H. and Denny-Brown, D. Electroencephalographic study of insufficiency of the basilar and carotid arteries in man. *Neurology (Minneapolis)*, 1956, 6: 455–477.
- Millikan, C.H., Siekert, R.C. and Shick, R.M. Studies in cerebrovascular disease. V. The use of anticoagulant drugs in the treatment of intermittent insufficiency of the internal carotid arterial system. *Mayo Clin. Proc.*, 1955, 30: 578–586.
- Millikan, C.H. et al. Ad Hoc Committee on cerebrovascular disease, A classification and outline of cerebrovascular disease, Part II. *Stroke*, 1975, 6: 565–616.
- Mosmans, P.C.M., Jonkman, E.J., Magnus, O. and Van Huffelen, A.C. Regional cerebral blood flow and EEG. *Electroenceph. clin. Neurophysiol.*, 1973, 33: 122.
- Nagata, K., Mizukami, M., Araki, G., Kawase, T. and Hirano, M. Topographic electroencephalographic study of cerebral infarction using computed mapping of the EEG (CME). *J. Cereb. Blood Flow Metab.*, 1982, 2: 79–88.
- Obrist, W.D., Sokoloff, L., Lassen, N.A., Lane, M.H., Butler, R.N. and Feinberg, I. Relation of EEG to cerebral blood flow and metabolism in old age. *Electroenceph. clin. Neurophysiol.*, 1963, 15: 610–619.

- Ott, E., Lechner, H., Marguc, K., Bertha, G., Aranibar, A., Landurner G. and Sager, W.D. Correlation of EEG and CT findings with cerebral blood flow measurements in patients with cerebrovascular disorders. In: H. Lechner and A. Aranibar (Eds.), *EEG and Clinical Neurophysiology*. Excerpta Medica, Amsterdam, 1980: 143–147.
- Ottonello, G.A., Regeasta, G. and Tanganelli, P. Correlation between computed tomography and EEG findings in acute cerebrovascular disorders. In: H. Lechner and A. Aranibar (Eds.), *EEG and Clinical Neurophysiology*. Excerpta Medica, Amsterdam, 1980: 148–162.
- Paddison, R.M. and Ferriss, G.S. The electroencephalogram in cerebrovascular disease. *Electroenceph. clin. Neurophysiol.*, 1961, 13: 99–110.
- Rees, J.H., Du Boulay, G.H., Bull, J.W.B., Marshall, J., Russel, R.W.R. and Symon, L. Regional cerebral blood flow in transient ischaemic attacks. *Lancet*, 1970, ii: 1210–1213.
- Roseman, F., Schmidt, R.P. and Foltz, E.L. Serial electroencephalography in vascular lesions of the brain. *Neurology (Minneap.)*, 1952, 2: 311–331.
- Skinhøj, E., Hoedt-Rasmussen, K., Paulson, O.B. and Lassen, N.A. Regional cerebral blood flow and its autoregulation in patients with transient focal cerebral ischemic attacks. *Neurology (Minneap.)*, 1970, 20: 485–493.
- Tolonen, U. and Sulg, I.A. Comparison of quantitative EEG parameters from four different analysis techniques in evaluation of relationship between EEG and rCBF in brain infarction. *Electroenceph. clin. Neurophysiol.*, 1981, 51: 177–185.
- Toole, J.F. and Patel, A.N. *Cerebrovascular Disorders*. McGraw-Hill, New York, 1974: 187–197.
- Toole, J.F., Janeway, R., Choi, K., Davis, C., Johnston, F. and Miller, H.S. Transient ischemic attacks due to atherosclerosis. A prospective study of 160 patients. *Arch. Neurol. (Chic.)*, 1975, 32: 5–12.
- Tulleken, C.A.F., Van Dieren, A., Ten Veen, J. and Lopes da Silva, F.H. Changes in local EEG, local cerebral blood flow and flow in the distal stump of the middle cerebral artery in cats with an occlusion of the middle cerebral artery. In: B. Van Eijnsbergen and F.H. Lopes da Silva (Eds.), *Progress Report Institute of Medical Physics TNO*, Vol. 6. TNO, Utrecht, 1978: 102.
- Ueno, S. and Matsuoka, S. Topographic display of slow wave types of EEG abnormality in patients with brain lesions. *Jap. med. Electr. Bio-Engng*, 1976, 14: 118–124.
- Van der Drift, J.H.A. The EEG in cerebrovascular disease. In: P.J. Vinken and G.W. Bruyn (Eds.), *Handbook of Clinical Neurology*, Vol. 11. North-Holland, Amsterdam, 1972: 267–291.
- Walter, W.G. and Shipton, H.W. A new toposcopic display system. *Electroenceph. clin. Neurophysiol.*, 1951, 3: 281–292.
- Wong, E., Bull, J.W.B., Du Boulay, G.H., Marshall, J., Russel, R.W.R. and Symon, L. Regional cerebral blood flow in completed strokes and transient ischemic attacks. A clinical correlation. *Neurology (Minneap.)*, 1973, 22: 949–952.
- Yonekura, M., Austin, G., Poll, N. and Hayward, W. Evaluation of regional cerebral blood flow in patients with transient ischemic attacks and minor stroke. *Surg. Neurol.*, 1981, 15: 57–65.