

Short report

Mutism following left hemisphere infarction

AS DAVID,* I BONE

From the Department of Neurology, Institute of Neurological Sciences, Southern General Hospital, Glasgow, UK

SUMMARY A case of mutism due to left hemisphere infarction is described. Recovery revealed mild motor dysphasia. Review of the literature showed that the case resembles aphemia but is unique by virtue of its duration, and the absence of associated apraxia and paresis.

Mutism is a rare clinical entity. It may occur transiently in lesions of Broca's area,¹ or the inferior Rolandic region.² We describe a case of total mutism following left common carotid artery occlusion in the absence of hemiparesis and oro-bucco-lingual apraxia which we believe to be due to a highly specific apraxia of speech.

Case report

A 51-year-old, right-handed housewife, with a history of controlled hypertension, was on holiday abroad when she awoke, unable to speak. A relative noticed right sided facial weakness. On her return, the patient was admitted to her local hospital and on the 12th day after the onset of her illness was transferred to this Institute for further investigation.

On admission she was alert and undistressed. Blood pressure was 140/90 mm Hg. Slight upper motor neuron facial weakness was detected on the right. She was unable to speak or indeed utter any sound though she could cough to command. The patient could not whisper, hum or mouth words either spontaneously or in imitation. Her comprehension appeared to be good in that she could follow simple written and verbal instructions. Questions were answered by nodding "yes" or "no". Writing was printed initially with some paraphasic errors but was adequate for day-to-day communication. The patient could perform a range of buccal, lingual, and facial movements on request. Such manoeuvres as licking lips and rolling the tongue were carried out with ease, as were chewing and swallowing. General neurological examination was entirely normal, in particular there was no weakness or dyspraxia of

any limb. Reflexes were symmetrical and the plantar responses flexor. Indirect laryngoscopy showed normal larynx and vocal chord movement.

CT scanning without contrast showed a very small area of reduced density in relation to the left sylvian fissure. A repeat scan with contrast revealed a large area of enhancement in the left fronto-parietal region extending to

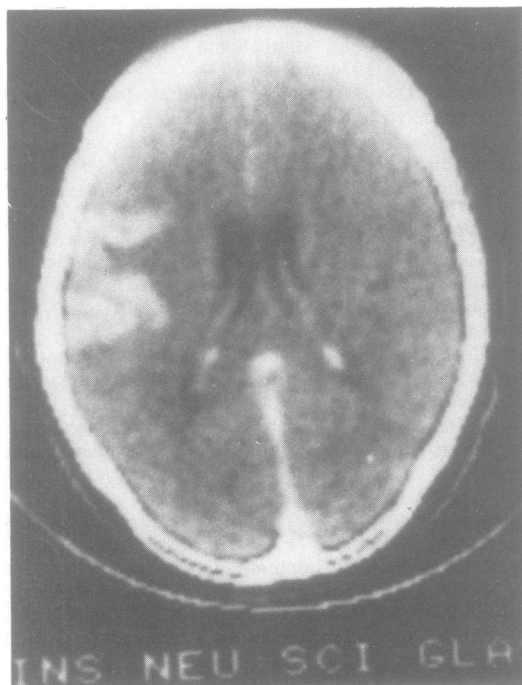


Fig CT scan with contrast enhancement showing large lesion in left fronto-parietal region.

*Present address and address for reprint requests: Dr AS David, Department of Psychiatry, The Bethlem Royal and Maudsley Hospitals, Monks Orchard Road, Beckenham, Kent BR3 3BX, UK.

Received 2 December 1983 and in revised form 1 June 1984.
Accepted 11 June 1984

Mutism following left hemisphere infarction

the brain surface (fig). An isotope brain scan showed an irregular area of increased uptake in the left inferior frontal region. Angiography was performed and though technically difficult showed absent filling of the left common and internal carotid arteries. There was no evidence of arterio-venous malformation.

The diagnosis was made of cerebral infarction secondary to common carotid artery occlusion. Assessment on the Boston Diagnostic Aphasia Examination one day after admission showed some auditory comprehension failure on complex sequential commands and abstract reasoning material. Reading comprehension and narrative writing also showed slight impairment. Verbal expression was of course absent. Follow-up assessment 12 days later showed substantial improvement to virtually normal in reading, writing, and comprehension. The patient could write long-hand with only a few paraphasic errors. Screening parietal tests showed no abnormalities. Nevertheless, she was still mute and remained so for a further 5 weeks, until speech returned abruptly. Examination at that time revealed non-fluent, laboured speech with dysprosody, articulation errors and some phoneme substitutions ("I have difficult... in finding right words"). Transient word blocking was evident, though repetition reduced errors. Verbal expression was however functional and easily understood.

Discussion

Mutism is a rare clinical entity. It may occur in patients with gross dementia, bilateral basal ganglia lesions,³ pseudo-bulbar palsy,⁴ or in the syndrome of akinetic mutism.⁵ In these instances, the underlying cause is usually self-evident. Other causes include psychotic illness,⁶ elective mutism, relatively common in children,⁷ and hysteria.⁸ The above case is remarkable in that for 7 weeks the patient remained totally mute in the absence of significant receptive dysphasia, dysgraphia, dyspraxia or hemiparesis. Recovery was sudden with only residual language impairment. The inability to speak with retained capacity to read, write and understand has been called pure motor aphasia⁹ where recovery uncovers agrammatism and paraphasia. A second pattern of recovery exists whereby speech, when it returns, though laboured is not aphasic.^{2,3} Terms such as aphemia,^{10,11} cortical dysarthria,¹² and pure word dumbness,¹³ have been used to describe this. Many modern authors regard it as an apraxia of speech.¹⁴⁻¹⁶

Recent clinico-pathological studies of lesions in Broca's area (3rd inferior frontal convolution),^{1,17} showed that many patients were *nearly* mute at the onset of their illness but made good recoveries. Most could utter some sounds or words or were mute for a few days only. They all had some degree of right sided motor weakness with one exception,¹⁸ and prominent oro-bucco-lingual dyspraxia. Our patient differed in the sustained and absolute nature of her

mutism and the absence of obvious motor or dyspraxic signs. LeCours² described a case of mutism without apraxia who recovered without dysphasia due to a lesion in the inferior Rolandic region, sparing Broca's area. Mutism is seen in lesions of the supplementary motor area,¹⁹ but dysgraphia and hemiparesis are outstanding. Subcortical lesions give rise to a variety of language and motor deficits²⁰⁻²² but not mutism.

Critchley²³ stated that even severe aphasics can say something and that "total speechlessness" usually lies outwith "organic neurology". An appealingly eclectic alternative explanation to our patient's mute state was that it was a hysterical reaction to genuine aphasia. The ability to cough despite apparent aphonia is a classic sign of hysteria though such patients usually whisper.⁸

The varieties of emotional response are as numerous as there are patients, yet common reactions are either frustration, the so-called catatrophic reaction,²⁴ or withdrawal. However, in the latter, the patient is too embarrassed or depressed to speak abnormally so withdraws, but in more total way than just keeping silent, from interpersonal communication.⁶

We postulate that this case of mutism was due to an apraxia, so localised that it only affected those movements directly subserving the execution of speech and voice production. The centre of the causative lesion probably lies in the inferior part of the pre-central gyrus,² overlapping Broca's area yet not impinging upon the motor area. We wish to draw attention to this syndrome firstly because it demonstrates the discreteness of certain language functions in the brain each of which may be put out of action by localised infarctions, and secondly because it may be mistaken for hysteria.

References

- Mohr JP, Pessin MS, Finkelstein S, Funkenstein HH, Duncan GW, Davis KR. Broca aphasia: pathologic and clinical. *Neurology (Minneapolis)* 1978; **28**:311-24.
- LeCours AR, Lhermitte F. The "pure form" of the phonetic disintegration syndrome (pure anarthria); anatomo-clinical report of a historical case. *Brain Lang* 1976; **3**:88-113.
- Geschwind N. Non-aphasic disorders of speech. In: *Selected Papers on Language and the Brain*. Boston: D Reidel Publishing Co, 1974:74-85.
- Cummings JL, Benson DF, Houlihan JP, Crosenfeld LF. Mutism: Loss of neocortical and limbic vocalization. *J Nerv Ment Dis* 1983; **171**:255-9.
- Plum F, Posner JB. *The Diagnosis of Stupor and Coma*. Philadelphia: Davis, 1980.
- Benson DF. Psychiatric aspects of aphasia. *Br J Psychiatry* 1973; **123**:555-66.

- ⁷ Reed GF. Elective mutism in children: a reappraisal. *J Child Psychol Psychiatry* 1963;**4**:99–107.
- ⁸ Charcot J-M. A case of hysterical mutism in a man. In: *Clinical Lectures on Diseases of the Nervous System*. London: The New Sydenham Society, 1889:360–73.
- ⁹ Brown JW. *Aphasia, Apraxia and Agnosia*. Illinois: Charles C Thomas, 1972:117–26.
- ¹⁰ Bastian HC. On different kinds of aphasia, with special reference to their classification and ultimate pathology. *Br Med J* 1887;**2**:985–90.
- ¹¹ Schiff HB, Alexander MP, Naeser MA, Galaburda AM. Aphemia. Clinical-anatomic correlations. *Arch Neurol* 1983;**40**:720–7.
- ¹² Bay E. Aphasia and non-verbal disorders of language. *Brain* 1962;**85**:412–26.
- ¹³ Brain WR. *Speech Disorders*. London: Butterworth and Co, 1961.
- ¹⁴ Nathan PW. Facial apraxia and apraxic dysarthria. *Brain* 1947;**70**:449–78.
- ¹⁵ Luria AR. *Higher Cortical Functions in Man*. New York: Basic Books, 1966.
- ¹⁶ Critchley M. Articulatory defects in aphasia: the problem of Broca's aphemia. In: *Aphasiology*, London: Edward Arnold, 1970:210–6.
- ¹⁷ Ruff RL, Arbit E. Aphemia resulting from a left frontal haematoma. *Neurology (NY)* 1981;**31**:353–6.
- ¹⁸ Masdeu JC, O'Hara RJ. Motor aphasia unaccompanied by faciobrachial weakness. *Neurology (NY)* 1983;**33**:519–21.
- ¹⁹ Masdeu JC, Schoene WC, Funkenstein H. Aphasia following infarction of the supplementary motor area. *Neurology (Minneapolis)* 1978;**28**:1220–3.
- ²⁰ Damasio AR, Damasio H, Rizzo M, Varney N, Gersh F. Aphasia with nonhemorrhagic lesions in the basal ganglia and internal capsule. *Arch Neurol* 1982;**39**:15:20.
- ²¹ Damasio H. Cerebral localisation of the aphasias. In: Sarno MT, ed. *Acquired Aphasia*. New York: Academic Press, 1981:27–50.
- ²² Naeser MA, Alexander MP, Helm-Estabrooks N, Levine HL, Laughlin SA, Geschwind N. Aphasia with predominantly subcortical lesion sites. *Arch Neurol* 1982;**39**:2–14.
- ²³ Critchley M. Total speechlessness. In: *Aphasiology*. London: Edward Arnold, 1970:383–9.
- ²⁴ Goldstein K. *Language and Language Disturbances*. New York: Grune and Stratton, 1948.