

Basilar aneurysm

An unusual cause of pain in a blind eye

SUSAN LIGHTMAN, ANTHONY TYERS and PETER LEAVER*

*Department of Clinical Ophthalmology, Moorfields Eye Hospital, City Road,
London EC1V 2PD, UK*

Key words: brain aneurysm; painful blind eye

INTRODUCTION

Pain in a blind eye is usually associated with either raised intraocular pressure or impending phthisis. Aneurysms of the internal carotid artery and circle of Willis are a well known cause of pain and neurological signs in and around the eye (Ross-Russell, 1980), unlike vertebro-basilar aneurysms which are uncommon (Locksley, 1966; Drake, 1965; Nijensohn *et al.*, 1974). The latter do not have such classic modes of presentation, often presenting with non-specific symptoms before the aneurysm ruptures (Drake, 1965; Cogan & Mount, 1963). Hence, they are difficult to diagnose and with an enucleated eye localizing neurological signs may be absent and the diagnosis only made when neurological signs develop elsewhere.

CASE REPORT

A 63-year-old male whose left eye was blind from a screwdriver injury 40 years previously, presented with a six-month history of pain around the left eye. The pain radiated from the eye to the brow, temple

and vertex and was aching in type. It occurred several times a week, had no precipitating factors and was partially relieved by aspirin. He had also noticed occasional slight drooping of the left eyelid. The patient was a known hypertensive, on treatment with Methyl Dopa.

On examination, the left eye was divergent with no perception of light. There were signs of an old penetrating ocular injury. The intraocular pressure was raised at 75 mmHg and there was no view of intraocular structures posteriorly. An ultrasonic B scan showed a total fixed retinal detachment with cyst formation.

He was treated initially with oral Diamox 250 mg qds and then with a retrobulbar injection of 2 ml of 70% alcohol but without effect. Left enucleation was performed four months after presentation. A partial left ptosis was noted at the pre-operative examination and attributed to the retrobulbar alcohol. Histology of the enucleated globe revealed no other disease process.

After an apparent improvement lasting about two weeks, recurrent bouts of pain returned and persisted. There were no other symptoms and the ptosis remained unchanged. Ten months later, the pain increased and a complete left ptosis developed over a period of four weeks. He now also complained of a feeling of numbness

* Reprint requests to: Dr. Susan Lightman, Moorfields Eye Hospital, City Road, London EC1V 2PD, UK

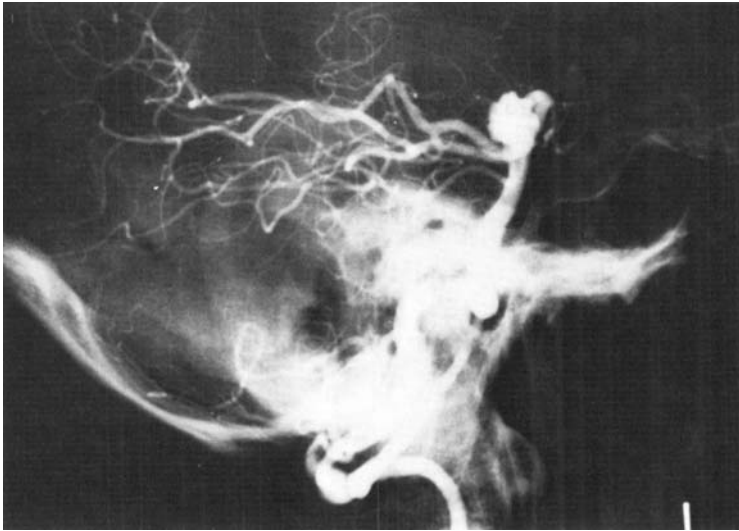


Fig. 1. Vertebral angiogram showing large saccular aneurysm arising from trunk of basilar artery.

around the left eye and cheek and mild weakness of the right arm and leg. He had signs of pyramidal weakness of the limbs and facial weakness on the right side, but there were no sensory signs. His BP was 190/110.

CT scans showed a large density mass enhancing strongly after Conray. Carotid angiography was normal but vertebral angiography showed a large saccular aneurysm arising from the trunk of the basilar artery at the origin of the left superior cerebellar artery, projecting superiorly and to the left behind and medial to the posterior cerebral artery (Fig. 1).

Surgery was considered but refused at that time by the patient. His blood pressure was controlled and the pain and hemiparesis improved. Two months later he developed a dense right hemiplegia. He was readmitted and after further discussion surgery was undertaken.

At surgery the aneurysm was found to be indenting the brain stem medial to the tentorium just inferior to the oculomotor nerve,

which was atrophic, either as a result of injury from the screwdriver 40 years previously or from compression by the aneurysm. The aneurysm was 30 mm in diameter with a 7-8 mm neck arising from the basilar artery proximal to the bifurcation at the origin of the left superior cerebellar artery. A Surgita aneurysm clip was placed across the neck, the aneurysm was aspirated and fleshy clot removed via an incision into the fundus.

The patient had a stormy post-operative course but was eventually discharged with a residual hemiparesis and facial weakness which has continued to improve.

COMMENT

Initially this patient seemed to have a straightforward problem of a painful blind eye with a markedly raised intraocular pressure. He had minimal intermittent ptosis at that time without other signs suggestive of IIIrd nerve involvement, which

was considered to be the result of a retrobulbar alcohol injection. He had experienced facial numbness but had no objective sensory loss. The eye was enucleated as other measures had failed to control the pain. Further clues suggesting another disease process were not found until ten months later when he developed a complete

(L) ptosis and (L) pyramidal and facial weakness soon after.

ACKNOWLEDGEMENT

The authors would like to thank Professor W.I. McDonald and Mr. David Thomas for their help in preparing this paper. S.L. is supported by a grant from the Wellcome Trust.

REFERENCES

- COGAN, D. E. & MOUNT, H. T. J.: Intracranial aneurysms causing ophthalmoplegia. *Arch. Ophthalmol.* 70:757-771, 1963
- DRAKE, C. G.: Surgical treatment of ruptured aneurysms of the basilar artery. *J. Neurosurg.* 23: 457-473, 1965
- LOCKSLEY, H. B.: Natural history of subarachnoid haemorrhage. Intracranial aneurysms and arteriovenous malformations. *J. Neurosurg.* 25:321-368, 1966
- NIJENSOHN, D. E., RUBEN, J. S. & REAGAN, T. J.: Clinical significance of basilar artery aneurysms. *Neurology* 301-305, 1974
- ROSS-RUSSELL, R. W.: Vascular causes of ocular pain. *Trans. ophthalm. Soc. UK* 100: 251-252, 1980