

A CASE OF CHOREA DUE TO POLYCYTHAEMIA VERA

H. H. E. Morré*, T. C. A. M. van Woerkom and L. J. Endtz

SUMMARY

The history of a 76 years-old woman suffering from chorea caused by polycythaemia vera is reported. Initial treatment with repeated phlebotomy followed by intravenous administration of P 32 led to the disappearance of both the polycythaemia and the chorea. Since abnormal CBF in the region of the basal ganglia has been postulated to be responsible for this syndrome, a dynamic CT examination was performed, but no significant abnormalities were found.

INTRODUCTION

Neurological abnormalities are common complications of polycythaemia vera (SLOAN, 1933; KRAMER, 1961; SILVERSTEIN *et al.*, 1962). Chorea associated with polycythaemia is, however, rare, and to the best of our knowledge only 27 patients with this syndrome have been reported so far (EDWARDS *et al.*, 1975; VOICULESCU *et al.*, 1979). Recognition of the clinical entity is important, because with adequate treatment it is reversible (TROTSENBURG and KOSTER, 1954; EDWARDS *et al.*, 1975; VOICULESCU *et al.*, 1979). Despite post-mortem studies (SCHIFF *et al.*, 1936; KOTNER and TRITT, 1942; BIETTI *et al.*, 1968), laboratory investigations, and investigation of the cerebral blood flow (CBF) (VOICULESCU *et al.*, 1979), the pathophysiology of chorea due to polycythaemia is still far from clear.

In this report we present clinical and computed tomographic (CT) data on a patient with polycythaemic chorea.

CASE HISTORY

On the 23th of April, 1980, a 76 years-old woman was admitted to our hospital because of involuntary movements of unknown origin. Her complaint was a tingling feeling in both hands. She experienced the involuntary movements as uncomfortable; they were at first ascribed to nervousness. She said they had been present for about one month. In addition she complained of a slight dizziness, which she had

* Dept. of Neurology, Municipal Hospitals, The Hague, The Netherlands
Clin. Neurol. Neurosurg. 1982, Vol. 84-2 (Accepted 15.1.82)

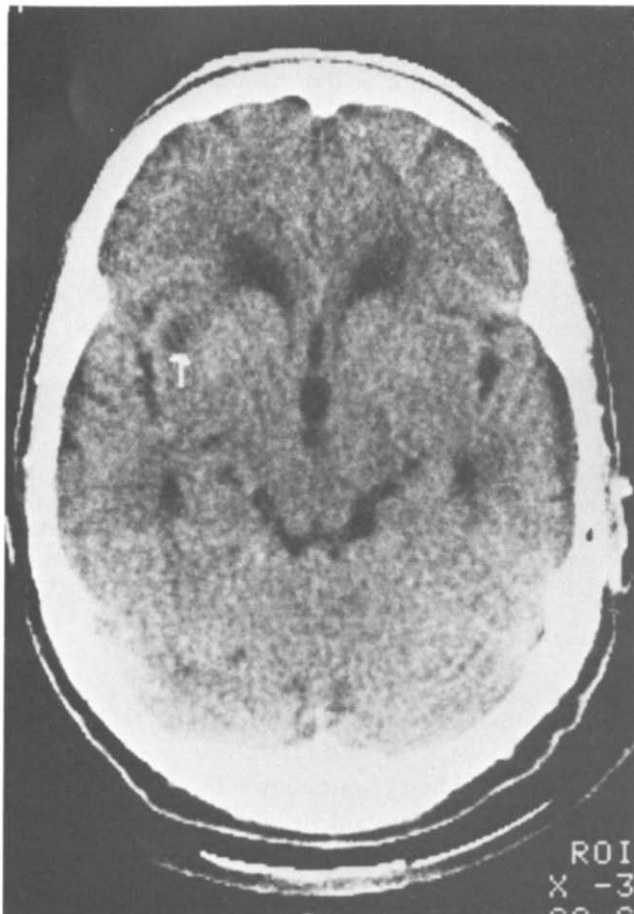


Fig. 1.
The small right sided infarct near the claustrum is indicated by the arrow.

had for many years. Relatives had noticed patient's involuntary movements and also the fact that she made funny faces three months earlier. Besides, her speech had become more difficult to understand. Both the patient and her relatives stressed the fact that such a disease had never occurred in their family before. On examining the patient, we saw the involuntary movements of her face, especially of the mouth and tongue; the latter she protruded while she talked. Her speech was dysarthric and she raised her voice on certain syllables. The rapid movements she made with her arms and hands were interpreted as choreatic. There was a slight paresis of her left arm.

She had a red face, brick-red hands, and slightly cyanotic nails and lips. There was no hepatomegaly or splenomegaly. X-ray films of skull and chest were normal. A CT scan revealed a small infarct in the basal ganglia near the claustrum on the right side (Fig. 1). The EEG was bradyrhythmic and diffusely abnormal without focal cortical abnormalities.

LABORATORY FINDINGS

Haemoglobin 12.2 mmol/l (N: 7.3-9.5 mmol/l), haematocrit 64.5% (N: 36-46%), erythrocyte count $8.44 \times 10^{12}/l$ (N: $3.7 - 4.9 \times 10^{12}/l$), thrombocyte count $488 \times 10^9/l$ (N: $150 - 350 \times 10^9/l$). Leucocyte count $10.9 \times 10^9/l$ (N: $3.9 - 11.0 \times 10^9/l$), polynuclears 76%, eosinophils 9%, lymphocytes 7%, monocytes 8%. The leucocyte alkaline phosphatase level was elevated. A bone marrow specimen obtained by sternal puncture showed very active haematopoiesis, with an increased number of megacariocytes of which many were abnormally large.

These haematological findings confirmed the clinical diagnosis of polycythaemia vera.

Between April 25th and May 12th, 1980, seven phlebotomies were performed. The haemoglobin and the haematocrit values both normalized to 7.8 mmol/l and 42.8%, respectively (Fig. 2). At first the patient benefited from the venesections in that the involuntary movements decreased after each treatment; however, the choreatic movements increased whenever the haemoglobin level rose. 7 mc P 32 was given intravenously on May 25th, 1980. After this treatment the choreatic movements gradually subsided again. When the patient was discharged on June 18th there was still a slight dysarthria, which disappeared in the course of the following month. During her stay in the hospital an attempt was made to measure the cerebral blood flow in the basal ganglia by dynamic computed tomography to see whether an abnormality of perfusion or circulation could be found. The enhancement changes in the basal ganglia were consistent with the changes in the surrounding tissue; an increased or decreased blood flow in the basal ganglia could not be demonstrated with this method.

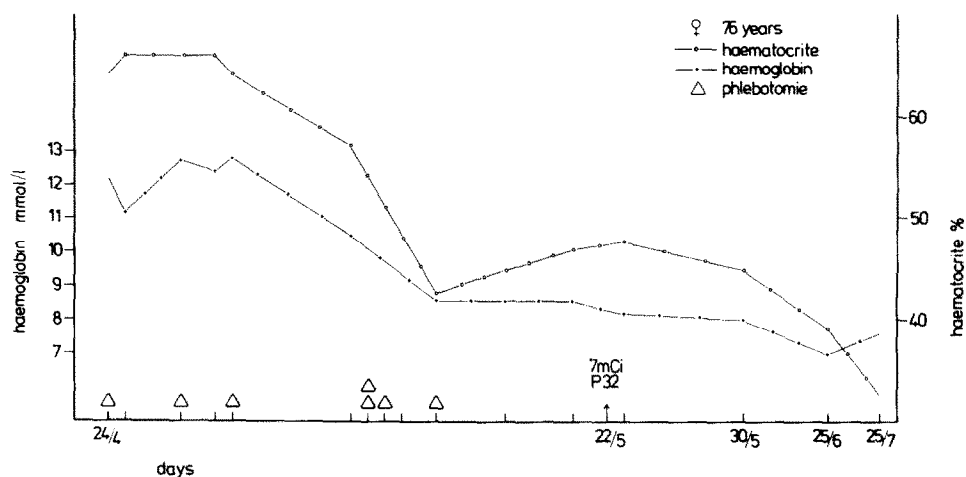


Fig. 2.

The changes of haemoglobin and haematocrit during treatment with phlebotomies and 7.0 mc P 32 intravenously.

DISCUSSION

Depending on their nature, choreatic movements have been related to lesions occurring in different parts of what is called the extrapyramidal system (MARTIN, 1968). Which structures precisely are involved in the choreatic manifestations due to polycythaemia is not known (GAUTIER-SMITH and PRANKERD, 1967; EDWARDS *et al.*, 1975; VOICULESCU *et al.*, 1979). The generally good results of appropriate treatment of polycythaemia suggest that in the majority of the patients, reversible functional disturbances rather than irreversible anatomical lesions are responsible for motoric disorders of this origin. The nature of these functional disturbances has been partially explained by the low cerebral blood flow (CBF) found in patients with polycythaemia whose haematocrite is far above average (THOMAS *et al.*, 1977). In this respect it is of interest that lowering of the haematocrit by venesection is associated with a remarkable increase in CBF (THOMAS *et al.*, 1977). As far as we know, cerebral circulation has been studied in only one patient with polycythaemia complicated by choreatic movements (VOICULESCU *et al.*, 1979). By means of the Xenon-133 and the Technetium-99m methods Voiculescu and co-workers showed in their patient a diffuse reduction of the CBF with the lowest flow rate occurring bilaterally in the region of the basal ganglia. No other observations of this kind have been found in the literature.

In our case computerized tomography disclosed a small low-density area, certainly representing an infarct, in the region of the right claustrum, a structure belonging to the corpus striatum and lying close to the putamen (METTLER, 1968).

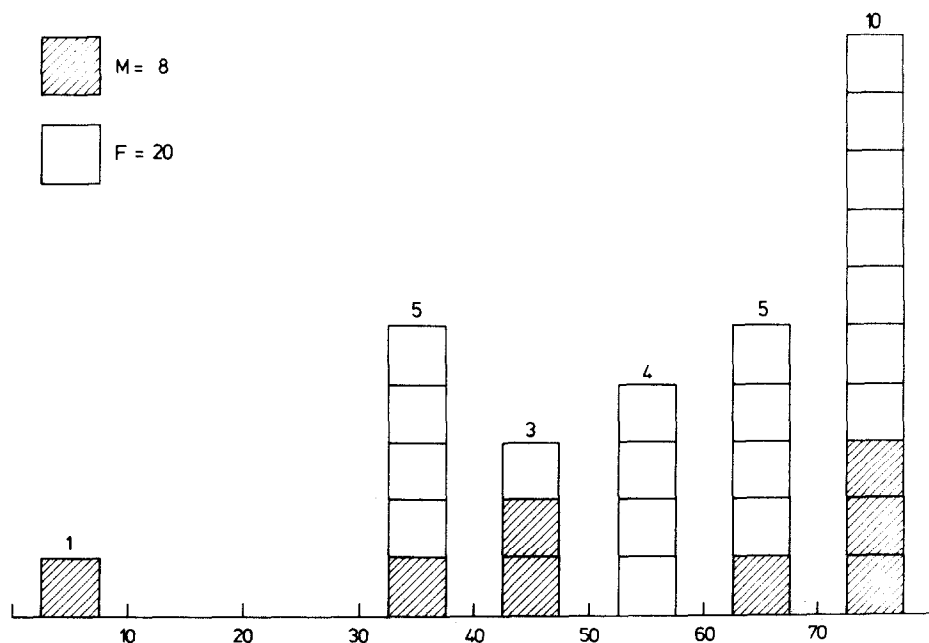


Fig. 3.
The distribution of age and sex in patients with polycythaemic chorea of all the reported cases so far.

However, in view of the common syndromes caused by lacunar infarcts, it does not seem very likely that the patient's bilateral choreatic movements could be ascribed to this localized lesion on the CT scan (MOHR *et al.*, 1978). Determination of cerebral blood flow by means of dynamic computed tomography revealed no significant differences in the CBF between the area of the basal ganglia and the surrounding brain tissue. Nevertheless, widespread invisible pathophysiological alterations in the basal ganglia due to polycythaemia and resulting in choreatic movements cannot be excluded.

Finally, although a reduced CBF in the nigro-striatal system may play an important part in the pathogenesis of chorea, it seems probable that at least one other factor is involved. The incidence of polycythaemia vera is somewhat higher in men (CALABRESI and MEYER, 1959). Yet polycythaemic chorea is mostly noted in middle-aged or elderly females: 20 out of 28 reported cases including our patient (71%; Fig. 3). Almost the same female predominance has been observed for Sydenham's chorea in the age-group older than 10 years (NAUSIDA *et al.*, 1980). It can be postulated that polycythaemic chorea is a reflection of a functional disorder of the basal ganglia due to an interaction between a disturbed CBF and a genetic influence on that part of the cerebral control of movement.

ACKNOWLEDGEMENT

We are indebted to Dr. R. E. M. Hekster for his neuroradiological investigations and to Dr. C. H. W. Leeksa for the haematologic consultation.

REFERENCES

- BIETTI, C., A. POMPILI and L. SINIBALDI (1968) Coreoatetosi in malattia di Vaquez. (Contributo anatomo-clinico), *Rivista di Neurologia* 38: 615.
- CALABRESI, P. and O. O. MEYER (1959) Polycythemia vera. I: Clinical and laboratory manifestations, *Ann. Int. Med.* 50: 1182.
- EDWARDS, P. D., R. PROSSER and C. E. C. WELLS (1975) Chorea, polycythaemia, and cyanotic heart disease, *J. Neurol. Neurosurg. Psych.* 39: 729.
- GAUTHIER-SMITH, P. C. and T. A. PRANKERD (1967) Polycythaemia vera and chorea, *Acta Neurol. Scand.* 43: 357.
- KOTNER, L. M. and J. H. TRITT (1942) Chorea complicating polycythaemia vera: report of a case. *Ann. Int. Med.* 17: 544.
- KRAMER, W. (1961) Neurologische stoornissen bij polycythaemia vera, *Ned. T. Gen.* 105: 1277.
- MARTIN, J. P. (1968) Choreatic syndromes. In: *Handbook of Clinical Neurology: Diseases of the basal ganglia*. Ed: Vinken, P. J. and G. W. Bruyn, Amsterdam, North Holland Publishing Co. 6: 435.
- METTLER, F. A. (1968) Anatomy of the basal ganglia. In: *Handbook of Clinical Neurology: Diseases of the basal ganglia*. Ed: Vinken, P. J. and G. W. Bruyn, Amsterdam, North Holland Publishing Co. 6: 1.
- MOHR, J. P., L. R. CAPLAN, J. W. MELSKI, R. J. GOLDSTEIN, G. W. DUNCAN, J. P. KISTLER, M. S. PESSIN and H. L. BLEICH (1978) Harvard Coöperative Stroke Registry: A prospective registry, *Neurology* 28: 754.
- NAUSIDA, P. A., B. J. GROSMANN, W. C. KOLLER, W. J. WEINER and H. L. KLAUANS (1980) Sydenham chorea: An update, *Neurology* 30: 331.
- SCHIFF, P., J. O. TRELLES and J. AJURIAGUERRA (1936) Sur un syndrome particulier d'origine pallidale. Erythémie avec chorée, *Encéphale* 31: 153.

- SILVERSTEIN, A., H. GILBERT and L. R. WASSERMAN (1962) Neurologic complications of polycythaemia. *Ann. Int. Med.* 57: 909.
- SLOAN, L. H. (1933) Polycythaemia rubra vera. Neurologic complications; report of four cases. *Arch. Neurol. Psychiat.* 30: 154.
- THOMAS, D. J., G. H. DU BOULAY, J. MARSHALL, T. C. PEARSON, R. W. ROSS RUSSEL, L. SYMON, G. WETHERLEY-MEIN and E. ZILKHA (1977) Cerebral blood-flow in polycythaemia. *Lancet* ii: 161.
- TROTSENBURG, L. VAN and M. KOSTER (1954) Chorea caused by polychythaemia vera and treated with radioactive phosphorus. *Folia Psychiat. Neurol. Neurochir. Neerland.* 57: 429.
- VOICULESCU, V., D. A. JONESCU, G. LAZAR, C. ALECU, C. PREDESCU, C. POPA, A. XENAKIS, J. MARCU and M. GHITESCU (1979) Two cases of choreatic syndrome caused by polycythemia vera. *Eur. Neurol.* 18: 96.