

Progressive Multifocal Leukoencephalopathy: A Burnt-Out Case

Richard W. Price, MD,* Surl Nielsen, MD,† Bruce Horten, MD,† Michael Rubino, PhD,‡
Billie Padgett, PhD,‡ and Duard Walker, MD‡

A patient with Hodgkin's disease developed progressive multifocal leukoencephalopathy (PML), documented by brain biopsy to be associated with JC virus infection. His disease progressed over several months, resulting in severe neurological deficit, but then stabilized with little or no further clinical progression during the remaining year of his life. Histopathological evaluation of the brain at autopsy supported the clinical impression that brain infection was arrested. Whereas the brain biopsy exhibited the histological features of active PML including giant bizarre astrocytes, at postmortem examination brain lesions appeared inactive, with regression of astrocytic changes and elimination of oligodendroglial inclusions. Similarly, JC virus antigen, present in the brain biopsy, was not detected in the autopsied brain. This case provides further evidence that PML is not invariably fatal and that clinical and cytological remission can occur.

Price RW, Nielsen S, Horten B, Rubino M, Padgett B, Walker D: Progressive multifocal leukoencephalopathy: a burnt-out case. *Ann Neurol* 13:485-490, 1983

Progressive multifocal leukoencephalopathy (PML) is an opportunistic viral infection of the central nervous system that characteristically pursues a steadily progressive course and is fatal within a few weeks to several months after onset of symptoms [1, 9, 11, 14]. Since the disease was initially characterized, however, a few cases of transient and, more rarely, well-documented long-term remission have been reported [2, 3, 4, 9, 12]. We describe an additional patient with PML, in whom an arrest in the progression of disease was noted. Histopathological evaluation of the patient's brain at autopsy revealed only inactive demyelination. Oligodendroglial intranuclear inclusions were absent, and there was marked regression of the characteristic PML astrocytic changes documented at brain biopsy during the active phase of the infection.

Case History

A 43-year-old white man with Hodgkin's disease was admitted on October 31, 1978, for evaluation of aphasia. A diagnosis of Hodgkin's disease, mixed cellular type, had been established approximately one year earlier when the patient presented with axillary and inguinal adenopathy. He was initially treated with nodal radiation and MOPP (nitrogen mustard, vincristine, procarbazine, and prednisone) followed by lomustine (CCNU) and vinblastine, and subsequently, because of recurrent disease both above and below the diaphragm, COPP (cyclophosphamide, vincristine, procar-

bazine, and prednisone) therapy was instituted. In August, 1979, the patient presented to another hospital with a 6-day history of fever, chills, and headache. Cerebrospinal fluid (CSF) examination revealed 5 white blood cells per mm³ (100% polymorphonuclear leukocytes), a glucose of 41 mg/dl, and protein of 46 mg/dl. The cryptococcal antigen titer in the blood was 1:64 but was considered equivocal in the CSF. Whereas previous skin tests had been positive for mumps and streptokinase/streptodornase antigens, these had become negative. In early October, a repeat spinal tap revealed a CSF cryptococcal antigen titer of 1:32; 250 cells per mm³, of which 80% were lymphocytes; and a glucose of 16 mg/dl and protein of 149 mg/dl. The patient was treated with systemic amphotericin B and 5-fluorocytosine, with resultant improvement of his fever and headache. Aphasia had its onset in mild form with word-finding difficulty in July but had progressed notably in the weeks before the patient's admission to Memorial Hospital.

At the time of admission, the patient's headaches and fever had disappeared. On examination, moderately severe expressive aphasia and mild right hemiparesis were present. Both plantar responses were extensor. A spinal tap yielded 10 white blood cells per mm³, 99% of which were mononuclear, a glucose of 30 mg/dl, and a protein of 23 mg/dl. Cryptococcal antigen at this time was negative. A computerized tomographic (CT) scan obtained shortly before admission revealed a circumscribed low-density area in the left posterior frontal region (Fig 1a, b). An electroencephalogram (EEG) was abnormal, with focal delta slowing in the left hemisphere superimposed on mild bilateral background slowing. Im-

From the Departments of *Neurology and †Pathology, Memorial Sloan-Kettering Cancer Center and Cornell University Medical College, New York, NY 10021, and the ‡Department of Medical Microbiology, University of Wisconsin Medical College, Madison, WI 53706.

Received Aug 9, 1982. Accepted for publication Sept 12, 1982.

Address reprint requests to Dr Price, Department of Neurology, Memorial Sloan-Kettering Cancer Center, 1275 York Ave, New York, NY 10021.

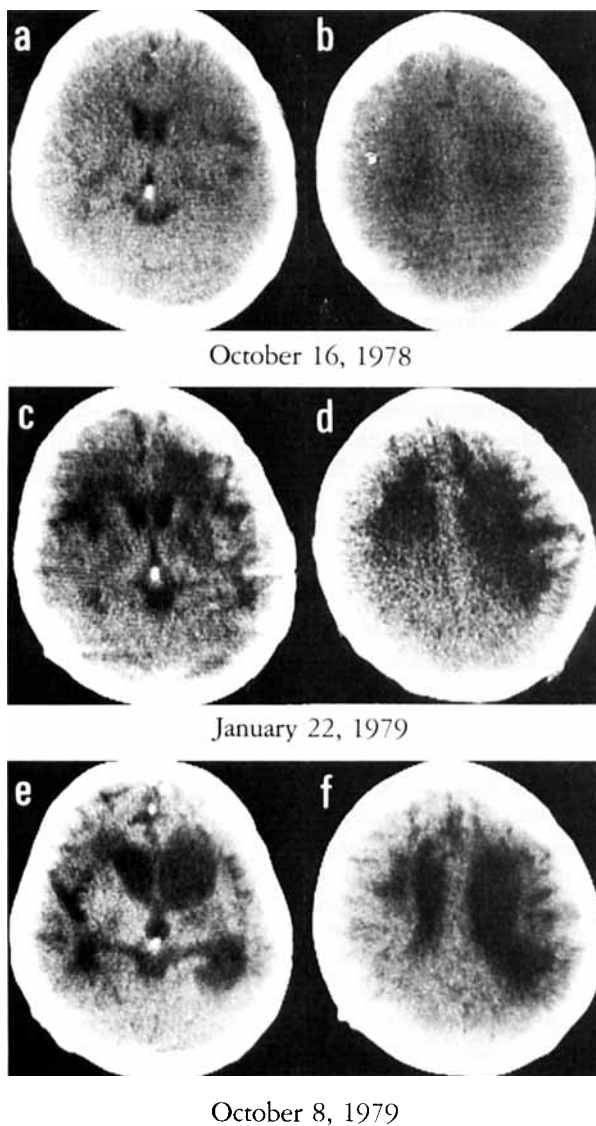


Fig 1. Evolution of CT scan findings. Scans were obtained on the dates specified. Montage presents the left hemisphere on the right side of the figure. The first scan shows only a small peripheral area of decreased density in the posterolateral frontal region (a, b). Three months later, in January, the demyelinated hypodense areas are now extensive (c, d). Subsequently, atrophy with sulcal and ventricular enlargement developed in the areas of previous demyelination (e, f).

munological testing revealed impaired lymphocyte proliferative responses to mitogens and defective leukocyte migration inhibitory factor (LIF) production in response to JC virus antigen; these results were included in a previously published series [16]. Both lymphocyte proliferation and LIF production in response to cryptococcal antigen were vigorous, suggesting that strong specific immunological response had accompanied recovery from meningeal fungal infection.

A brain biopsy was carried out and a diagnosis of PML associated with JC virus infection was made (to be discussed). Amphotericin and 5-fluorocytosine were discontinued.

Levamisole, 150 mg three times per week, was begun but stopped after four doses. During hospitalization the patient's neurological condition deteriorated steadily, with diminished language output and comprehension as well as worsening of his right hemiparesis. He was discharged 2 weeks after admission.

We did not see him thereafter but maintained telephone contact with his wife, who said that he continued to deteriorate so that by January, 1979, he had become mute and unable to follow verbal commands. He lost bowel and bladder control. However, he remained alert in appearance and cooperated while being fed. A CT scan at that time documented the progression of white matter disease (Fig 1c, d).

Between January and March of 1979 the patient's neurological condition stabilized. There was never any clear recovery, but his ability to be fed and to respond to his wife's nursing care remained essentially unchanged over the next year. A CT scan in October, 1979, showed that the areas of previous demyelination had progressed to atrophy with ventricular enlargement, but progression into the white matter of previously uninvolved regions was not evident (Fig 1e, f). In March, 1980, the patient became abruptly ill, presumably from aspiration pneumonia, and died. Postmortem examination of the brain was performed at Memorial Hospital.

Pathological Findings

In the brain biopsy, changes were confined to the white matter, where lipid-laden macrophages predominated in a very cellular field and only a few residual normal oligodendrocytes were identified. Reactive astrocytes were also present. Giant astrocytes with bizarre nuclei measuring up to 40 μ in diameter contained coarsely clumped chromatin and thickened nuclear membranes (Fig 2). A few of these huge nuclei had a basophilic, homogeneous appearance. A rare smaller round nucleus, apparently oligodendroglial, exhibited a similar homogeneous basophilia. A few lymphocytes were seen forming a cuff around one blood vessel. Immunofluorescent staining of frozen tissue with specific antisera against JC virus, BK virus, and simian virus 40 (SV 40) revealed only cells containing JC virus antigen, thereby establishing the virological diagnosis [10].

At postmortem examination of the brain, the left cerebral white matter from the frontal pole to the parietooccipital junction exhibited cavitation (Fig 3). Scattered areas of softening were also present in the right hemisphere, particularly in the white matter of the frontal pole. The white matter of the right temporal and parietal lobes and of both occipital lobes was relatively spared. Secondary atrophy of the left basis pontis and the right lateral column of the spinal cord was evident.

Microscopically, the left hemisphere cavitation was characterized by the presence of only a few macrophages and by well-developed fibrillary gliosis along the border associated with occasional astrocytic nuclei. A rare cell had a slightly enlarged nucleus (Fig 4A), but none approached the size and atypical appearance of

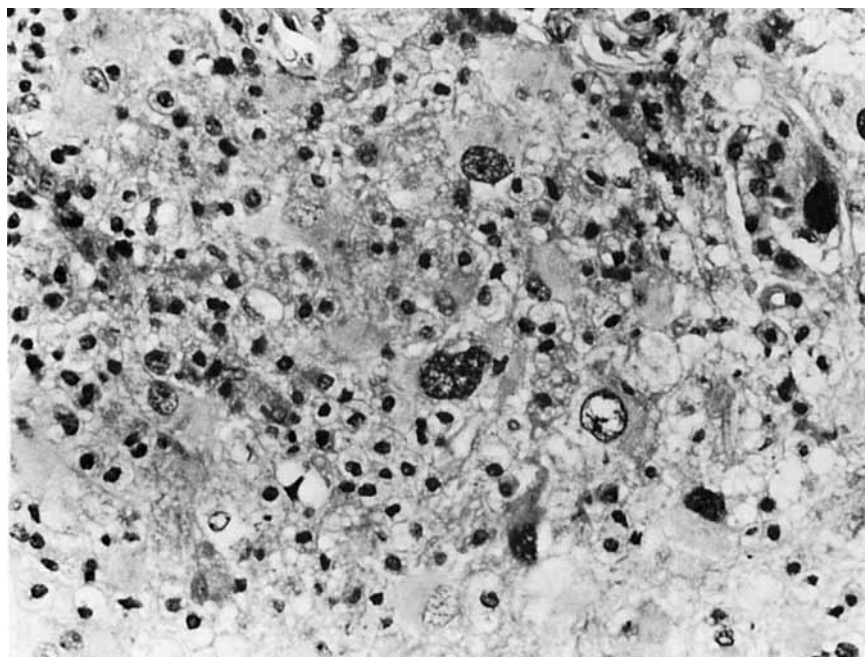


Fig 2. Histopathology of brain biopsy. A representative field from the biopsy shows marked astrocytic atypia, with several bizarre enlarged astrocytic nuclei. The background contains numerous macrophages. (H&E; $\times 250$.)

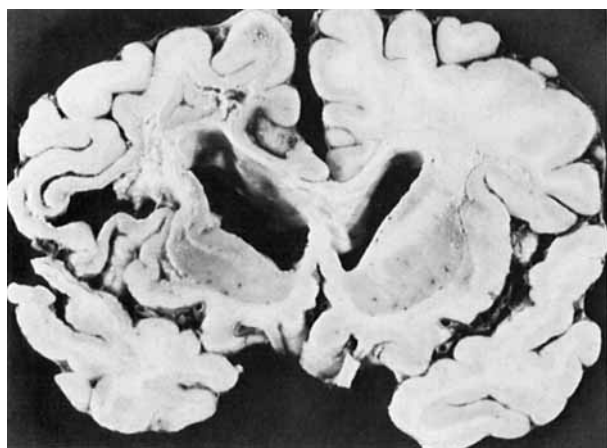

Fig 3. Gross appearance of the brain at autopsy. The white matter of the left frontal lobe (shown on the left) exhibits extensive cavitory necrosis, while less marked involvement is present on the right.

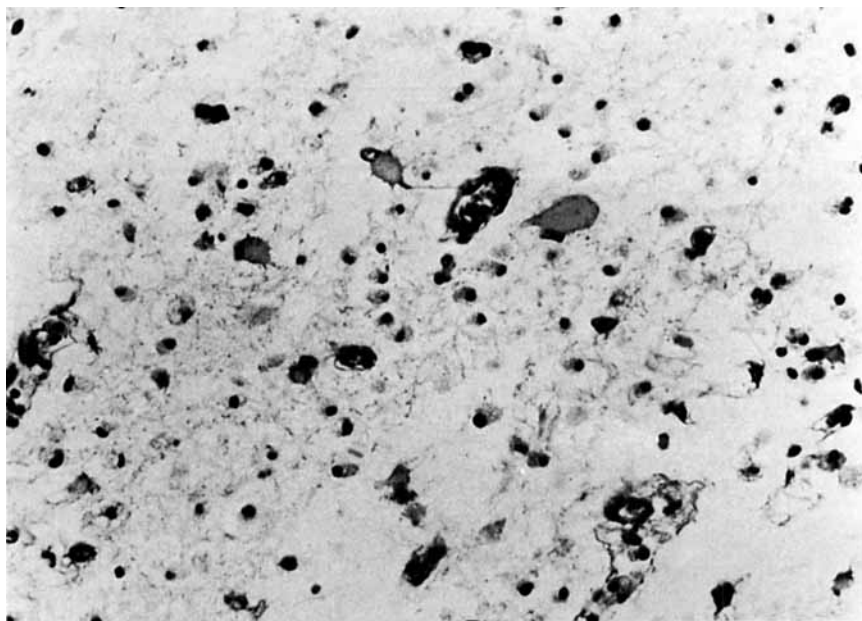
the astrocytes present in the biopsy. A few lymphocytes were seen in perivascular locations. The multifocal nature of the process was evident with the presence of small demyelinating lesions in adjacent and remote white matter (Fig 4B). The Bodian silver impregnation technique and the Luxol fast blue myelin stain confirmed the relative axonal sparing in these

smaller foci of myelin loss. Occasional reactive astrocytes and a rare macrophage were associated with the decrease in oligodendrocytes in these foci (Fig 4C). Nowhere were intranuclear inclusions identified in oligodendroglia or other cellular elements. A few lesions also had focal stippled tissue calcification. Scattered microglial clusters and an occasional chromatolytic neuron in the lower cortex were the only changes of note in the gray matter structures.

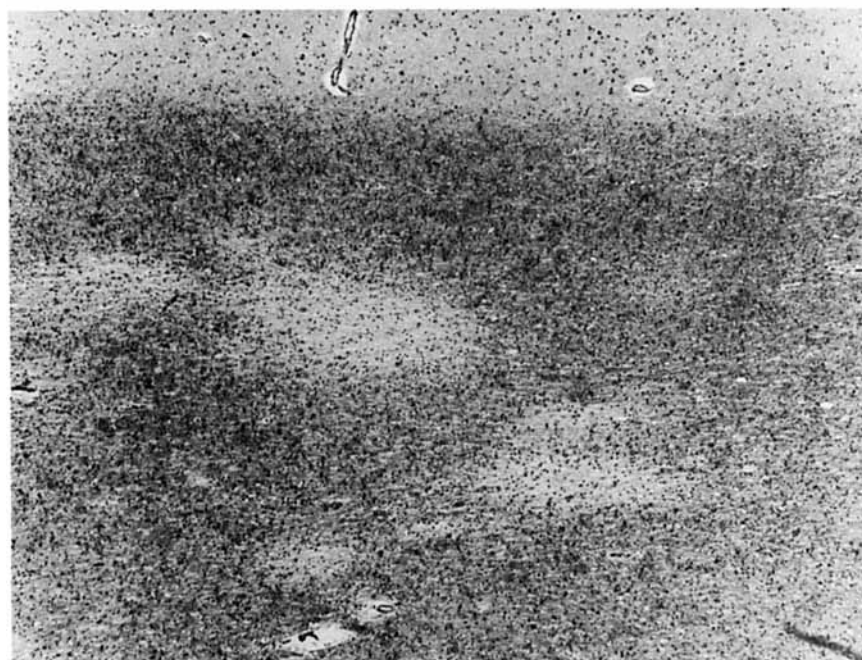By means of the peroxidase-antiperoxidase method, with rabbit antiserum reactive against polyoma group-common antigen as the primary serum, brain sections were evaluated for the presence of viral antigen [5]. Antigen was not detected within or surrounding the demyelinated foci, while simultaneously tested positive control sections from an active case of PML (similarly fixed with formalin) were clearly antigen positive.

Discussion

PML results from papovavirus infection of the brain. In the great majority of cases rigorously studied, JC virus has been identified as the etiological agent [9, 10], while in 2 cases the related SV40 virus has been reported [15]. In the patient discussed here, JC virus was identified by specific antiserum staining of biopsied brain tissue. JC virus is of low pathogenicity and requires impairment of cell-mediated host defenses to allow a progressive nervous system infection [16]. In our patient, Hodgkin's disease and antineoplastic therapy provided the setting for such opportunistic infection. The initial phase of his illness was typical, with relentless clinical progression which was also documented by CT scan. However, after several months,



A

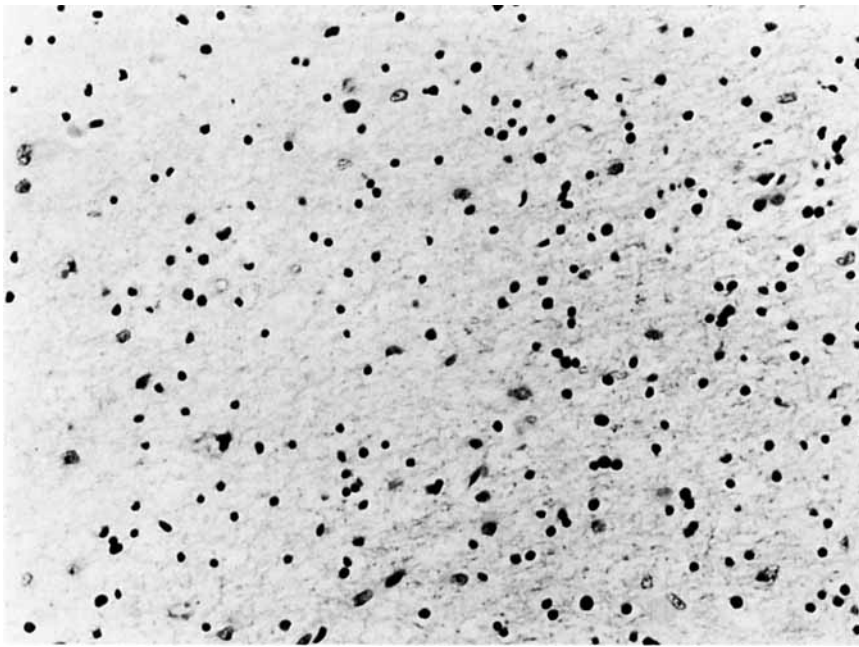


B

Fig 4. Histopathology of the brain at postmortem examination. (A) A field within one of the large lesions contrasts with the biopsy, seen in Figure 2, in showing a reduced number of macrophages and the absence of nuclear atypia within the reactive astrocytic population. The astrocytes illustrated here are among the largest found in the postmortem brain. (H&E; $\times 250$.) (B) Low-power micrograph illustrating smaller foci of demyelination within the subcortical white matter. The cerebral cortex is shown at the top. (H&E; $\times 40$.) (C) Higher-power view of the transition zone of one of the demyelinating foci shown in B. Demyelination is to the left, with normal brain to the right. Notable is the reduction in the number of oligodendrocytes within the demyelinated focus, with a few reactive astrocytes (upper left) and normal-appearing oligodendrocytes intermingled with reactive astrocytes (lower right). Absent are intranuclear inclusions within oligodendrocytes. (H&E; $\times 100$.)

this progression apparently ceased. Although the extent of the patient's neurological impairment could well have obscured further demyelination, for over one year no new functional impairment occurred, indicating an altered tempo in the course of his disease.

The clinical impression that the infection had arrested was borne out by the pathological findings, particularly when the histopathological features of the biopsy and autopsy material were compared. Thus, residual white matter cavitation and demyelination in various stages were evident at death, but the characteristic microscopic cellular changes of active PML were



C

no longer seen. Whereas the large transformed astrocytes characteristic of PML were readily identified in the biopsy, they were no longer present in the brain at death, with the possible exception of a rare, large astrocyte within cystic areas. Moreover, at autopsy the lesions in general appeared quiescent, as judged by the degree of macrophage activity as well as by the number and appearance of astrocytes and oligodendroglia. In a few smaller foci the demyelinating nature of the basic process was confirmed by the preservation of nerve fibers on silver stain, but even in these smaller lesions only a few reactive astrocytes were seen, none with discernible nuclear atypia. Moreover, whereas JC viral antigen was clearly demonstrated at biopsy, antigen was not detected in the autopsied brain sections. This contrasts with observations on formalin-fixed postmortem brains from 16 other cases of PML in which viral antigen was readily demonstrated using this same immunoperoxidase method (Rubino M: unpublished data).

Taken together, the clinical, histopathological, and virological findings indicate that progressive brain infection had been arrested. Although follow-up immunological testing was not carried out after stabilization of the patient's condition, presumably spontaneous reconstitution of cell-mediated defenses against JC virus accounted for the remission. Just as he had previously reacted to cryptococcal antigen and cleared his meningeal fungal infection, he appears to have finally mobilized effective defenses against JC virus, eliminating both productively infected oligodendrocytes and transformed astrocytes characteristic of PML. Either these infected astrocytes were of reduced viability or they were removed by reconstituted immune-

surveillance mechanisms; whatever the mechanism, these cells failed to establish independent proliferation like true tumor cells.

The present case supplements previous reports of remission in PML and for the first time directly demonstrates histopathological regression. The remitting and exacerbating course in some patients [3, 4, 6, 7, 13] and the well-documented sustained remission in this one and several others [2, 7, 8, 9, 12] indicate that PML is not invariably fatal. In some patients, immune defenses may be only slightly below the threshold needed for an adequate antiviral response, and either exogenously administered antiviral therapy or spontaneous endogenous reconstitution of immunity may allow sustained remission from brain infection. These examples provide hope for future treatment of PML.

Supported in part by US Public Health Service Grants CA22507 from the National Cancer Institute and AI11217 from the National Institute of Allergy and Infectious Disease. R. W. P. is an Irma T. Hirshl Career Scientist Awardee. M. R. is a postdoctoral trainee under Training Grant T32 CA09075 from the National Institutes of Health.

We thank Dr Jerome B. Posner for his support and comments and Adele Ahronheim for preparation of this manuscript.

References

1. Astrom KE, Mancall EL, Richardson EP Jr: Progressive multifocal leukoencephalopathy: a hitherto unrecognized complication of chronic lymphatic leukaemia and Hodgkin's disease. *Brain* 81:93-111, 1958
2. Bauer WR, Turel AP, Johnson KP: Progressive multifocal leukoencephalopathy and cytarabine. Remission with treatment. *JAMA* 226:174-176, 1973

3. Bolton CF, Rozdilsky B: Primary progressive multifocal leukoencephalopathy. A case report. *Neurology (Minneapolis)* 21:72-77, 1971
4. Hedley-Whyte ET, Smith BP, Tyler HR, Peterson WP: Multifocal leukoencephalopathy with remission and five-year survival. *J Neuropathol Exp Neurol* 25:107-116, 1966
5. Itoyama Y, Webster H deF, Sternberger NH, et al: Distribution of papovavirus, myelin-associated glycoprotein, and myelin basic protein in progressive multifocal leukoencephalopathy lesions. *Ann Neurol* 11:396-407, 1981
6. Kepes JJ, Chon SM, Price LW: Progressive multifocal leukoencephalopathy with 10-year survival in a patient with non-tropical sprue. *Neurology (Minneapolis)* 25:1006-1012, 1975
7. Marriott PJ, O'Brien MD, MacKenzie ICK, Janota I: Progressive multifocal leukoencephalopathy: remission with cytarabine. *J Neurol Neurosurg Psychiatry* 38:205-209, 1975
8. Mathews T, Wisotzkey H, Moosy J: Multiple central nervous system infections in progressive multifocal leukoencephalopathy. *Neurology (Minneapolis)* 26:9-14, 1976
9. Padgett BL, Walker DL: Virologic and serologic studies of progressive multifocal leukoencephalopathy. In Sever JL, Madden DL (eds): *Polyoma Viruses and Human Neurological Disease*. New York, Allen R. Liss, in press
10. Padgett BL, Walker DL, Zu Rhein GM, et al: JC papovavirus in progressive multifocal leukoencephalopathy. *J Infect Dis* 133:686-690, 1976
11. Richardson EP Jr: Progressive multifocal leukoencephalopathy. In Vinken PJ, Bruyn GW (eds): *Handbook of Clinical Neurology*. Vol 9, Multiple Sclerosis and Other Demyelinating Diseases. Amsterdam, North-Holland, 1970, pp 485-499
12. Selhorst JB, Ducey KF, Thomas JM, et al: PML: remission and immunologic reversals. *Neurology (NY)* 28:337, 1978
13. Stam FC: Multifocal leukoencephalopathy with slow progression and very low survival. *Psychiatr Neurol Neurochir* 69:453-459, 1966
14. Walker DL: Progressive multifocal leukoencephalopathy: an opportunistic viral infection of the nervous system. In Vinken PJ, Bruyn GW, Klawans HL (eds): *Handbook of Clinical Neurology*. Vol 34, Infections of the Nervous System, Part II. Amsterdam, North-Holland, 1978, pp 307-329
15. Weiner LP, Herndon RM, Narayan O, et al: Isolation of virus related to SV40 from patients with progressive multifocal leukoencephalopathy. *N Engl J Med* 286:385-390, 1972
16. Willoughby E, Price RW, Padgett BL, Walker DL, Dupont B: Progressive multifocal leukoencephalopathy (PML): in vitro cell-mediated immune responses to mitogens and JC virus. *Neurology (NY)* 30:256-262, 1980