

## Aphasia and left thalamic hemorrhage

ARDEN F. REYNOLDS, JR., M.D., A. BASIL HARRIS, M.D.,  
GEORGE A. OJEMANN, M.D., AND PAUL T. TURNER, M.D.

*Department of Neurological Surgery, University of Washington, Seattle, Washington,  
and Division of Neurological Surgery, University of New Mexico, Albuquerque, New  
Mexico*

✓ Left thalamic hemorrhage as a cause of aphasia has not been widely recognized. Large thalamic hemorrhages cause coma, making speech examination impossible; smaller thalamic hemorrhages were difficult to document until recent diagnostic advances. Nine cases of thalamic hemorrhage with aphasia have been described in the literature. This report presents four additional cases. These patients had acute onset of aphasia, supranuclear paralysis of upward gaze, right hemisensory deficits, and mild right hemiparesis. Three of the four patients responded to ventriculostomy drainage with rapid clearing of the supranuclear paralysis of upward gaze, and two later required placement of permanent ventricular shunts. After 1 year, two patients exhibited no clinically detectable speech malfunction and the other two were severely aphasic. The hemiparesis, hemisensory deficits, and ocular pareses all cleared. These cases are discussed with respect to present models of the role of the thalamus in speech.

**KEY WORDS** • aphasia • thalamus • hemorrhage •  
ventriculostomy • Parinaud's syndrome

**A**LTHOUGH a thalamic effect on speech has been postulated,<sup>6,16</sup> spontaneous thalamic lesions causing acute aphasia have been considered an unusual occurrence. In large part this can be attributed to the coma which confounds detailed speech testing. Nine cases of thalamic hemorrhage and two cases of hemorrhagic infarction associated with speech abnormalities have been reported in the literature.<sup>4,5,10,17</sup> Four additional cases of left thalamic hemorrhage are the subject of this report. The patients presented with aphasia, supranuclear paralysis of conjugate vertical gaze, right-sided sensory deficits, and minor right-sided motor deficits. This constellation of symptoms was initially attributed to thalamic hemorrhage by Fisher,<sup>6</sup> and reiterated in detail in reviews of the role of thalamus in speech.<sup>10,14</sup>

### Case Reports

#### Case 1

This 25-year-old right-handed man noted during intercourse the acute onset of left-sided headache and an awareness of decreased perception of all senses on the right side of the body. On examination he had a fluent aphasia with anomia and perseveration, supranuclear paralysis of upward gaze, right sixth nerve paresis, and right supranuclear facial paresis. The pupils were equal and reactive. There was decreased perception of touch, pinprick, position, and vibration on the right side of the body including the face, and a moderate right hemiparesis. Deep tendon reflexes were symmetric and plantar responses were flexor.

Retrograde femoral arteriography revealed an abnormal arterial blush in the region of

## Aphasia and left thalamic hemorrhage

the left pulvinar. An electroencephalogram (EEG) demonstrated pronounced delta activity over the left hemisphere with epileptiform discharges. Technetium-99 cerebral blood flow study and brain scan were normal. Ventriculography revealed that the floor of the trigone of the left lateral ventricle was irregular and elevated, and the fluid contained 42,500 red blood cells (RBC)/cu mm. The patient became more alert, and the upward gaze paresis resolved immediately after placement of a ventriculostomy catheter. The posterior third ventricle failed to fill as demonstrated by both pneumoencephalography and positive contrast (Conray-60) ventriculography. The diagnosis was left posterior thalamic hemorrhage due to cryptic arteriovenous malformation.

One month later there was a minimal central seventh nerve paresis and decreased graphesthesia in the right hand. The right hemiparesis had cleared. Repeat Conray ventriculography showed absence of the scalloped floor of the left lateral ventricle, and the posterior third ventricle now was well filled. Following the ventriculogram, the patient's anomia transiently returned and the right central facial paresis worsened for 12 hours.

Eight months after the initial event, neurological examination was normal. Repeat left vertebral and carotid arteriograms were normal. A Reitan psychological test battery was administered 1 year following the initial episode, and the patient still demonstrated a mild degree of aphasia. In addition, his right hand performance was slightly impaired in comparison to his left hand during complex manipulations.

### Case 2

This 39-year-old man was admitted with confusion, aphasia, and right-sided paresis. He was being treated for diabetes mellitus of adult onset and hypertension. The patient was alert with a nonfluent aphasia. He intermittently followed commands. Cranial nerve examination revealed conjugate downward deviation of the eyes which failed to move above the horizontal meridian. There was nystagmus on right lateral gaze. There was no response to visual field threat from the right. There were right fifth, twelfth, and central seventh nerve pareses. Sensory examination

revealed decreased perception of touch and pain on the right side including the face. Motor examination revealed a fluctuating right hemiparesis. Deep tendon reflexes were symmetrically depressed and the right plantar response was extensor.

A brain scan was normal and an EEG showed symmetric delta waves. Arteriography revealed flattening and a 5 mm left-to-right shift of the internal cerebral vein. Conray ventriculography revealed thinning of the posterior third ventricle with elevation and lateral deviation of the floor of the left lateral ventricle at the region of the trigone. The ventricular fluid contained 39,000 RBC/cu mm. The patient's aphasia, paralysis of upward gaze, right sensory deficit, and right hemiparesis failed to improve, despite external ventriculostomy drainage for 5 days. His neurological examination 8 weeks later was unchanged and he was transferred to a chronic care facility.

### Case 3

This 51-year-old right-handed hypertensive woman had the acute onset of headache, emesis, and shortly became unresponsive. On examination she was hypertensive, unresponsive to verbal commands, and had fixed conjugate downward deviation of the eyes which failed to move above the horizontal meridian. Lumbar puncture showed bloody cerebrospinal fluid (CSF) with 600,000 RBC/cu mm. Respirations were of Cheyne-Stokes type.

On external ventriculostomy, the initial pressure was 400 mm CSF above the brow. The ventricular fluid was bloody. With ventricular drainage the patient improved over the next 5 hours and could speak but was dysphasic. A retrograde femoral arteriogram showed flattening and left-to-right shift of the internal cerebral vein. Paralysis of upward gaze cleared after 3 days of ventricular drainage. The external ventriculostomy was removed 5 days after admission, and the patient became progressively more obtunded. A ventriculoatrial shunt was placed 4 days later, and her level of consciousness returned to normal.

The patient was contacted 1 year later and refused to return for neuropsychological testing or examination. However, she denied any language, sensory, or motor difficulties.

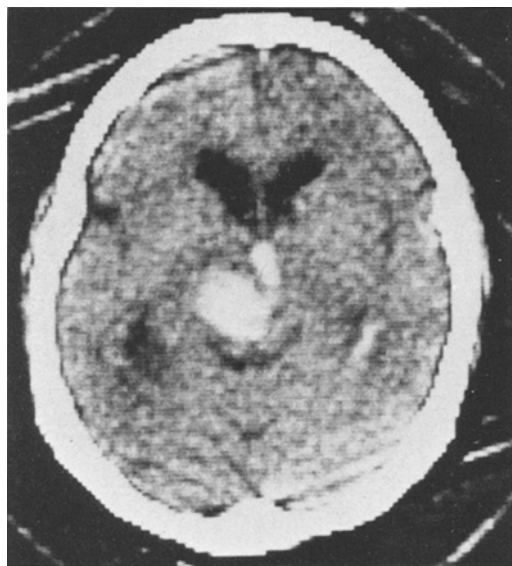


FIG. 1. Case 4. Computerized tomography scan. A large clot can be seen limited to the left thalamus except for a small extension into the third ventricle.

#### Case 4

This 44-year-old Navajo silversmith acutely developed a dysphasia, supranuclear paralysis of upward gaze, right hemiparesis, and right sensory deficit. A computerized tomography (CT) scan revealed a left thalamic hemorrhage with rupture into the posterior third ventricle (Fig. 1). He became progressively obtunded, and an external ventriculostomy was placed. An EEG showed left posterior delta activity. An arteriogram revealed an apparent vascular glioma, limited to the thalamus, as the etiology of the hemorrhage.

Supranuclear paralysis of upward gaze cleared after ventriculostomy drainage was started. He underwent a course of radiation therapy for the presumed glioma. The right-sided sensory and motor deficits markedly improved over the first week, but the aphasia remained unchanged. The patient's level of consciousness deteriorated after removal of the ventriculostomy, so a ventriculo-peritoneal shunt was placed. The patient's neurological function was stable for the 4 months of follow-up study; severe aphasia and mild right-sided sensory and motor deficits remained.

#### Discussion

In the syndrome of left thalamic hemorrhage as described by Fisher,<sup>6</sup> three cardinal features were emphasized: 1) the predominance of sensory deficits over motor deficits; 2) the presence of ocular motor disturbances, with vertical gaze being impaired by medial thalamic lesions; and 3) the presence of dysphasia, with perseveration being prominent. All of our patients showed all of these features.

The diagnosis was confirmed in our patients by arteriography in three, ventriculography in two, and CT scan in one. Thalamic hemorrhage produces typical changes in each of these diagnostic studies. The arteriographic changes include shift of the internal cerebral vein from side to side and sometimes posterior superior displacement. Lateral displacement of the basilar vein was present in one patient. A small cryptic arteriovenous malformation was present in another.

Changes evident in the ventriculogram included elevation and irregularity of the floor of the third portion of the lateral ventricle. The posterior third ventricle was irregular and poorly filled. These filling deficits were thought to represent clot in the posterior third ventricle. The CT scan showed a blood density mass in the left thalamus with third ventricular clot.

The management of left thalamic hemorrhage would seem to be best accomplished as follows. When the diagnosis is suspected on clinical grounds, it should be confirmed by CT scan. Then, if the patient has a depressed level of consciousness, supranuclear paralysis of upward gaze, or hemiparesis, a trial of ventriculostomy drainage seems indicated. Two of our patients, Cases 3 and 4, eventually required a permanent ventricular shunt system. Supranuclear paralysis of upward gaze in these patients probably reflects pressure from the hematoma on the quadrigeminal plate. The depressed level of consciousness could reflect pressure on the reticular activating system. Hemipareses are probably due to pressure on the internal capsule, since only one of the five cases that came to autopsy had extension of the hematoma into the internal capsule.<sup>4,5,10</sup> Thus, ventriculostomy may serve to decompress the quadrigeminal plate, the reticular activating system, and the internal capsule.

## Aphasia and left thalamic hemorrhage

The finding of speech disturbance without a cortical lesion is not well known. The evidence for a language deficit without cortical lesions is twofold. First, autopsy data from patients with left thalamic hemorrhage and aphasia have been reported in five instances. These patients did not have cortical lesions. The speech disturbance has been characterized as fluctuating widely,<sup>10</sup> with a paucity of spontaneous speech, occasional nonsense syllables,<sup>10</sup> and as a fluent anomia with perseveration.<sup>14</sup>

The second evidence for the role of the left thalamus in speech is from observations on patients undergoing thalamotomy, where no lesion in speech cortex was made. Acute dysphasia has been reported at clinical examination in 34% to 42% of patients after left thalamotomy.<sup>1,19</sup> Pathologically, the lesions in those patients who evidenced dysphasia were confined to the left ventrolateral nucleus or globus pallidus.<sup>8,18</sup> The incidence of the dysphasia from dorsomedial thalamotomies, even in left brain, was much less frequent, one in 90.<sup>20</sup> With formal language testing, Ojemann<sup>14</sup> found anomie errors in 62% of patients 48 hours after left ventrolateral lesions. This was significantly more frequent than before operation, or after right thalamotomy. These errors consisted of misnamings and perseverations.

Several mechanisms have been proposed to explain the role of thalamus in speech. It has been suggested that speech disturbances reflect a general deterioration of neural function with thalamic lesions.<sup>3,7,11,18</sup> Evidence against this view comes from our Cases 1, 3, and 4, where the generalized deficits cleared with ventriculostomy while the speech deficits remained. Additionally, speech disturbances seem to be associated primarily with the left thalamus, and not the right<sup>14</sup> and even there, in a rather discrete area.<sup>13,14</sup> The speech disturbances with thalamic lesions do not seem to be identical to any of those described with cortical lesions. Lesions characteristic of thalamic speech deficits include wide fluctuation in performance, with fluent speech containing widely extraneous perseverations.<sup>9,10,14</sup>

These thalamic speech deficits also differ from those seen with "conduction" aphasia, which follows disturbance of a subcortical fiber tract system running through the insula from the posterior temporal association area to Broca's area.<sup>2</sup> Patients with conduction

aphasia are unable to repeat auditory input. All four of our patients could repeat auditory input.

More recently, it has been proposed that the left thalamus is involved in attention mechanisms that are important to storage and retrieval of verbal items from both short-term and long-term verbal memory.<sup>12-16</sup> These mechanisms can be altered by electrical stimulation of the left ventrolateral thalamus where stimulation during input enhances later recall, and enhances the accuracy of naming items presented during stimulation in a pre-existing aphasia.<sup>13,14</sup> Difficulties in focusing attention and associated problems with recent memory would seem a likely explanation for the wide fluctuation in the performance and the apparent perseverative intrusion of unrelated verbal material,<sup>9</sup> the hallmarks of "thalamic" language disturbances. Left thalamic mechanisms also seem to be involved in coordinating the motor aspects and the respiratory substrate of speech.<sup>12</sup> Damage to these mechanisms may also be important in some of the more severe output deficits with thalamic lesions, as in our Case 2.<sup>1</sup>

### References

1. Bell DS: Speech functions of the thalamus inferred from the effects of thalamotomy. *Brain* **91**:619-638, 1968
2. Benson DR, Sheremata WA, Bouchard R, et al: Conduction aphasia. A clinicopathological study. *Arch Neurol* **28**:339-346, 1973
3. Brown JW: Language, cognition and the thalamus. *Confin Neurol* **36**:33-60, 1974
4. Bugiani O, Conforto C, Sacco G: Aphasia in thalamic haemorrhage. *Lancet* **1**:1052, 1969 (Letter)
5. Ciemins VA: Localized thalamic hemorrhage. A cause of aphasia. *Neurology* **20**:776-782, 1970
6. Fisher CM: The pathologic and clinical aspects of thalamic hemorrhage. *Trans Am Neurol Assoc* **84**:56-59, 1959
7. Geschwind N: Discussion on cerebral connections and brain function, in Darley FI, Millikan CH (eds): *Brain Mechanisms Underlying Speech and Language*. New York: Grune and Stratton, 1967, pp 71-72
8. Hermann K, Turner JW, Gillingham FJ, et al: The effects of destructive lesions and stimulation of the basal ganglia on speech mechanisms. *Confin Neurol* **27**:197-207, 1966
9. Luria AR: On quasi-aphasic speech disturbances in lesions of the deep structures of the brain. *Brain Lang* **4**:432-459, 1977

10. Mohr JP, Watters WC, Duncan GW: Thalamic hemorrhage and aphasia. **Brain Lang** 2:3-17, 1975
11. Nielsen JM: **Agnosia, Apraxia, Aphasia: Their Value in Cerebral Localization.** New York/London: PB Hoeber, 1946, 292 pp
12. Ojemann GA: Asymmetrical function of the thalamus in man. **Ann NY Acad Sci** 299: 380-396, 1977
13. Ojemann GA: Language and the thalamus: object naming and recall during and after thalamic stimulation. **Brain Lang** 2:101-120, 1975
14. Ojemann GA: Subcortical language mechanisms, in Whitaker H, Whitaker HA (eds): **Studies in Neurolinguistics.** New York: Academic Press, 1975, Vol. 2, pp 103-138
15. Ojemann GA, Blick KI, Ward AA Jr: Improvement and disturbance of short-term verbal memory during human ventrolateral thalamic stimulation. **Trans Am Neurol Assoc** 94:72-75, 1969
16. Penfield W, Roberts L: **Speech and Brain Mechanisms.** Princeton, NJ: Princeton University Press, 1959, 286 pp
17. Samarel A, Wright TL, Sergay S, et al: Thalamic hemorrhage with speech disorder. **Trans Am Neurol Assoc** 101:283-285, 1976
18. Samra K, Riklan M, Levita E, et al: Language and speech correlates of anatomically verified lesions in thalamic surgery for Parkinsonism. **J Speech Hearing Res** 12:510-540, 1969
19. Selby G: Stereotactic surgery for the relief of Parkinson's disease. Part 2. An analysis of the results of a series of 303 patients (413 operations). **J Neurol Sci** 5:343-375, 1967
20. Spiegel EA, Wycis HT: **First International Symposium on Stereoccephalotomy.** New York: S Karger, 1962

---

This research was supported by NIH Research Grant NS-05211 awarded by the National Institute of Neurological and Communicative Disorders and Stroke.

Dr. Harris and Dr. Ojemann are affiliates of the Child Development and Mental Retardation Center, University of Washington.

*Address reprint requests to:* Arden Reynolds, M.D., Division of Neurosurgery, University of New Mexico, 915 Stanford Drive N.E., Albuquerque, New Mexico 87131.