

- clearing compartments. *Stroke* 5: 607-611, 1974
17. Meyer JS, Hayman LA, Yamamoto M, Sakai F, Nakajima S: Local cerebral blood flow measured by CT after stable xenon inhalation. *AJNR* 1: 213-225, 1980
  18. Fieschi C, Bozzao L, Agnoli A, Nardini M, Bartolini A: The hydrogen method of measuring local blood flow in subcortical structures of the brain. Including a comparative study with the 14-antiypriene method. *Exp Brain Res* 7: 111-119, 1969
  19. Pasztor E, Symon L, Dorsch NWC, Branston NM: The hydrogen clearance method in assessment of blood flow in cortex, white matter and deep nuclei of baboons. *Stroke* 4: 556-567, 1973
  20. v.Kummer R, Kohtes U: Local CBF and vascular reactivity measured by chronically implanted electrodes. In Betz E, Grote J, Heuser D, Wullenweber R (eds): *Pathophysiology and Pharmacotherapy of cerebrovascular disorders*, Baden-Baden, Köln, New York, Gerhard Witzstrock Verlag, p 8-11, 1980
  21. Aukland K, Bower BF, Berliner RW: Measurement of local blood flow with hydrogen gas. *Circ Res* 14: 164-187, 1964
  22. Reinoso-Suarez F: *Topographischer Hirnatlas der Katze für experimentale-physiologische Untersuchungen*. E. Merck AG, Darmstadt, 1961
  23. Zierler KL: Equations for measuring blood flow by external monitoring of radioisotopes. *Circ Res* 16: 309-321, 1965
  24. Haining JC, Don Turner M, Pantall RM: Measurement of local cerebral blood flow in the unanesthetized rat using a hydrogen clearance method. *Circ Res* 23: 313-324, 1968
  25. Fein JM, Willis J, Hamilton J, Parkhurst J: Polarographical measurement of local cerebral blood flow in the conscious and anesthetized primate. *Stroke* 6: 42-51, 1975
  26. Nordby HK, Flood S: A long term observation of local cerebral blood flow using the hydrogen gas clearance technique. *Acta Neurochirurgica* 35: 65-69, 1976
  27. Smith AJK, McCreery DB, Bloedel JR, Chou SN: Hyperemia, CO<sub>2</sub>-responsiveness, and autoregulation in the white matter following experimental spinal cord injury. *J Neurosurg* 48: 239-251, 1978
  28. v.Kummer R, Hartmann A, Buttinger C, Kohtes U: Problems using hydrogen for measurement of local cerebral blood flow. In Cervós-Navarro, Fritschka E (eds): *Cerebral microcirculation and metabolism*, New York, Raven Press, 1981
  29. James IM, Millar RA, Purves MJ: Observations on the extrinsic neural control of cerebral blood flow in the baboon. *Circ Res* 25: 77-93, 1969
  30. Wilkinson IMS, Browne DRG: The influence of anaesthesia and of arterial hypocapnia on regional blood flow in the normal human cerebral hemisphere. *Brit J Anaesth* 42: 472-482, 1970
  31. Severinghaus JW, Lassen N: Step hypocapnia to separate arterial from tissue PCO<sub>2</sub> in the regulation of cerebral blood flow. *Circ Res* 20: 272-278, 1967
  32. Skinhøj E, Paulson OB: Carbon dioxide and cerebral circulatory control. *Arch Neurol* 20: 249-252, 1969
  33. Shalit MN, Reinmuth OM, Shimoyjo S, Scheinberg P: Carbon dioxide and cerebral circulatory control III. The effects of brain stem lesions. *Arch Neurol* 17: 342-353, 1967

## Cerebral Infarction Associated with Lupus Anticoagulants — Preliminary Report

ROBERT G. HART, M.D.,\* VINCENT T. MILLER, M.D.,† BRUCE M. COULL, M.D.,‡ AND  
VERA BRIL, M.D.§

**SUMMARY** Hypercoagulability may contribute to stroke in young adults. Lupus anticoagulants (LA) were identified in six patients (4%) of 145 young adults with cerebral infarction. The clinical features of the 6 patients in this survey plus an additional patient from another institution with LA-associated stroke are presented. Four had systemic lupus erythematosus and 3 had idiopathic LA; all had mild thrombocytopenia. In 2 patients, no other conditions associated with stroke were discovered after thorough evaluation. Recurrent arterial thrombosis occurred in 4 of 7 patients during an average of two years of follow-up. Evidence suggests that inhibition of prostacyclin formation may occur with LA, promoting a prothrombotic state.

Stroke Vol 15, No 1, 1984

LUPUS ANTICOAGULANTS (LA) are acquired IgG or IgM immunoglobulins which inhibit coagulation by interfering with the phospholipid portion of the prothrombin activator complex.<sup>1,2</sup> Although it initially described in patients with systemic lupus erythematosus (SLE) 30 years ago, they have been associated with the use of phenothiazines, non-SLE autoimmune disease, neoplasms, and drug-induced lupus as well as

occurring idiopathically.<sup>1-5</sup> The laboratory hallmark is a prolonged partial thromboplastin time (PTT) which fails to normalize when affected plasma is mixed with normal plasma. Additionally, mild thrombocytopenia and a false-positive VDRL are often associated with LA.

Despite their function as *in vitro* anticoagulants, LA are, paradoxically, most often associated with thrombosis and not abnormal bleeding.<sup>6</sup> Mueh et al recently reported thrombotic events in eight of 35 patients with LA.<sup>4</sup> Most clinical events have involved venous thromboembolism, but arterial thrombosis with attendant stroke (3 patients) and TIA (3 patients) has been reported.<sup>2, 4, 7-9</sup>

We report the clinical features of cerebral infarction associated with LA occurring in seven young adults. Of these patients, 6 were identified in a retrospective, population-based survey of 145 young adults with ce-

From the Department of Medicine (Neurology),\* University of Texas Health Science Center, San Antonio, Texas; the Department of Neurology,† Northwestern University Medical School, Chicago, Illinois; the Department of Neurology,‡ Oregon Health Science University, Portland, Oregon; and Toronto General Hospital,§ Toronto, Ontario, Canada.

Address correspondence to: Robert G. Hart, M.D., Department of Medicine (Neurology), University of Texas Health Science Center, 7703 Floyd Curl Drive, San Antonio, Texas 78284.

Received March 3, 1983; revision accepted June 21, 1983.

TABLE 1 Laboratory Criteria of Lupus Anticoagulants\*

A. Primary laboratory criteria	
1)	prolongation of PTT more than 5 seconds beyond normal range
2)	incomplete correction of PTT after 1:1 mixture with normal plasma, remaining at least 5 seconds longer than normal plasma
3)	abnormal dilute tissue thromboplastin assay
B. Associated laboratory features	
1)	mild thrombocytopenia
2)	slight prolongation of prothrombin time
3)	false-positive VDRL

\*PTT is partial thromboplastin time, kaolin clotting time may be substituted for PTT.

rebral infarction.<sup>10</sup> In two patients, the absence of other conditions associated with stroke suggests a role of LA in the etiology of cerebral infarction.

### Methods

There were 6 patients (4%) with LA identified in a retrospective survey of hospital records of 145 young adults (age less than 40) who had cerebral infarction which occurred during the years 1975–1981 at 10 hospitals in Portland, Oregon. A prolonged PTT was the initial evidence that led to further characterization. Many patients with an obvious cause of stroke (eg., prosthetic valve) were not screened with a PTT.

Cerebral infarction was defined as the abrupt onset of a persistent focal neurologic deficit without hemorrhage on computed tomography (CT). Patients with slowly (over hours) evolving deficits or deficits associated with seizures, diffuse encephalopathy or abnormalities of the cerebrospinal fluid (CSF) were excluded to avoid inclusion of patients with lupus cerebritis. LA were considered to be present when the initial two criteria of table 1A were present. In 4 patients, all three criteria were met. Further hematologic testing to fulfill all criteria was not possible in the remaining two patients who were lost to follow-up. An additional patient (VB) was not part of the retrospective survey but was identified at another center.

TABLE 2 Clinical Features of Cerebral Infarction and Lupus Anticoagulant

Patient	Age/Sex	Etiology	Events	PTT*	PT*	Platelets	Arteriography	Related features
DG	42M	idiopathic‡	3 CI	58	14.1	78,000	branch occlusions	none
SH	40F	SLE†	multiple CI	73	12.6	140,000	carotid stenosis	marantic endocarditis, spontaneous abortion
JW	37F	SLE	3 CI	48	11.7	78,000	not done	mitral prolapse, spontaneous abortion, false (+) VDRL
CD	18F	SLE	1 CI	58	11.4	85,000	normal	classic migraine, spontaneous abortion, false (+) VDRL
AP	20F	idiopathic	1 CI	115	12.2	125,000	carotid siphon occlusion	oral contraceptives
TS	28F	SLE	1 CI	64	12.1	82,000	not done	brachial artery occlusion
VB	23F	idiopathic	1 CI	43	11.0	110,000	branch occlusion	oral contraceptives, crural venous thrombosis

\*PTT is partial thromboplastin time in seconds, upper limit of normal is 40 seconds. PT is prothrombin time in seconds. SLE is systemic lupus erythematosus. CI is cerebral infarction.

†See text for details, clinically typical of SLE but antinuclear antibodies were never demonstrated.

‡Idiopathic implies absence of other medications or other disease to explain presence of the inhibitor.

### Results

Our survey of cerebral infarction in patients 40 years-old or less revealed that at least 6 (4%) had LA. With the additional patient with LA and stroke who was not part of this survey, clinical information is available for seven patients (table 2). There were 6 females and one male. All had mild thrombocytopenia. Four patients with stroke and LA also had SLE; stroke was the presenting feature of SLE in 3 of these patients. Two patients with SLE had false-positive VDRL tests for syphilis. One patient had clinical venous thrombosis, and another had multiple new and old pulmonary emboli at postmortem examination. In patients with idiopathic LA, two were receiving no medications and one had recently started oral contraceptives at the time of the initial stroke. The LA persisted after cessation of oral contraceptives in this last patient.

Other conditions that may predispose to cerebral infarction were seen in five patients (table 2): mitral valve prolapse, classic migraine, recent initiation and recent discontinuation of oral contraceptive use and a combination of marantic endocarditis and atherosclerosis were each found in one patient. Follow-up was brief, averaging only two years, but four patients (56%) experienced recurrent ischemia (table 3). Three recurrent episodes involved the brain and one an extremity.

Three illustrative patients are described:

#### Case 1

DG was a previously healthy 35 year-old man who experienced sudden right hemiparesis and aphasia. There was no history of migraine or substance abuse. General physical examination, complete blood count, EKG and echocardiography were normal. No coagulation studies were initially done. Cerebral arteriography revealed multiple branch artery occlusions of the left middle cerebral artery. Deficits slowly improved, although residual hemiparesis and nonfluent dysphasia were permanent. A platelet number estimate by peripheral smear, done six months later at the time of

TABLE 3 *Subsequent Events in Lupus Anticoagulant and Stroke*

Patient	Follow-up years	Therapy	Events
DG	7	none	2 CI
SH	1	immunosuppressives	multiple CI at autopsy
JW	3	immunosuppressives	2 CI
CD	2	none	none
AP	2	none	none
TS	1	immunosuppressives	limb artery thrombosis
VB	0	anticoagulants	?

CI is cerebral infarction.

elective circumcision, was slightly low. He was started on phenytoin after a generalized convulsion one year after stroke.

Five years later, he complained of sudden headache and was found to be confused with garbled speech. Neurological examination revealed the residua of his prior stroke plus severe dysarthria. Anti-nuclear antibody (ANA) testing, serum complement levels, LE preparation, protein electrophoresis, prothrombin time (PT), CSF examination and cerebral arteriography were all normal. Platelet count was 110,000 (normal > 150,000). CT scan showed bilateral hypodense areas consistent with cerebral infarctions. Cardiology consultation, EKG and echocardiography again disclosed no abnormalities of the heart. He was treated with aspirin and dipyridamole, but he was known to be poorly compliant.

Two years later (seven years after his first stroke) he experienced sudden worsening of right hemiparesis. General examination was again normal. Complete blood counts were normal except for a platelet count of 78,000. The PTT was 57.8 seconds (normal < 40 seconds) and incompletely corrected with a 1:1 dilution with normal plasma. Prothrombin time was minimally prolonged at 14.1 seconds (control was 12 seconds). Tissue thromboplastin dilution test was abnormal, indicative of a circulating anticoagulant. Erythrocyte sedimentation rate (ESR) was 12 mm/hr. Serum ANA, rheumatoid factor, serum cryoglobulin titers and protein electrophoresis were again normal. Antiplatelet antibodies were not detected by direct or indirect immunofluorescent techniques. Echocardiography and cerebral arteriography were again normal. CT (figure 1) showed multiple, bilateral cerebral hypodensities. The prolonged PTT persisted after discontinuation of phenytoin.

Comment: The presence of LA was only appreciated during evaluation of the third episode of stroke, as no PTT was done on prior evaluations. Longstanding thrombocytopenia, however, suggests that LA may have been present during the initial strokes. No other conditions associated with recurrent cerebral infarction were identified despite extensive search.

#### Case 2

SH was a 40 year-old left-handed woman who experienced sudden headache and trouble speaking. Six

years earlier she had a spontaneous abortion, at which time her PTT was normal and ANA were absent. There was a history of hypertension and migratory polyarthralgias. Physical examination was remarkable for a malar rash and alexia without agraphia. Extensive laboratory investigation included a hemoglobin of 15 gm/dl, an ESR of 50 mm/hr, PTT of 73.1 seconds without corection with 1:1 dilution with normal plasma, absent ANA and anti-DNA antibodies on repeated testing, absent cryoglobulins, normal serum protein electrophoresis, and negative rheumatoid factor and VDRL. Dilute tissue thromboplastin inhibition testing was indicative of a circulating anticoagulant. Serum complement and fibrinogen levels were normal; fibrin degradation products were minimally present. There was moderate proteinuria (1 gram/24 hours). CSF examination, CT scan and echocardiography were normal. Platelet aggregation responses and beta-thromboglobulin assay were normal. Cerebral arteriography showed moderate (50%) stenoses of the origins of both internal carotid arteries as the only abnormalities.

She was treated with prednisone (60 mg/day) for presumed sero-negative SLE. Repeat laboratory studies one month later revealed an ESR of 34 mm/hr, PTT of 38 seconds and persistent proteinuria. Renal biopsy revealed a mixed membranous and mesangioproliferative glomerulonephritis with heavy mesangial deposits of IgG and IgA by immunofluorescent staining consistent with SLE.

Nine months after her initial stroke she experienced a sudden seizure-like event and was re-evaluated. Neurological examination was normal except for persistent alexia. PTT was 44 seconds and moderate proteinuria persisted. Complement titers, ANA titers, anti-DNA

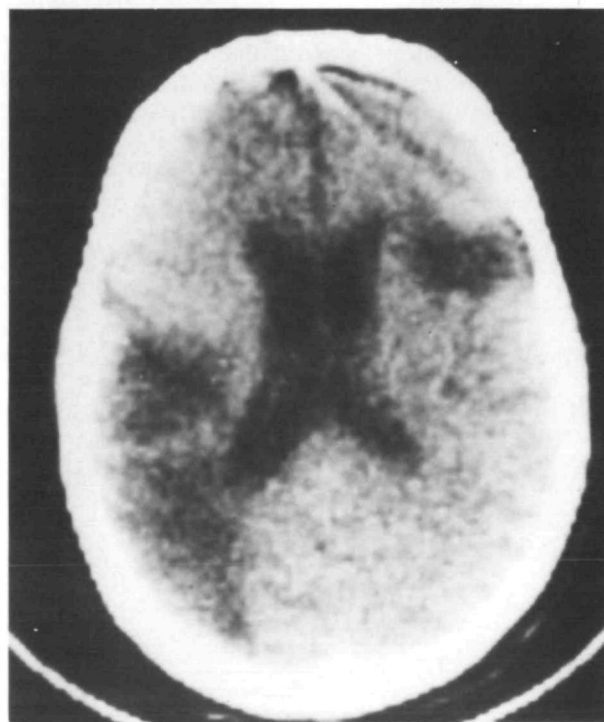


FIGURE 1. CT of patient 1 (DG) demonstrating multiple low density areas consistent with cerebral infarction.

antibody assay and CSF were normal. A CT scan revealed a new hypodense area in the left cerebellum. A purpuric skin lesion was biopsied but no evidence of vasculitis was found. Azathioprine was started (150 mg/day). Her PTT remained persistently elevated (50 seconds) on follow-up testing.

Thirteen months after the initial stroke she underwent urgent laparotomy for an acute abdomen. PTT was 63 seconds, ESR was 47 mm/hr, platelet count was 117,000, PT was 12 seconds, and red blood cell morphology was normal. An infarcted colon was resected, but the patient rapidly succumbed to septic shock postoperatively.

Autopsy showed atherosclerotic vascular disease involving the coronary, carotid and renal arteries as well as the aorta. A 3 mm noninfective (marantic) vegetation was present on the mitral valve without accompanying inflammation or necrosis of valvular ground substance. Multiple areas of small infarction of varying age were present in the myocardium and cerebral cortex, the largest involving 2 cm of cortex. Thrombotic occlusion of small vessels was seen in many organs, including the brain. However, there was no inflammation of the adjacent vessel walls. There was minimal atherosclerotic involvement of the intracranial arteries.

Comment: The PTT fluctuated during the course of her illness but was most elevated during clinical thrombotic episodes. Despite the repeatedly negative testing for ANA during active disease, her illness was typical of SLE with associated lupus anticoagulants.

### Case 3

CP was a 23 year-old woman who presented with sudden left hemiparesis and ataxia. For six months prior to admission she had livedo reticularis involving arms and legs, and recurrent episodes of pleuritic chest pain. She had used oral contraceptives intermittently for three years, and discontinued this medication one week before admission. Hypertension (BP 220/130 mm Hg) was noted on admission as well as livedo reticularis, but her general physical examination was otherwise unremarkable. Initial CT scan of the head was normal. Chest x-ray, EKG, and two-dimensional (2D) echocardiogram were normal. Hemoglobin, white cell count, serum electrolytes, VDRL, CSF studies and serum complement levels were all normal. Platelet count was 110,000/mm.<sup>3</sup> ESR was 12 mm/hr. ANA, LE cell preparations and anti-DNA assay were normal. Prothrombin time was normal, but PTT was prolonged (patient = 43 sec, control = 29 sec) with failure to correct on mixing with normal plasma. Renal biopsy showed a proliferative glomerulopathy with mesangial IgM deposits.

Cerebral arteriography showed a branch occlusion of the right middle cerebral artery. Repeat CT demonstrated a lucent area in the right internal capsule. PTTs remained prolonged during treatment with dipyridamole and sulfinpyrazone.

Three weeks after her stroke, she developed left leg swelling and pain. Venography revealed extensive old and recent thromboses. She was placed on anticoagulants but was lost to follow-up shortly thereafter.

### Discussion

The association of LA and cerebral infarction, as described in our patients, does not necessarily imply a cause and effect. About 10% of all patients with SLE have LA. Patients with SLE have many reasons for stroke, including inflammatory arteritis, cortical vein thrombosis, Libman-Sacks or infective endocarditis with embolism, other coagulation and fibrinolytic aberrancies,<sup>7, 9, 11</sup> and atherosclerosis related to frequent coexistence of hypertension. Further, sudden onset of relatively focal cerebritis may simulate large or medium-sized vessel occlusion and be difficult to clinically distinguish from conventional cerebral infarction.

However, Carreras et al have shown that plasma from many patients with LA inhibits production of prostacyclin — a potent vasodilator and platelet anti-aggregant.<sup>2, 12</sup> Inhibition of prostacyclin formation by LA might well predispose to thrombosis, as suggested by several investigators.<sup>2, 12, 13</sup> In two of our patients (DS, TS), no other conditions predisposing to cerebral infarction were discovered after thorough evaluation except idiopathically occurring LA.

Correlation between the degree of elevation of PTT, quantitative titer of inhibitor and/or other laboratory features of LA with propensity for thrombosis has not been clearly established. Carreras and Vermynen reported an average 2.4 times prolongation of PTT in four LA patients with recurrent thrombosis, 2.2 times in four LA patients with single thrombotic events, and 1.8 times in six LA patients without thrombosis.<sup>2</sup> Meuh et al reported an average prolongation of PTT by a factor of 2.2 in two LA patients with arterial thrombosis and by 1.7 in six LA patients with venous thrombosis.<sup>4</sup> Our patients with cerebral infarction had an average increase in PTT by a factor of 2.0. Carreras and Vermynen preliminarily reported that inhibition of prostacyclin production correlated with degree of prolongation of PTT ( $p < 0.015$ ) and presence of thrombosis ( $p < 0.20$ ).<sup>2</sup> Although thrombocytopenia is seen in 30% of all patients with the LA,<sup>4</sup> four of eight patients with LA and thrombosis in Mueh et al's series<sup>4</sup> and all of our patients had thrombocytopenia. Elevation of factor VIII, LA, thrombocytopenia and stroke have been seen in one patient.<sup>14</sup>

In several other of our patients, LA coexisted with other disorders that may predispose to stroke. A prothrombotic state associated with LA might act in synergy with migraine, mitral valve prolapse and/or oral contraceptive use to produce stroke, although stroke occurs in association with each of these conditions without LA.<sup>10</sup>

Marantic (nonbacterial, thrombotic) endocarditis was found in one patient with multiple, noninflammatory small vessel occlusions. Marantic endocarditis is often associated with coagulation abnormalities which are thought to predispose to occurrence of noninfective thrombi on cardiac valves. The presence of LA in our patient could be fortuitous or, perhaps, predispose to marantic endocarditis. Five other patients had 2D echocardiography and valvular lesions were not demonstrated. Platelet-fibrin thrombi without inflammation of vessel walls are common in large vessel occlu-

sion in SLE as well as in small vessels in lupus cerebritis.<sup>11</sup> Altered coagulability with *in situ* thrombosis or embolism could explain these nonvasculitic occlusions.

In our retrospective survey, at least 6 of 145 (4%) of young adults with cerebral infarction had LA. The cause of stroke in young adults is often unclear, even after thorough evaluation seeking known conditions predisposing to stroke.<sup>10</sup> The PTT may fluctuate to within the normal range in patients with LA and may not be an ever-present marker of these antibodies (as in patient SH). Further, the sensitivity of PTT in detecting the LA has been shown to be reagent dependent,<sup>15</sup> and more easily detectable when platelet counts are low.<sup>15</sup> Kaolin clotting time may be a more sensitive screening test than PTT for LA.<sup>2, 16</sup>

Lupus anticoagulants are present in older patients, most of whom do not have SLE.<sup>14</sup> We have recently evaluated a 71 year-old man with multiple, bilateral cerebral infarctions occurring over 2 years in association with LA. Bilateral carotid endarterectomies were done for minimal bifurcation plaques but with subsequent recurrent stroke.

Other disorders of coagulation associated with stroke may superficially mimic LA. Diffuse intravascular coagulation (DIC) is an acquired syndrome of hemorrhage and thrombosis that occurs in a variety of diseases.<sup>17</sup> It is an acute or chronic consumptive coagulopathy with neurologic involvement ranging from diffuse encephalopathy to brain infarction and hemorrhage. Laboratory hallmarks are a prolonged PT, thrombocytopenia, hypofibrinogenemia and elevated fibrinogen degradation products. The PTT is frequently prolonged in DIC, but usually corrects when diluted with normal plasma. Large artery occlusions in DIC patients have frequently coexisted with nonbacterial thrombotic (marantic) endocarditis with presumed embolism.<sup>17</sup>

Thrombotic thrombocytopenic purpura (TTP) may present with stroke but is not easily confused with LA. TTP is usually a malignant syndrome with microangiopathic hemolytic anemia, fever, renal impairment and neurologic dysfunction.<sup>18</sup> Thrombocytopenia is usually marked, anemia is invariable, and PTT is normal in 94% of TTP patients.<sup>18</sup> Chronic and/or recurrent TTP is rare but may be associated with minimal anemia and thrombocytopenia; coagulation studies have been normal.<sup>19</sup> Other conditions which may superficially resemble LA include occult, low-dose heparin administration, vitamin K deficiency, severe liver disease and improper collection of blood (partial clotting).

With etiologic uncertainty surrounding the association of LA and cerebral infarction, appropriate treatment of such patients is unclear. Recurrent arterial thrombosis has occurred disturbingly often. Anticoagulants have been used in patients with recurrent deep venous thrombosis associated with LA.<sup>4</sup> Based on the possible mechanism of prostacyclin inhibition, aspirin

therapy may be empirically advised until further data are forthcoming.<sup>20, 21</sup>

### Acknowledgments

The authors express their gratitude to Brewster Smith, M.D. for referring one of the patients, J. Donald Easton, M.D., and Shirley Levine, M.D. for reviewing the manuscript, and Melissa Rice for secretarial assistance.

### References

- Schleider MA, Nachman RL, Jaffee EA, Coleman M: A clinical study of the lupus anticoagulant. *Blood* **48**: 499-509, 1976
- Carreras LO, Vermeylen JG: "Lupus" anticoagulant and thrombosis—possible role of inhibition of prostacyclin formation. *Thromb Haemostat* **48**: 38-40, 1982
- Conley CL, Hartmann RC: A hemorrhagic disorder caused by circulating anticoagulant in patients with disseminated lupus erythematosus. *J Clin Invest* **31**: 621-622, 1952
- Meuh JR, Herbst KD, Rapaport SI: Thrombosis in patients with lupus anticoagulant. *Ann Int Med* **92**: 156-159, 1980
- Edwards RL, Rick ME, Wakem CJ: Studies on a circulating anticoagulant in procainamide-induced lupus erythematosus. *Arch Int Med* **141**: 1688-1690, 1981
- Bowie EJW, Thompson JH, Pascuzzi CA, Owen CA: Thrombosis in systemic lupus erythematosus despite circulating anticoagulants. *J Lab Clin Med* **62**: 416-430, 1963
- Angles-Cano E, Sultan Y, Clauvel JP: Predisposing factors to thrombosis in systemic lupus erythematosus. *J Lab Clin Med* **94**: 312-21, 1979
- Landi G, Calloni MV, Candelise L: Recurrent ischemic attacks in two young adults with lupus anticoagulant. *Stroke* **14**: 377-379, 1983
- Jungers P, Dougados M, Gazengel C, Tron F, Bach JF: Manifestations thromboemboliques au cours du lupus érythémateux disséminé. *Annales de Medecine Intern (Paris)* **131**: 395, 1980
- Hart RG, Miller VT: Cerebral infarction in young adults: a practical approach. *Stroke* **14**: 110-114, 1983
- Paterson A, Timperley W, Slater D: Coagulation abnormalities in fatal cerebral lupus erythematosus. *J Royal Soc Med* **74**: 53-55, 1981
- Carreras LO, Defreyn G, Machin SJ, Vermeylen J, Deman R, Spitz B, van Assche A: Arterial thrombosis, intrauterine death and "lupus" anticoagulant. *Lancet* **1**: 244-246, 1981
- Marchesi D, Parbtani A, Frampton G, Livio M, Remuzzi G, Cameron JS: Thrombotic tendency in systemic lupus erythematosus. *Lancet* **1**: 719, 1981
- Waddell CC, Brown JA: The lupus anticoagulant in 14 male patients. *JAMA* **248**: 2493-2495, 1982
- Mannuci PM, Canciani MT, Mari D, Meucci P: The varied sensitivity of partial thromboplastin and prothrombin time reagents in the demonstration of the lupus-like anticoagulant. *Scand J Haematol* **22**: 423-432, 1979
- Exner T, Richard KA, Kronenberg H: A sensitive test demonstrating lupus anticoagulant and its behavioral patterns. *Br J Haematol* **40**: 143-151, 1978
- Schwartzman RJ, Hill JB: Neurologic complications of disseminated intravascular coagulation. *Neurology* **32**: 791-797, 1982
- Ridolfi RL, Bell WR: Thrombotic thrombocytopenic purpura. Report of 25 cases and review of the literature. *Medicine* **60**: 413-427, 1981
- Cuttner J: Chronic thrombotic thrombocytopenic purpura: report of a case with five relapses and review of the literature. *Mt Sinai J of Med* **45**: 418-425, 1978
- Masotti G, Gallanti G, Poggessi L et al: Differential inhibition of prostacyclin production and platelet aggregation by aspirin. *Lancet* **2**: 1213-1216, 1979
- Boey ML, Colaco CB, Ghoravi AE, et al: Thrombosis in systemic lupus erythematosus: striking association with the presence of circulating lupus anticoagulant. *Brit Med J* **287**: 1021-1023, 1983