

Interhemispheric subdural hematoma

Case report

ALAN H. FRUIN, M.D., GREGORY L. JUHL, B.S., AND CHARLES TAYLON, M.D.

Division of Neurological Surgery, Department of Surgery, Creighton University School of Medicine, Omaha, Nebraska

✓ A case of interhemispheric subdural hematoma (ISH) is presented and discussed. This disorder is a rare form of intracranial hemorrhage, which classically presents as an isolated paresis of one leg or a hemiparesis worse in the leg than the arm. The majority of cases are due to occipital trauma because of the anatomy of the bridging veins. Chronic interhemispheric hematomas are rare since the natural history of these lesions is to spread out over the cerebral convexity. Conservative treatment for ISH may be beneficial unless neurological deterioration necessitates early operative intervention.

KEY WORDS • brain injury • head injury • subdural hematoma • interhemispheric subdural hematoma

INTERHEMISPHERIC subdural hematoma (ISH) is a rare form of posttraumatic intracranial hemorrhage. Only 13 such cases have previously been reported in the literature.^{1,2,4-6,9,10,13,14,16,17} Neurological deterioration has required early operative intervention in these cases. We report a case of an acute traumatic ISH managed nonoperatively. The literature is reviewed and the unique aspects of this entity are presented and discussed.

Case Report

This 59-year-old man fell at work and struck his occiput. There was no history of loss of consciousness. The patient was seen at a clinic where a scalp laceration was sutured. Skull roentgenograms and neurological examination at that time were normal. Over the next 24 hours he experienced continuous headaches and two episodes of vomiting. Eighteen hours after the fall he began to develop numbness and weakness in his left leg. He was taken to the emergency room 24 hours after the injury, and a marked left lower-extremity monoparesis was noted. Computerized tomography (CT) of the head revealed a right ISH (Fig. 1 *left*). Since the patient was awake and alert, it was decided to initially treat him medically. An intracranial pressure (ICP) monitor was inserted, and ICP was recorded as 20 mm Hg. Intermittent mannitol was given to maintain an ICP of 15 mm Hg or less. Despite adequate control of

the patient's ICP, mild weakness developed in his left arm, and the left leg became totally paretic. The ICP eventually fell to below 10 mm Hg, and mannitol was discontinued on the 6th day after injury. The ICP monitor was removed 1 week later. After the ICP returned to a normal level, there was gradual improvement in the patient's left-sided weakness, which completely cleared by 6 weeks after the fall. During this period, a CT scan showed a gradual shift of the ISH to the right cerebral convexity 4 weeks after trauma (Fig. 1 *center*). By 10 weeks, the hematoma had completely resolved (Fig. 1 *right*).

Discussion

Interhemispheric subdural hematoma is a rare clinical entity first described by Aring and Evans in 1940.¹ The classical presentation of this disorder is a contralateral monoparesis of the leg or a hemiparesis in which the leg is weaker than the arm. This symptom complex has been called the "falx syndrome,"^{11,13} and was noted to be present in 10 of the 13 previously reported cases.^{1,2,4-6,9,10,13,14,16,17} The only other symptoms consistently associated with this disorder include headache, vomiting, and seizures (Table 1). A history of loss of consciousness or evidence of skull fracture is not commonly associated with ISH (Table 1).

The site of injury, however, does appear to be significant. In eight of the cases reported to date, the site

Interhemispheric subdural hematoma

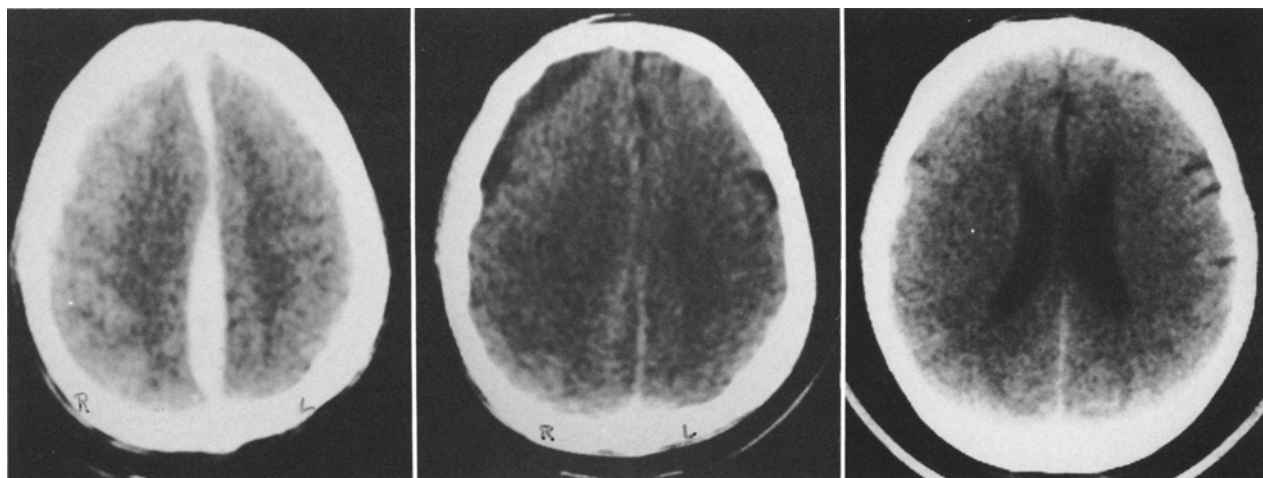


FIG. 1. Computerized tomography scans showing the course of the interhemispheric subdural hematoma. *Left:* Scan at 24 hours post-injury showing the acute hematoma. *Center:* Scan at 4 weeks post-injury showing shift of the hematoma to the convexity as it became chronic. *Right:* Scan at 10 weeks post-injury showing complete resolution of the hematoma.

of the trauma was given: in six of these the trauma was occipital (Table 1). It has also been shown that the cause of ISH is the tearing of a bridging vein between the cerebral cortex and the superior sagittal sinus.⁶ The anatomy of these veins is such that they course anteromedially before entering the sinus.⁷ A sharp blow to the occiput in the sagittal plane would cause posterior movement of the cerebral hemisphere relative to the fixed sinus. Such a movement would maximally stretch the veins, making them vulnerable to tearing.

Although chronic subdural hematomas make up 25% to 50% of all subdural hematomas,^{3,12,15} among the 14 cases of ISH documented to date only one may have been chronic.¹⁶ The paucity of reported cases of chronic ISH may be explained by the tendency of the acute ISH to migrate over the convexity as it liquefies. This phenomenon was present in our case, and also in a case

reported by Ogsbury, *et al.*¹³ These are the only two reported cases of ISH not treated surgically during the acute phase. In a large series of chronic subdural hematomas, Hirakawa, *et al.*,⁸ found no cases of chronic ISH. However, they noted that occipital trauma was the etiology in 30% of their cases. The possibility thus arises that some chronic convexity subdural hematomas may originate as ISH.

Finally, with the proposed progression of this disorder in mind, a somewhat broader outlook in the management of ISH than has been advocated previously may be in order. Prompt surgical intervention has been recommended as the only safe and acceptable method of treatment,^{4,6,10,14} but this may not necessarily be true. The majority of cases reported to date involved patients whose neurological deterioration was so acute and progressive that immediate surgical intervention was indi-

TABLE 1
Clinical summary of 14 cases of interhemispheric subdural hematoma

Case No.	Authors, Year	Site of Trauma	Skull Fracture	Loss of Consciousness	Falx Syndrome	Other Symptoms
1	Aring & Evans, 1940	occipital	no	yes	yes	seizures
2	Gannon, 1961	not given	yes	yes	yes	—
3	Wollschlaeger & Wollschlaeger, 1964	occipital	no	yes	yes	—
4	Clein & Bolton, 1969	parietal	no	yes	yes	—
5	Sibayan, <i>et al.</i> , 1970	not given	unknown	no	yes	headache
6	Ho, <i>et al.</i> , 1977	not given	unknown	no	yes	—
7	Ogsbury, <i>et al.</i> , 1978	not given	unknown	no	no	headache, seizures
8		occipital	no	no	yes	headache, seizures, vomiting
9	Glista, <i>et al.</i> , 1978	occipital	unknown	no	yes	seizures
10	Kasdon, <i>et al.</i> , 1979	occipital	unknown	no	yes	headache, vomiting
11	Fearnside, <i>et al.</i> , 1979	frontal	no	no	yes	—
12	Pozzati, <i>et al.</i> , 1982	not given	yes	no	no	headache, vomiting
13		not given	no	no	no	—
14	Fruin, <i>et al.</i> , 1984	occipital	no	no	yes	headache, vomiting

cated. Evacuating these hematomas at craniotomy without causing further trauma to the attached bridging veins can be difficult. It would be much easier to treat the hematoma after it has shifted out over the convexity. With this communication, there are now two reported cases of ISH in which the initial symptoms were less severe, and the patient's neurological status stabilized with conservative treatment.¹³ With this mode of treatment, the patient's ICP and neurological status should be closely monitored, and the patient should proceed to craniotomy only if neurological deterioration indicates surgical intervention.

References

1. Aring CD, Evans JP: Aberrant location of subdural hematoma. *Arch Neurol Psychiatry* **44**:1296-1306, 1940
2. Clein LJ, Bolton CF: Interhemispheric subdural haematoma: a case report. *J Neurol Neurosurg Psychiatry* **32**:389-392, 1969
3. Echlin FA, Sordillo SVR, Garvey TQ Jr: Acute, subacute, and chronic subdural hematoma. *JAMA* **161**:1345-1350, 1956
4. Fearnside MR, Hall K, Sengupta RP: Interhemispheric subdural haematoma following head injury. *Aust NZ J Surg* **49**:678-680, 1979
5. Gannon WE: Interhemispheric subdural hematoma. Case report. *J Neurosurg* **18**:829-830, 1961
6. Glista GG, Reichman OH, Brumlik J, et al: Interhemispheric subdural hematoma. *Surg Neurol* **10**:119-122, 1978
7. Goss CM: *Gray's Anatomy of the Human Body*, ed 29. Philadelphia: Lea & Febiger, 1973, pp 687-688
8. Hirakawa K, Hashizume K, Fuchinoue T, et al: Statistical analysis of chronic subdural hematoma in 309 adult cases. *Neurol Med Chir* **12**:71-83, 1972
9. Ho SU, Spehlmann R, Ho HT: CT scan in interhemispheric subdural hematoma. Clinical and pathological correlation. *Neurology* **27**:1097-1098, 1977.
10. Kasdon DL, Magruder MR, Stevens EA, et al: Bilateral interhemispheric subdural hematomas. *Neurosurgery* **5**:57-59, 1979
11. List CF: Interhemispheric subdural suppuration. *J Neurosurg* **7**:313-324, 1950
12. McKissock W, Richardson A, Bloom WH: Subdural haematoma. A review of 389 cases. *Lancet* **1**:1365-1369, 1960
13. Ogsbury JS, Schneck SA, Lehman RAW: Aspects of interhemispheric subdural haematoma, including the falx syndrome. *J Neurol Neurosurg Psychiatry* **41**:72-75, 1978
14. Pozzati E, Gaist G, Vinci A, et al: Traumatic interhemispheric subdural hematomas. *J Trauma* **22**:241-243, 1982
15. Rosenbluth PR, Arias B, Quartetti EV, et al: Current management of subdural hematoma. Analysis of 100 consecutive cases. *JAMA* **179**:759-762, 1962
16. Sibayan RQ, Gurdjian ES, Thomas LM: Interhemispheric chronic subdural hematoma. Report of a case. *Neurology* **20**:1215-1218, 1970
17. Wollschlaeger PB, Wollschlaeger G: The interhemispheric subdural or falx hematoma. *AJR* **92**:1252-1254, 1964

Manuscript received October 27, 1983.

Address reprint requests to: Alan H. Fruin, M.D., Division of Neurological Surgery, Creighton University School of Medicine, 601 North 30th Street, Omaha, Nebraska 68131.