

The Relevance of Secondary Epileptogenesis to the Treatment of Epilepsy: Kindling and the Mirror Focus

Eli S. Goldensohn

Department of Neurology, College of Physicians & Surgeons, Columbia University and Albert Einstein College of Medicine, New York, New York

Summary: Human beings with partial epilepsy and demonstrable cerebral lesions show, in addition to ipsilateral epileptiform EEG discharges, apparently independent epileptiform discharges from the opposite hemisphere. Patients with apparent unilateral focal onset of their partial seizures but without demonstrable lesions also frequently display what appear to be bilaterally independent EEG foci. When surgical treatment or medical prognosis is considered and there is no demonstrable lesion, the decision of which of the two apparent foci is primarily responsible for the seizures is often difficult.

Even with a known structural lesion the question arises whether, following its removal, the contralateral focus will persist and will be epileptogenic. Two related experimental phenomena bear directly on these questions—kindling and the mirror focus. This presentation looks critically at existing evidence and finds that it fails to support the idea that kindling and the mirror focus have roles in human epilepsy that currently should influence clinical decisions. **Key Words:** Epilepsy—Kindling—Electroencephalography.

People with partial epilepsy and demonstrable unilateral cerebral lesions often show, in addition to ipsilateral epileptiform electroencephalographic (EEG) discharges, apparently independent discharges from homotopic areas of the opposite hemisphere (Pope et al., 1946; Falconer and Kennedy, 1961). Patients without demonstrable lesions who have partial seizures also frequently display what appear to be independent spike foci from both hemispheres (Jasper et al., 1951). When surgical treatment is contemplated and no demonstrable lesion can be discovered, making the crucial decision as to which of the two independent electrical foci is responsible for the seizures is often difficult. After that decision has been made questions arise as to the persistence and epileptogenicity of the contralateral focus after the contemplated removal of the primary focus. Even with an identified unilateral structural lesion, the same questions remain as to whether, after removal of the lesion, the previously observed contralateral independent discharges will persist and be epileptogenic. A related consideration is whether the length of time that a contralat-

eral focus has been present is related to its persistence after the structural lesion has been removed. Yet another open question that impinges on both medical and surgical management is whether recurrent ipsilateral firing at a primary focus for months and years increases its own epileptogenic sensitivity and results in more frequent and severe seizures.

Two experimental phenomena—kindling and the mirror focus—bear directly on each of these clinical questions. At a symposium held in Vancouver in 1977, celebrating the founding of the Epilepsy Society of Canada, I reviewed the remarkable impact that recognition of the kindling phenomenon and subsequent research have had on understanding the mechanisms of epilepsy (Goldensohn, 1978). Kindling was observed first in rats by Goddard (1967; Goddard et al., 1969) and was pursued by him and his Canadian colleagues (Racine, 1978), including studies in primates by Dr. Wada (1976, 1981), who was host at the inaugural session. Kindling as a method for investigating the development of seizures has already added much to our knowledge of the basic mechanisms of epilepsy. Among its remarkable attributes is that the kindling model can produce chronic seizures without evidence of tissue damage (Goddard and Douglas,

Address correspondence and reprint requests to Dr. Goldensohn at Department of Neurology, Montefiore Hospital and Medical Center, 111 East 210 Street, Bronx, New York 10467.

1975). The mirror focus, a related phenomenon, was discussed in terms of human epilepsy by Pope et al. (1946) and later by Morrell (1959, 1960) in animals. Like kindling, the mirror focus is of physiologic importance and is potentially significant in clinical epilepsy. Mayersdorf and Schmidt (1982) recently reviewed the two phenomena in a book entitled *Secondary Epileptogenesis*.

I will present physiological data on kindling and the mirror focus that relate to the development and persistence of seizures in various species. The ultimate purpose of this contribution, however, is to critically evaluate existing evidence that supports or fails to support the idea that kindling and the mirror focus play roles in human epilepsy that currently should influence clinical decisions.

The term mirror focus is used to describe a new, apparently independent epileptogenic focus in an area of the brain contralateral and homotopic to an original focus. It presumes that the secondary focus has been induced by and has become completely independent of the original epileptogenic focus (Morrell, 1969). The term kindling is used to describe the progressive enhancement of electrical and behavioral responses to short duration, initially subthreshold stimuli that are applied at intervals of days or hours to a discrete area of gray matter of the brain (Goddard et al., 1969). Electrical afterdischarges that outlast the stimuli are noted first. They increase in intensity over time, and in some species, repetition eventually leads to complete generalized convulsions. The enhanced responses to subthreshold stimuli may persist for many months without reinforcement. A wide variety of stimulus frequencies can result in kindling but a minimum interval between successive trains of stimuli is critical. The enhanced responses to the subliminal stimuli can transfer from the original area to the homologous area of the opposite hemisphere. Kindling has resulted in seizures in all species tested, including some primates.

The question of the clinical relevance of kindling and the mirror focus will be explored by examining human cases. Such cases must show electrical evidence of repetitive spontaneous electrical discharging at intervals over a long time so that the processes of kindling and the mirror focus might be expected to develop. In each case we can ask: (1) what findings suggest that secondary epileptogenesis has occurred? (2) do they persist? (3) did kindling occur? and (4) was a mirror focus established? The cases reported below and other clinical data that appear pertinent are considered in an effort to evaluate the role of secondary epileptogenesis in human epilepsy.

First, let us look at 3 cases that presented practical clinical questions of management. The 3 patients together had a total of 56 years of uncontrolled seizures and each showed frequent, independent epileptiform discharges from a distant area as well as from the area of a structural brain lesion. In order to look for contralateral independent persistence, the unilateral primary focus was removed and verified histologically in each case.

Case I

D.G., aged 39 years, was seen by me for the first time in January 1980. He related that his seizures began in 1961, at the age of 20 years, several months after an automobile accident that caused a severe head injury and 3 days of unconsciousness. In the history given by his sister, however, his seizures began as short periods of unresponsiveness 3 years before the accident.

The attacks were characterized by feelings of strangeness followed by staring and automatisms. In spite of adequate blood levels of carbamazepine, primidone, and phenytoin among other anticonvulsants, the attacks were intractable and he was referred as a candidate for surgical treatment. Neurological examination was unremarkable. An EEG in February 1980 showed he had a predominantly left medial and lateral anterior temporal spike focus (Fig. 1A). A second EEG on January 20, 1981, showed independent spiking of about equal degree from both the right and left medial temporal areas with more medial temporal slowing on the left (Fig. 1B). A computed tomography (CT) scan of the head in 1978 had been normal. A second CT scan with and without contrast medium and a cerebral arteriogram on January 30, 1981, were normal. Closed circuit TV recording of seizures with EEG indicated a left temporal origin for the attacks. In summary, this patient had had seizures for 22 years with independent epileptiform spiking coming from either temporal lobe. On February 23, 1981, a left temporal lobectomy was performed. The findings and follow-up on this case are given later in this report.

Case II

R.B., aged 47, had onset of recurrent seizures in 1960 at age 23 following the birth of her first child. Four years later, in the third month of her second pregnancy, she developed a progressively severe headache. Examination revealed bilateral papilledema and angiography showed a right frontal mass. A right frontal intracerebral hematoma was removed. The specimen contained a vascular anomaly with closely packed, medium-sized vas-

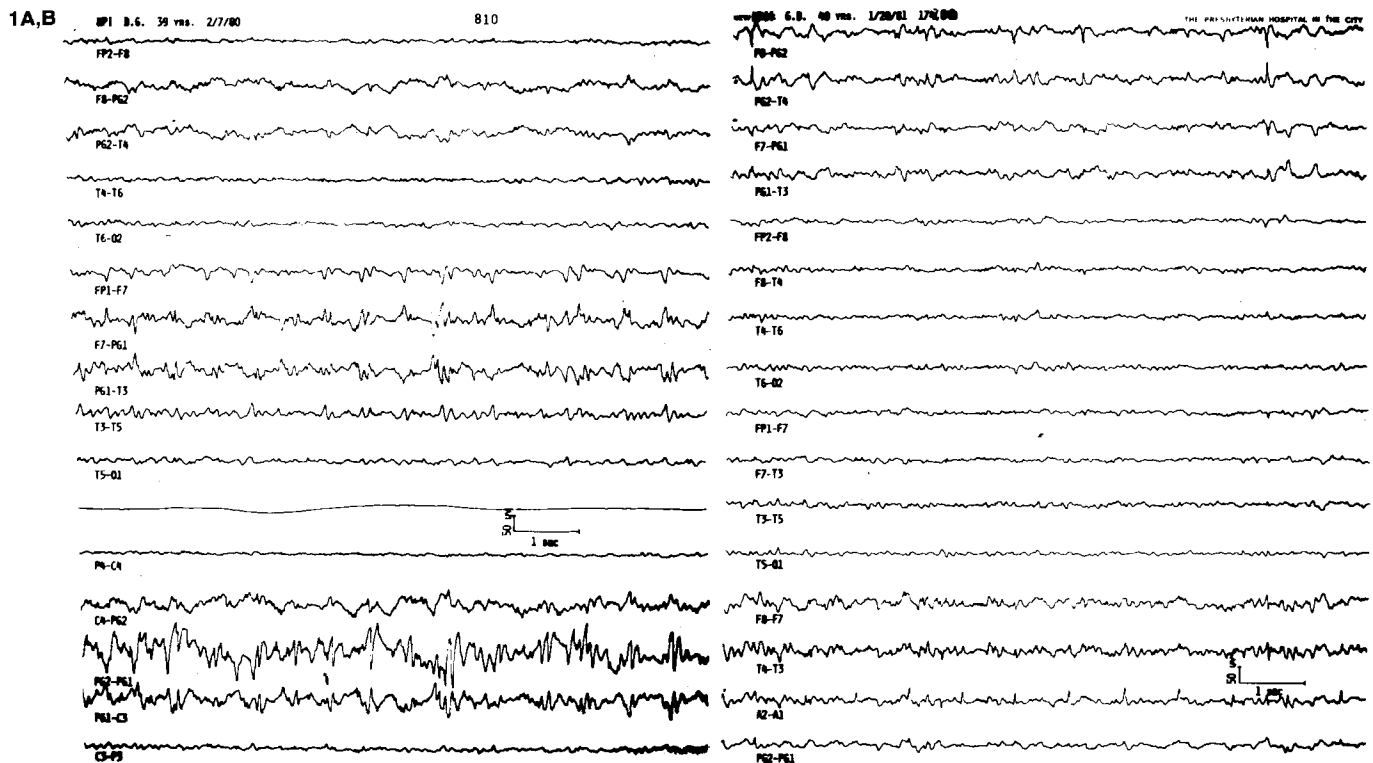


FIG. 1. **A:** D.G., 2/7/80. Repetitive firing at left anterior temporal (F 7) and mesial temporal (PG 1) electrodes best seen in channels 6, 7, 8, and 14 and 15. **B:** D.G., 1/20/81 (11 months after record in A). The spiking is now mainly from the right mesial temporal area (electrode PG 2 in channels 1 or 2) and less so at the left mesial temporal electrode (PG 1 in channels 3 and 4). However, there is more slow wave activity on the left. Deflections in channel 15 are EKG.

cular channels devoid of smooth muscle, and a surrounding extensive cellular degeneration. Seizures persisted about five times daily and seldom did more than 2 days elapse without an attack. They began with a rising abdominal sensation, and at times the patient screamed or called out before performing complex activities such as partial undressing. She had no memory of the events. There was no evident neurological deficit. In 1975, at age 38, 15 years after the seizures began and 11 years after removal of the hematoma and vascular malformation, she was considered for surgical treatment. Arteriography showed an area of left frontal hypovascularity. The EEG showed a continuous left frontal slow wave focus and abundant intermittent epileptiform spikes occurring independently from both the left frontotemporal and right medial temporal areas (Fig. 2A,B). In summary, this is a case of 15 years of frequent seizures with bilateral independent epileptiform spike foci. The patient was operated on in 1975; an 8-year follow-up is given below.

Case III

R.H., aged 39 years, had the onset of seizures at age 20. For several years they occurred only as lim-

ited episodes characterized by a feeling of warmth in the upper part of the body, followed by a feeling of strangeness in the patient's surroundings. At the age of 25, infrequent overt seizures began that were characterized by rocking, loss of contact, and head turning to the left. On several occasions these proceeded to become generalized major motor seizures. For the past 12 years, the episodes occurred four to five times weekly and often included darting of the eyes from side to side. Each attack lasted about a minute and was followed by a period of confusion for several minutes during which he felt he had experienced a dream. At the Neurological Institute of New York in 1970 a skull X-ray film, EEG, brain scan, and right carotid angiogram were normal. In December 1982, a CT scan with and without contrast medium and a 4-vessel cerebral angiogram were normal. In 1982, the routine sleep and awake EEG records showed mainly a right temporal spike focus but also an independent left temporal spike focus (Fig. 3A,B). Closed circuit TV gave evidence of a right lateral and medial temporal origin for the seizures. In summary, this man had a 19-year history of recurrent attacks with 12 years of frequent, recurrent seizures occurring four to five times weekly, with apparently bilateral independent

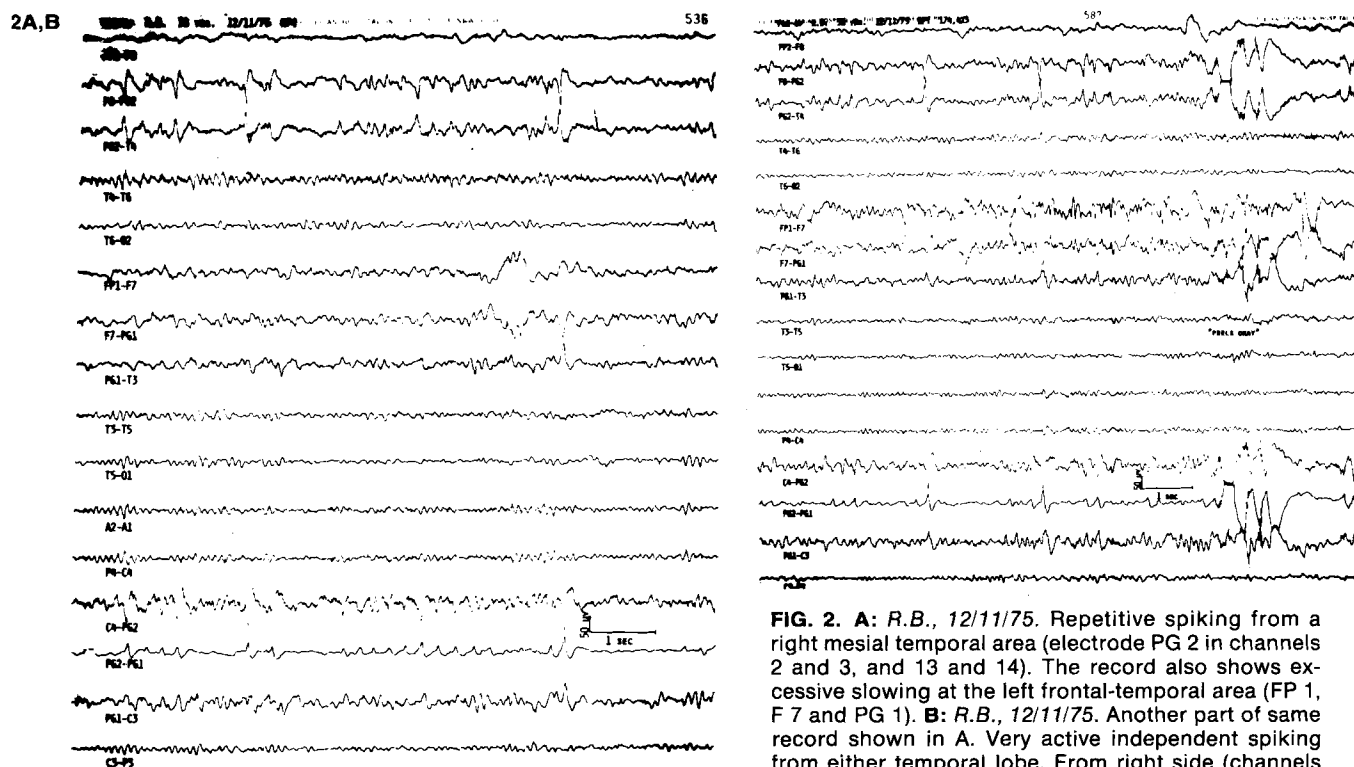


FIG. 2. A: R.B., 12/11/75. Repetitive spiking from a right mesial temporal area (electrode PG 2 in channels 2 and 3, and 13 and 14). The record also shows excessive slowing at the left frontal-temporal area (FP 1, F 7 and PG 1). **B:** R.B., 12/11/75. Another part of same record shown in A. Very active independent spiking from either temporal lobe. From right side (channels 2 and 3, PG 2) and from left side (channels 6, 7, and 8). Excessive slowing in the left frontal area persists.

foci. He was operated on in December 1982, and I will give a 1-year follow-up on this case below.

In terms of duration of illness, bilateral electrical manifestations, and frequency of attacks, each of these cases suggests the presence of a mirror focus and warrants consideration of the possibility that kindling had occurred.

Experimental seizures in kindled animals are stereotyped and easily reproduced, and no histological evidence of brain tissue injury is found (Goddard and Douglas, 1975). Enhanced responses to ordinarily subliminal stimuli, although diminished, persist over intervals of 12 months or more without intervening stimulations. Stimulus repetition rate and duration are not crucial for kindling to occur, but a minimal interval between successive stimulations is critical (Racine, 1978). Kindling in one amygdala facilitates subsequent kindling of the contralateral amygdala and septal regions. Increased severity of seizures correlates with increases in the amplitude of afterdischarges, particularly at the homotopic contralateral sites. Of particular interest is the fact that after full kindling has been established, continuation of stimuli over long periods can lead to spontaneous interictal discharges and spontaneous seizures (Wada et al., 1974, 1976; Wada and Osawa, 1976). Most studies of the kindling phenom-

enon have used stimulation of the amygdala. Other areas of the brain are much less responsive, but with repeated electrical stimulation over longer periods, kindling can result (Wada et al., 1976; Burnham, 1978). Most primates are resistant to kindling (Racine, 1978).

In rats, intraperitoneal injections of ordinarily ineffective doses of pentylenetetrazol at 8-h intervals cause the gradual development of increasingly severe convulsive movements (Fig. 4) (Pinel and Van Oot, 1976). The observation that the periodic administration of a chemical agent can cause kindling in the same manner as electrical stimulation suggests that potentially convulsive drugs that are administered for clinical purposes may be capable of inducing lasting increases in patients' susceptibility to convulsions. Such studies also make it clear that the electrical kindling originally described by Goddard is but one example of a more generalized phenomenon that follows the application of many local and generalized agents.

Electrical kindling intensifies and lowers the threshold to pentylenetetrazol seizures (Fig. 5) (Cain, 1980). These findings indicate that kindling produces a general increase in responsiveness to other convulsive agents, a process referred to by Cain as "cross-talk" (Cain, 1981). Alcohol with-

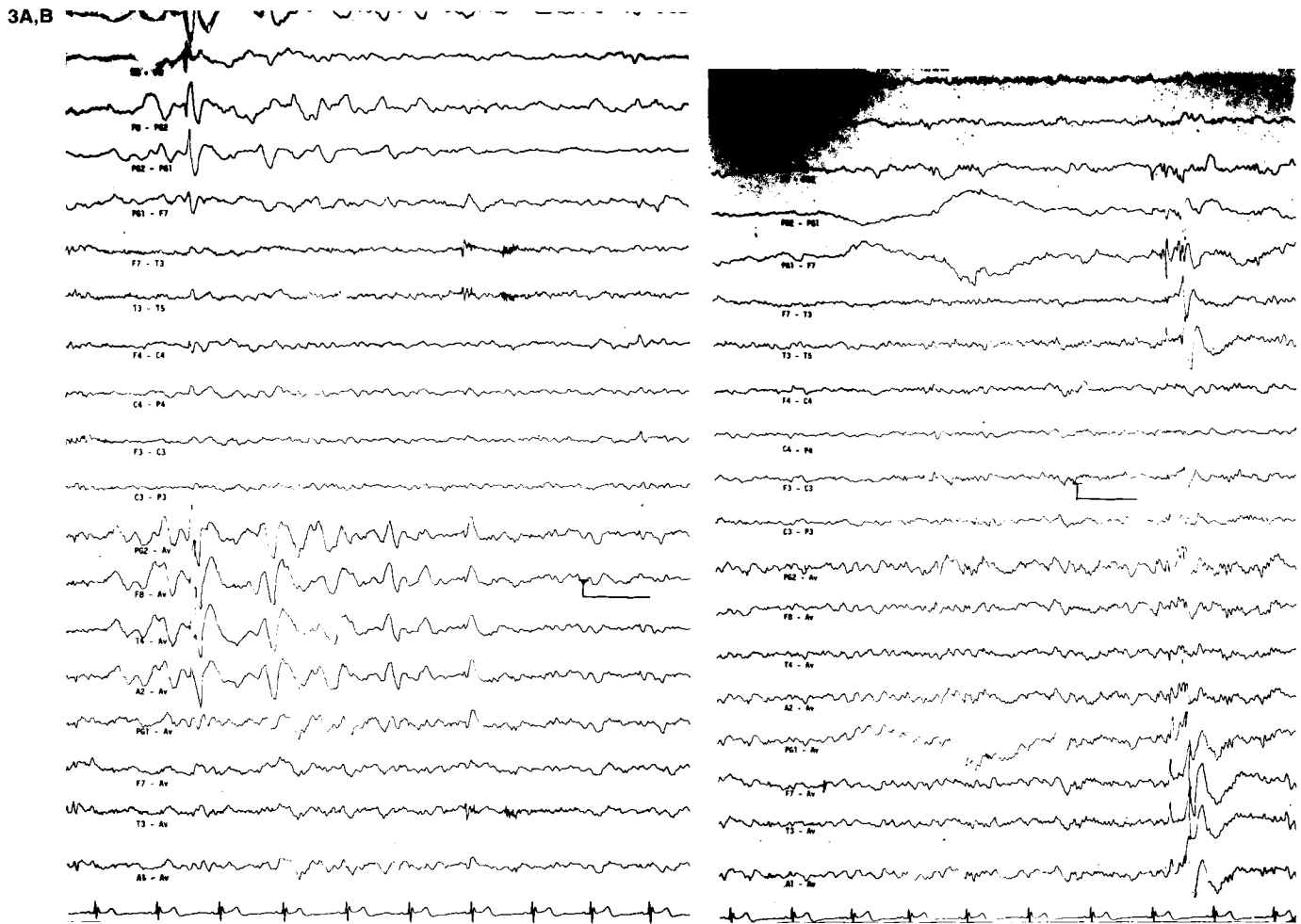


FIG. 3. A: *R.H.*, 12/8/82. Repetitive focal temporal spikes and sharp waves at right mesial and inferior temporal electrodes (PG 2 and A 2) and at anterior and mid-temporal electrodes (F 8 and T 4). Calibration signal 50 microvolts and one second. **B:** *R.H.*, 12/8/82 (same date as A). Spiking at left mesial and inferior temporal areas (PG 1 and A 1) and at anterior and mid-temporal areas (F 7 and T 3). Calibration signal 50 μ V and 1 s.

drawal seizures are also intensified after kindling by either electrical stimulation or injections of pentylentetrazol. The degree of severity is rated on a scale of 5: facial movements, clonus and head-nodding, focal clonus, drooling, and falling. Figure 6 shows the intensification of alcohol withdrawal motor seizures following amygdaloid kindling in rats who received subthreshold electrical stimulation three times daily, 5 days a week for 3 weeks. To create withdrawal symptoms, both kindled and control animals received ethanol by intubation at 8-h intervals for 2 weeks. Hyperactivity, clonus, and muscular jerks were each increased over 300% in the kindled animals as compared with the controls with unmodified alcohol withdrawal symptoms.

There are three types of excessive electrical responses found in kindled tissues: one is the enhancement of evoked responses or long-term po-

tentiation (Racine et al., 1975), another is the occurrence of interictal spikes generated by the neuronal paroxysmal depolarization shifts (PDS), which trigger bursts of action potentials, and the third is afterdischarge (Racine et al., 1981). It appears that each of these relatively separate phenomena are involved in the production of kindling. The enhancement (long-term potentiation) of synaptic responses occurs as a result of driving neuronal pathways to a high level of activity. The resulting long-lasting increases in the amplitude of evoked responses (Fig. 7) may be related to increases in either the number or the sensitivity of receptor sites in postsynaptic membranes. The interictal spike or PDS may be related to intrinsic characteristics of the membrane itself rather than solely to increased synaptic drive (Schwartzkroin and Wyler, 1980). The development of afterdis-

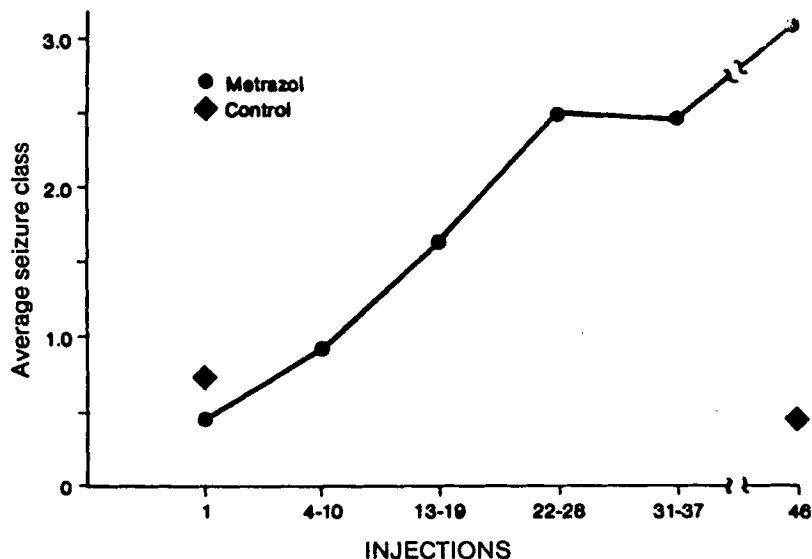


FIG. 4. The development of increasingly severe convulsive movements following the administration of pentylenetetrazol in low doses at 3 day intervals. By the 46th injection, facial movements (1 on ordinate), head nodding (2 on ordinate), and four limb clonus (3 on ordinate) developed regularly. (From Pinel and Van Oot, 1976.)

charge is essential for kindling, and its mechanism is also not fully understood (Cain, 1981). Anti-convulsants that are effective against motor seizures affect afterdischarge and interictal spikes in different manners (Fig. 8).

No structural or ultrastructural changes have yet been found in association with kindling (Goddard and Douglas, 1975), although some suggestive changes in the size of synaptic terminals have been seen (Morrell et al., 1975). Several possibilities could explain the occurrence of increased excitability without clearly detectable anatomical changes. These include increased release of transmitter substances to a given stimulus, increased sensitivity of postsynaptic membrane to a given quantity of transmitter, decreased pre- or postsyn-

aptic inhibition, and an increased number of pre-synaptic release sites. An approach to such molecular changes at the plasma membrane has shown that although kindling produces no significant change in cholinergic receptor binding at either the homotopic or opposite amygdala, both amygdala show reductions in norepinephrine receptor binding (Corcoran, 1981). The decrease in β -adrenergic binding sites implies that, in part, kindling is caused by a reduction in neuronal inhibition at both the stimulated and opposite amygdala. This evidence, combined with the finding of no change in muscarinic cholinergic receptor sites, suggests that reduction in inhibition plays a larger role in the kindling process than direct enhancement of excitability. This idea also fits with the finding of depletion of

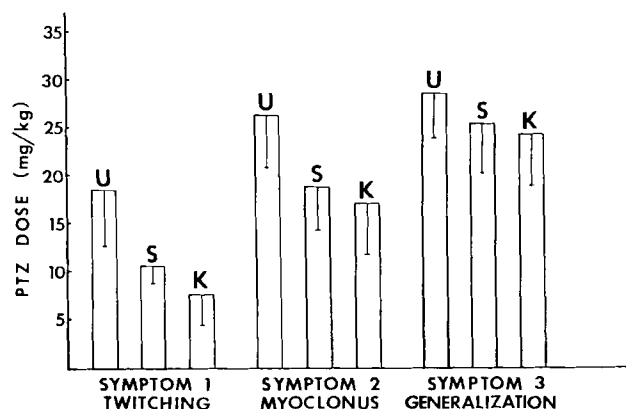


FIG. 5. The mean dose of PTZ (mg/kg) necessary to evoke each convulsive symptom in the three groups. The standard deviation is indicated on each bar. U, Unstimulated group; n = 7; S, stimulated group, n = 10; K, kindled group, n = 29. (From Cain, 1980.)

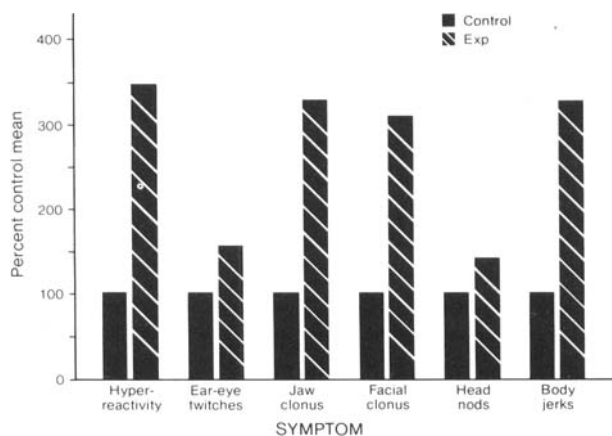


FIG. 6. Intensification of alcohol withdrawal motor seizures following a series of amygdaloid electrical stimulations in rats. Hyperactivity, clonus and muscular jerks have each been increased by over 300% in the kindled animals as compared to those with unmodified alcohol withdrawal seizures. (From Pinel and Van Oot, 1976.)

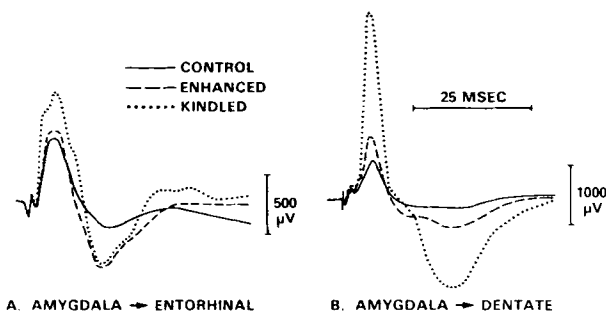


FIG. 7. The traces show the changes that develop in evoked potentials as the result of enhancement or kindling. Electrical pulses were applied to the amygdala and responses recorded in the entorhinal cortex in (A) and dentate gyrus (B). The kindled responses were measured 48 hours after completion of amygdala kindling. (From Racine et al., 1981.)

catecholamines (including norepinephrine) in the hippocampus of kindled brain.

The kindling phenomenon as a whole may have a common molecular basis. In the search for such a basis, it has been found that cyclohexamide, which inhibits protein synthesis, reduces the duration of afterdischarge and impairs the development of kindling through blocking afterdischarge in the frog (Morrell et al., 1975). Cyclohexamide, which is also a direct anticonvulsant, was found ineffective when applied during the intervals when the kindling process is developing and consolidating, suggesting an indirect effect (Ogata, 1977). Another protein synthesis inhibitor, anisomycin, arrests seizure development in mice but does not prevent the occurrence of afterdischarge (Cain, 1981). Anisomycin prevents increases in the duration and complexity of afterdischarges that ordinarily occur in the untreated kindled animal. After seizures are fully developed, anisomycin has no effect on the kindled seizures. It appears, therefore, that ongoing protein synthesis is necessary for the development of kindling, but the intermediate molecular processes involved in kindling are only now beginning to be clarified.

Let us now look at experimental data related to the mirror focus. There is no question that some experimental animals show apparently independent epileptiform EEG spikes in areas homologous and contralateral to epileptogenic foci. However, Morrell (1978, 1979) and his co-workers, and others (Wilson et al., 1977), believe that this contralateral EEG activity represents a new zone of epileptogenic tissue capable of producing seizures independent of the primary epileptogenic focus. Experimental evidence supporting this hypothesis is not strong. Practically all the corroborative data are EEG and electrocorticographic evidence showing

that paroxysmal activities in the two homotopic areas do not always occur synchronously or in obvious relationship. One study of cellular activity (Wilder and Morrell, 1967) reported epileptogenic characteristics at the mirror focus of bullfrogs but in cat preparations epileptiform activity projected into contralateral homotopic areas did not show typical cellular epileptogenic features (Ajmone-Marsan, 1963). Nevertheless, EEG evidence of independent, contralateral, focal epileptiform activity is seen experimentally in many species. The relative length of time needed for the development of contralateral independent discharges increases logarithmically as the phylogenetic scale is mounted. Wilder et al. (1968) compared the times it took to develop EEG mirror foci among different species. In amphibia it occurred in hours and in rhesus monkeys it took up to several years (Fig. 9). The evidence for contralateral independent foci in rhesus monkeys is, however, not conclusive. Harris and Lockard (1981), using rhesus monkeys, showed decisively that total removal of a primary epileptogenic zone after years of recurrent seizures invariably prevented further seizures and the development of contralateral independent epileptiform activity (Figs. 10 and 11). Also, Lowrie and Ettlinger (1980), using 29 monkeys, were unable to replicate in any of the animals their earlier reported experience that secondary independent foci develop. Finally, there is no convincing evidence of

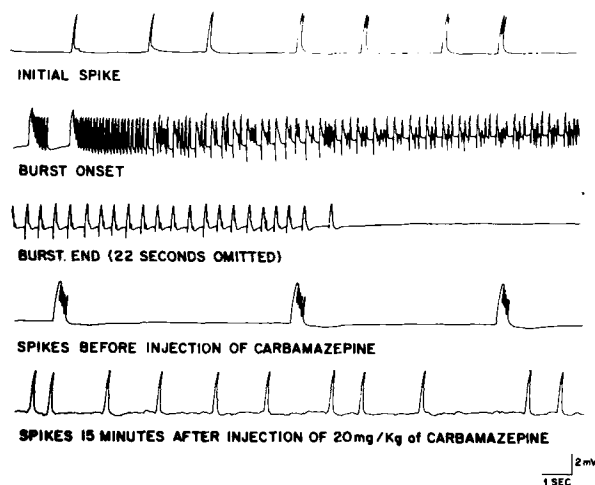


FIG. 8. The first line shows baseline frequency of interictal spiking in epileptogenic focus produced by penicillin. The second line shows a period of afterdischarge. The third line shows the end of the afterdischarge burst. The fourth line shows a decrease in interictal spike frequency as the focus becomes stronger shortly before the injection of an anticonvulsant. The last line shows the increase of interictal spike frequency which occurs following the injection of the anticonvulsant in therapeutic amounts. The same dose promptly stops afterdischarge and prevents recurrence for hours.

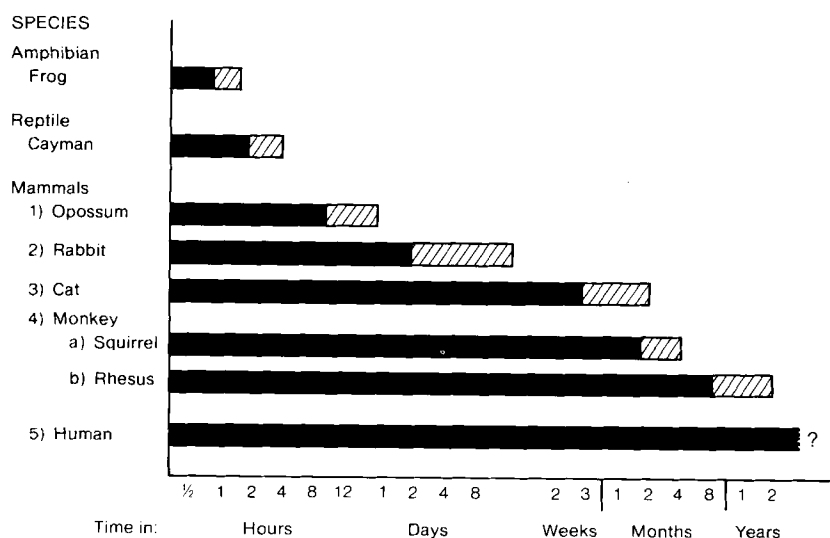


FIG. 9. Time table for secondary epileptogenesis. Approximate times required for genesis of independent secondary epileptic foci in certain vertebrates. (From Wilder et al., 1968.)

actual seizures beginning spontaneously from a mirror focus after the primary focus was removed.

The significance of kindling and of the mirror focus (secondary epileptogenesis) in man will now be examined further in terms of the postoperative findings in the 3 patients described earlier, who pre-operatively had bilateral, apparently independent foci.

Case I follow-up

On the basis of 20 years of intractable seizures and localization by clinical and EEG evidence, D.G. was subjected to a left temporal lobectomy on February 23, 1981. The corticogram showed high voltage spikes repeating about once per second maximal at the temporal tip. Slowing was also seen in that area (Fig. 12A). The left anterior temporal lobe was removed in sections. At sectioning there was a gray mass 1.2 cm in its greatest dimension. The white matter and cerebral cortex were infiltrated and partly replaced by a moderately cellular neoplasm that extended into the leptomeninges. The neoplasm did not appear to extend into the deep margins of the resection. Diagnosis was glioma with features of astrocytoma and oligodendroglioma in white matter, cerebral cortex, and leptomeninges. The patient is on reduced medication. The most recent EEG showed mild background slowing and asymmetries related to the skull defect (Fig. 12B). There have been no seizures in the 3 years since operation.

Case II follow-up

On the basis of 24 years of intractable seizures and clinical, EEG, and angiographic localization, a left frontal craniotomy was performed. At operation

on the left frontal lobe a large densely gliotic mass was reviewed that still showed evidence of a vascular anomaly. Following the procedure a few mild episodes occurred the second week; since that time R.B. has been seizure-free for the past 8 years. The last EEG, done in January 1983 (Fig. 13), showed intermittent motor slowing of the interior frontal area with a few slightly suggestive spikes in the left frontal area and nothing abnormal in the opposite hemisphere during the past 8 years.

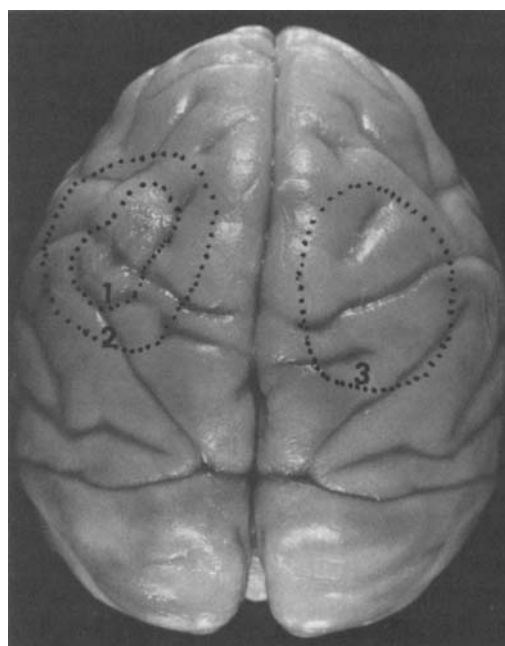


FIG. 10. This photograph shows the superior surface of monkey brain with the excisions outlined in dotted lines. 1, first; 2 second; and 3, third resections of cortex. Alumina granuloma is in first resected tissue. (From Harris and Lockard, 1981.)

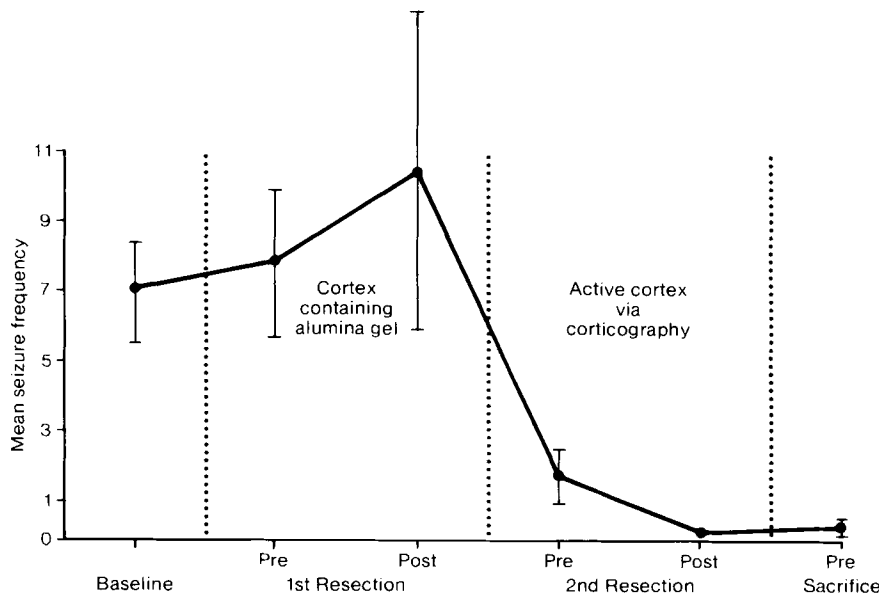


FIG. 11. Mean seizure frequency (n = 15) and associated standard deviation before and after each phase of the study (baseline, resections 1 and 2, and presacrifice). The means are daily seizure averages for each week. The first resection removed tissue containing alumina and the second resection removed tissue judged epileptic by ECoG. (From Harris and Lockard, 1981.)

Case III follow-up

On the basis of 19 years of intractable seizures and localization by clinical and simultaneous EEG localization, a right anterior temporal lobectomy was performed on R.H. Corticography showed anterior temporal spikes and focal irregular slowing

(Fig. 14A). A lesion was found that consisted of an oval area of dark red-black hemorrhaging, measuring 7 × 5 × 6 mm, extending from the leptomeninges into the underlying cortex as far as the junction with the white matter and surrounded by a narrow band of orange colored staining. This le-

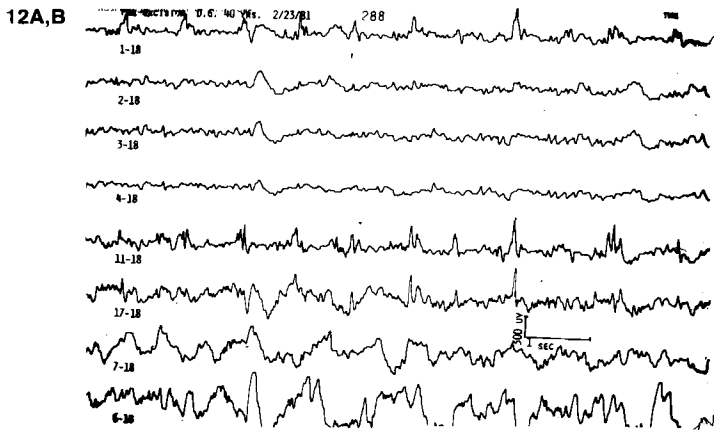
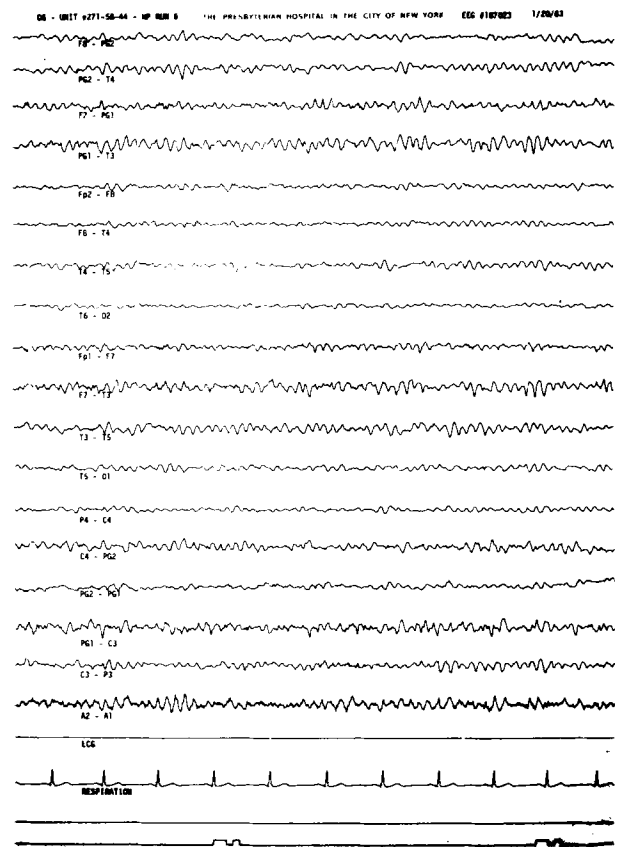


FIG. 12. A: D.G., 2/23/81. Electrococtogram. Electrodes 1, 2, 3, and 4 are from before backwards on the inferior temporal gyrus and electrodes 11, 17, 7, and 8 from before backwards on the middle temporal gyrus. Electrode 18 is a reference on the bone. Spikes are seen at electrodes 1 and 11 near the tip of the temporal lobe. Slow waves from the middle temporal gyrus are seen mainly at electrodes 6 and 7. **B:** D.G., 1/20/83. Two years after temporal lobectomy. The record is free of spikes. There is a voltage asymmetry with higher voltage activity from the left hemisphere (channel 4 compared to channel 1 for example), which is the result of the skull defect.



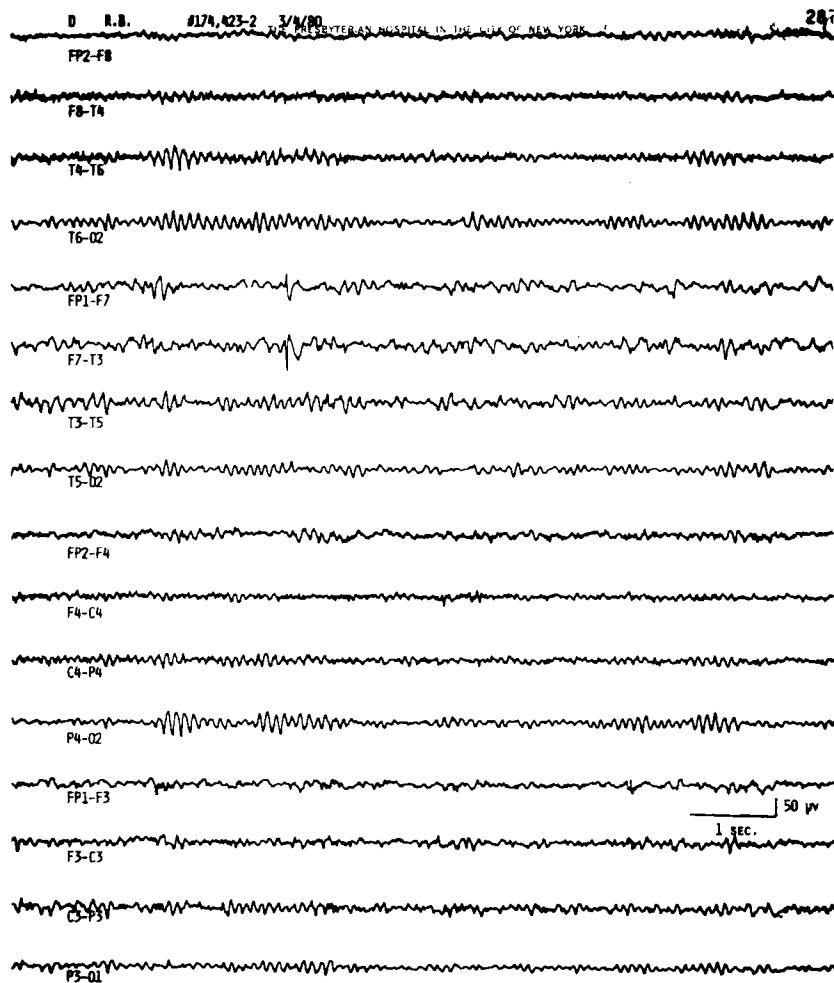


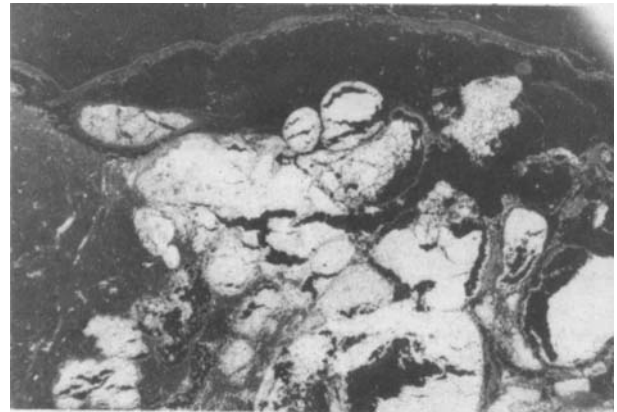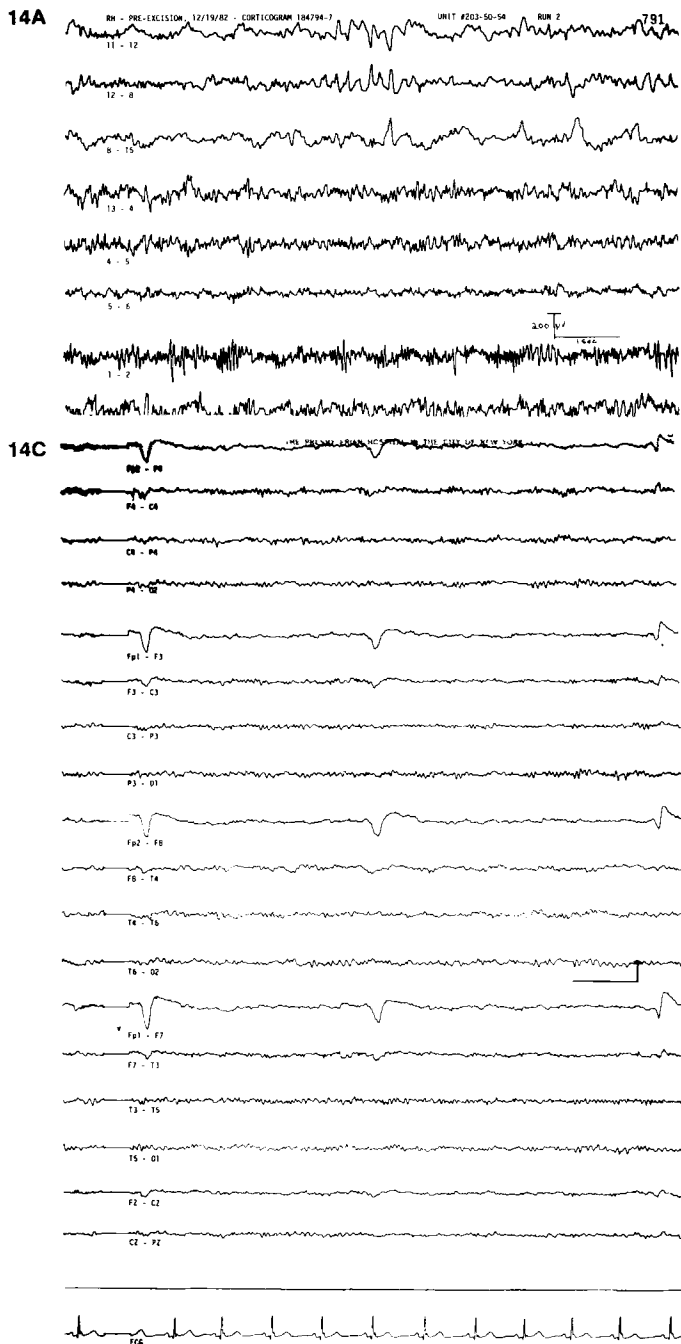
FIG. 13. R.B., 3/8/80. Five years post-operative. Residual but reduced slowing is present in the left frontal area (electrodes FP 1 and F 7). A rare single positive spike is seen at electrode F 7 with a very restricted field.

sion was an arteriovenous malformation, mainly intracortical in the temporal neocortex (Fig. 14B), and showed evidence of having bled in the past, with severe degeneration of nerve cells and astroglyosis confined to the immediate vicinity of the lesion. In the past 10 months there has been complete control except for some darting eye movements in the first few days after operation. There is no further paroxysmal activity on the EEG (Fig. 14C).

The existence of mirror foci in lower forms has already been discussed in some detail, with the conclusion that although the existence of apparently *independent epileptiform activity* can be observed, no convincing evidence of *epileptogenic* activity causing seizures has been forthcoming. The existence of "mirror foci" in some patients with temporal lobe epilepsy has been inferred by showing a longer duration of illness in patients with bilateral as compared to unilateral spike foci (Hughes and Schlagenhauff, 1961; Gupta et al., 1973). Such data are open to the alternative interpretation that pa-

tients with bilateral epileptogenic lesions have more severe forms of epilepsy, which begin earlier than those in patients with unilateral lesions. This is supported by studies of Van Buren et al. (1975), who found no evidence of progressive changes in epileptiform activity in human cases of persistent seizures and active foci after 5-year periods of observation.

Cases of human secondary epileptogenic lesions have been described but are few and not well documented (Wilson et al., 1977; Morrell, 1978, 1979; Torres and Jacome, 1982). Pope et al. (1946) stated that EEG "mirror foci" are frequently observed in association with unilateral foci but that they regularly disappear after the primary epileptogenic focus is removed. Torres and French (1973) and Wilson et al. (1977) each reported single cases of a degree of persistence of independent epileptiform contralateral activity following corpus callosotomy, which soon disappeared. In other studies (Falconer and Cavanaugh, 1959; Falconer and Kennedy, 1961; Falconer et al., 1962), contralateral spiking disappeared promptly after removal of the primary foci



14B

FIG. 14. A: *R.H.*, 12/19/82. Electroencephalogram shows multiple spikes near temporal tip (Electrode 12). Slow waves involving electrodes 11, 12, and 8 are from the inferior temporal gyrus. **B:** *R.H.* Section of arteriovenous malformation found in inferior temporal cortex extending into the leptomeninges. **C:** *R.H.*, 1/23/83 (22 days post temporal lobectomy on right). Record is free of paroxysmal activity but shows slight residual slowing and increased amplitude of background on the right side. The latter is related to the skull defect.

and did not reappear during several years of follow-up.

Torres and Jacome (1982) state that they were unable to find in the literature concerned with localized resections for epilepsy any case that would be strongly supportive of the concept that secondary epileptogenesis occurs in humans. To my knowledge, there is no documentation of persistent clinical or electrographic seizures, either in lower primates or man, that arise from mirror foci after the primary focus has been removed.

At this time, 15 years after kindling was first described, it seems important to put that phenomenon in some perspective as it relates to human epilepsy. We do not know if kindling can even occur in the human, and if it does occur, what the trigger parameters might be that correspond to the kindling stimulus in experimental animals. As with the mirror focus, we know that evolutionary advancement is associated with progressively greater difficulty in producing kindling (Wilder et al., 1968). Also, spontaneous seizures unrelated to a triggering stimulus

are rare even in fully kindled animals and are not observed in primates except in those with genetic convulsive tendencies (Wada and Osawa, 1976; Wada et al., 1976). Further, spontaneous interictal discharges are not universally present and are usually related to the kindling process itself rather than being present at long intervals after kindling is complete (Fitz and McNamara, 1979). While it is clear from experimental studies that interictal discharges are related to seizure susceptibility, their long-term or permanent effects on the process of epileptogenesis are not established. One of the most active EEGs in terms of frequency of focal interictal spiking is recorded in children with benign focal epilepsy of childhood ("sylvian seizures"). Yet it is characteristic of these children to be normal between attacks, for their seizures to be easily controlled, and for both the clinical and EEG manifestations to disappear in adolescence. Indeed, in any patient with epilepsy, there is at best only a rough correlation between the amount of interictal epileptiform activity on the EEG at any point in time and the frequency of clinical attacks. Further, cognitive deficits generally (O'Leary et al., 1981) and the behavioral syndrome of temporal lobe epilepsy in particular (Bear and Fedio, 1977) relate to the duration of illness but not to seizure frequency. This suggests that seizures and interictal psychological disturbances (if any) are only indirectly related.

In summary, I believe that present evidence is against the existence of a mirror focus capable of producing chronic seizures in man. Clinical evidence is lacking and contralateral EEG changes are not persistent. For these reasons, the concept of the mirror focus should have no place in affecting decisions in the treatment of epilepsy.

Kindling remains an intriguing phenomenon and a very useful experimental model for studying epilepsy and central nervous system plasticity. Observations in man, however, do not support a place for kindling that currently should influence the making of decisions for the diagnosis and management of patients with epilepsy.

REFERENCES

- Ajmone-Marsan C. Unitary analysis of "projected" epileptiform discharges. *Electroencephalogr Clin Neurophysiol* 1963; 15:197-208.
- Bear DM, Fedio P. Quantitative analysis of interictal behavior in temporal lobe epilepsy. *Arch Neurol* 1977;34:454-67.
- Burnham WM. Cortical and limbic kindling: similarities and differences. In: Livingston KE, Hornykiewicz, D, eds. *The continuing evolution of the limbic system concept*. New York: Plenum Press, 1978:507-19.
- Cain DP. Effects of kindling or brain stimulation on pentylene-tetrazol-induced convulsion susceptibility. *Epilepsia* 1980;21:243-9.
- Cain DP. Recent studies and new directions. In: Wada JA, ed. *Kindling 2*. New York: Raven Press, 1981.
- Corcoran ME. Catcholamines and kindling. In: Wada JA, ed. *Kindling 2*. New York: Raven Press, 1981.
- Falconer MA, Cavanaugh JB. Clinico-pathological considerations of temporal lobe epilepsy due to small focal lesions. *Brain* 1959;82:483-504.
- Falconer MA, Kennedy WA. Epilepsy due to small focal temporal lesions bilateral independent spike-discharging foci. *J Neurol Neurosurg Psychiatry* 1961;24:205-12.
- Falconer MA, Driver MV, Serefetinides EA. Temporal lobe epilepsy due to distant lesions: two cases relieved by operation. *Brain* 1962;85:521-34.
- Fitz JG, McNamara JO. Spontaneous interictal spiking in the awake kindled rat. *Electroencephalogr Clin Neurophysiol* 1979;47:592-96.
- Goddard GV. Development of epileptic seizures through brain stimulation at low intensity. *Nature* 1967;214:1020-1.
- Goddard GV, Douglas RM. Does the engram of kindling model the engram of normal long term daily memory? *Can J Neurol Sci* 1975;2:385-94.
- Goddard GV, McIntyre DC, Leech CK. A permanent change in brain function resulting from daily electrical stimulation. *Exp Neurol* 1969;25:294-330.
- Goldensohn ES. Epileptogenesis: recent neurobiological advances. In: Wada J, ed. *Modern perspectives in epilepsy*. Montreal: Eden Press, 1978;172-84.
- Gupta PC, Dharampaul S, Pathak SN, Singh B. Secondary epileptogenic EEG focus in temporal lobe epilepsy. *Epilepsia* 1973;14:423-26.
- Harris AB, Lockard JS. Absence of seizures or mirror foci in experimental epilepsy after excision of alumina and astroglitic star. *Epilepsia* 1981;22:107-22.
- Hughes JR, Schlagenhauff RE. Electro-clinical correlation in temporal lobe epilepsy with emphasis in inter-areal analysis of the temporal lobe. *Electroencephalogr Clin Neurophysiol* 1961;13:333-9.
- Jasper H, Pertuiset B, Flanigin H. EEG and cortical electrograms in relation to surgical therapy of patients with temporal lobe seizures. *Arch Neurol Psychiatry* 1951;65:272-90.
- Lowrie MB, Ettlinger G. The development of independent secondary ("mirror") discharge in the monkey: failure to replicate earlier findings. *Epilepsia* 1980;21:25-30.
- Mayersdorf A, Schmidt RP. *Secondary epileptogenesis*. New York: Raven Press, 1982.
- Morrell F. Experimental epilepsy in animals. *Arch Neurol* 1959;1:141-7.
- Morrell F. Secondary epileptogenic lesions. *Epilepsia* 1960;1:538-60.
- Morrell F. Physiology and histochemistry of the mirror focus. In: Jasper HH, Ward Jr AA, Pope A, eds. *Basic mechanisms of the epilepsies*. Boston: Little Brown, 1969;357-70.
- Morrell F. Secondary epileptogenic lesions in man: limits of the evidence. Presidential address, American Electroencephalographic Society, September 1978.
- Morrell F. Human secondary epileptogenic lesions [Abstract]. *Neurology* 1979;29:558.
- Morrell F, Tsuru N, Hoepfner TJ, Morgan D, Harrison WH. Secondary epileptogenesis in frog forebrain: effect of inhibition of protein synthesis. *Can J Neurol Sci* 1975;2:407-16.
- Ogata N. Effects of cyclohexamide on experimental epilepsy produced by daily amygdaloid stimulation in rabbits. *Epilepsia* 1977;18:101-8.
- O'Leary DS, Seidenberg M, Berent S, Boll TJ. Effects of age of onset of tonic-clonic seizures on neuropsychological performance in childhood. *Epilepsia* 1981;22:197-204.
- Pinel JPJ, Van Oot PH. Generality of the kindling phenomenon. In: Wada JA, ed. *Kindling*. New York: Raven Press, 1976;155-71.
- Pope A, Morris AA, Jasper H, Elliott KAC, Penfield W. Histochemical and action potential studies on epileptogenic areas of cerebral cortex in man and the monkey. *Res Publ Assoc Res Nerv Ment Dis* 1946;26:218-33.

- Racine R. Kindling: the first decade. *J Neurosurg* 1978;3:234-52.
- Racine RJ, Newberry F, Burnham WM. Post-activation potentiation and the kindling phenomenon. *Electroencephalogr Clin Neurophysiol* 1975;39:261-71.
- Racine R, Kairiss E, Smith G. Kindling mechanisms: the evolution of the burst response versus enhancement. In: Wada JA, ed. *Kindling 2*. New York: Raven Press, 1981.
- Schwartzkroin PA, Wyler AR. Mechanisms underlying epileptiform burst discharge. *Ann Neurol* 1980;7:95-107.
- Torres F, French LA. Acute effect of section of the corpus callosum upon "independent" epileptiform activity. *Acta Neurol Scand* 1973;49:47-62.
- Torres F, Jacome D. Secondary epileptogenesis in the human. In: Mayersdorf A, Schmidt RP, eds. *Secondary epileptogenesis*. New York: Raven Press, 1982.
- Van Buren JM, Ajmone-Marsan C, Matsuga N, Sadowsky D. Surgery of temporal lobe epilepsy. *Adv Neurol* 1975;8:155-96.
- Wada JA, ed. *Kindling*. New York: Raven Press, 1976.
- Wada JA, ed. *Kindling 2*. New York: Raven Press, 1981.
- Wada JA, Osawa T. Spontaneous recurrent seizure state induced by daily electric amygdaloid stimulation in Senegalese baboons *Papio papio*. *Neurology* 1976;26:273-86.
- Wada JA, Sato M, Corcoran ME. Persistent seizure susceptibility and recurrent spontaneous seizures in kindled cats. *Epilepsia* 1974;15:465-78.
- Wada JA, Osawa T, Mizoguchi T. Recurrent spontaneous seizure state induced by prefrontal kindling in Senegalese baboons *Papio papio*. In: Wada JA, ed. *Kindling*. New York: Raven Press, 1976.
- Wilder BJ, Morrell F. Cellular behavior in secondary epileptic lesions. *Neurology* 1967;17:1193-204.
- Wilder BJ, King RL, Schmidt RP. Comparative study of secondary epileptogenesis. *Epilepsia* 1968;9:275-89.
- Wilson DH, Reeves A, Gazzaniga MS, Culver C. Cerebral commissurotomy for the control of intractable seizures. *Neurology* 1977;27:708-15.