

ANTICOAGULANTS AND CEREBRAL VENOUS THROMBOSIS

J. P. HALPERN

Registrar in Neurology, Westmead Centre, Westmead, NSW

J. G. L. MORRIS

Neurologist, Westmead Centre, Westmead, NSW

G. L. DRISCOLL

Obstetrician and Gynaecologist, Westmead Centre, Westmead, NSW

Abstract:

Three patients with cerebral venous thrombosis are described. The management of this rare condition is discussed and a case is made for using anticoagulant therapy provided the diagnosis is established before cerebral infarction or hemorrhage have occurred. (Aust NZ J Med 1984; 14: 643-648.)

Key words: Cerebral venous thrombosis, anticoagulants, pregnancy.

INTRODUCTION

Cerebral venous thrombosis (CVT) is an uncommon condition with a high mortality rate.¹ It usually occurs in late pregnancy or the puerperium. It has also been described in association with a number of other conditions^{2,3} (see Table 1). In the pre-antibiotic era chronic infection of the sinuses and ears was an important cause of CVT.⁴ Under circumstances of increased blood coagulability or reduced cerebral venous flow, thrombus may form in the dural sinuses and cortical veins. This leads to swelling and ultimately infarction of the cerebral hemispheres and impaired drainage of cerebrospinal fluid through the arachnoid villi. The use of

anticoagulants such as heparin and warfarin in preventing propagation of thrombus has been considered inadvisable because of the risk of cerebral hemorrhage.⁵ In this report three patients with cerebral venous thrombosis are presented and a case is made for using anticoagulants provided certain conditions are met.

CASE HISTORIES

Case 1

A 23 year old woman developed a dull bi-frontal headache a few hours after giving birth to a healthy child. The pregnancy had been uneventful and she had gone into labour spontaneously at 39 weeks. There was no significant past history apart from two miscarriages occurring, respectively, at 10 weeks and 16 weeks. An epidural anesthetic had been used during labour to relieve pain and a normal birth had taken place after 6 hours. The headache was initially attributed to leakage of cerebrospinal fluid related to the epidural anesthetic. An epidural 'blood patch' was introduced but the headache became worse. It was particularly noticeable when she sat up. On the 7th day post partum two generalised

TABLE 1

Diseases Associated with Cerebral Venous Thrombosis

pregnancy	hemolytic anemia
puerperium	paroxysmal nocturnal
oral contraceptives	hemoglobinuria
dehydration	cryofibrinogenemia
cachexia	thrombocytopenia
congestive cardiac failure	diabetes mellitus
trauma	ulcerative colitis
sickle cell anemia	

Reprint requests to: Dr J. G. L. Morris, Department of Medicine, Westmead Centre, Westmead, New South Wales, 2145

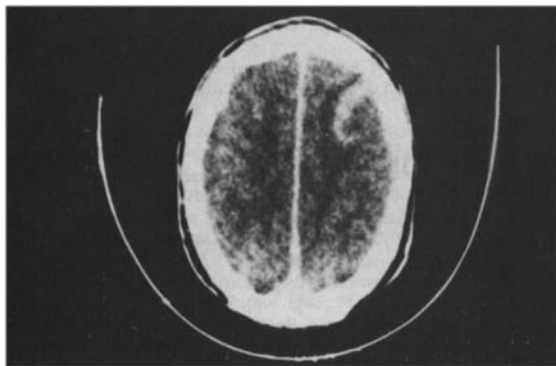


Figure 1: Post-contrast CT Scan of Patient 1 showing a crescentic area of uptake in the left fronto-parietal region.

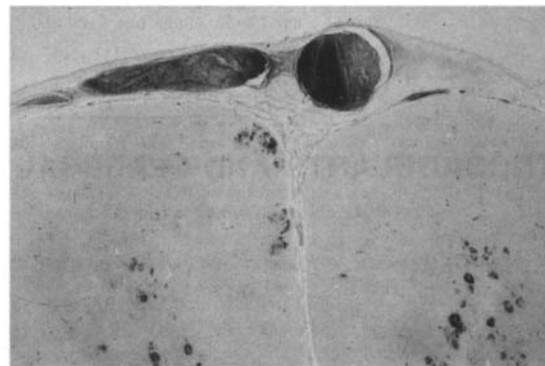


Figure 2: H & E section of a right frontal gyrus in Patient 1 showing a thrombosed surface vein and hemorrhagic areas within the substance of the brain.

tonic-clonic seizures were observed. The second attack was preceded by a frontal adverse seizure in which her head and eyes deviated to the right and the right arm stiffened. Anticonvulsant therapy was instituted. Cerebral computerised axial tomography (CT) showed no abnormality in the precontrast study and a crescentic area of uptake in the left fronto-parietal region following injection of contrast (see Figure 1). Extra contrast was given in order to visualise the sagittal sinuses. Following the CT scan the patient became irritable and photophobic. She had two further generalised tonic-clonic seizures. The hemoglobin was 10.6 g/dl, the white cell count $11.1 \times 10^9/l$ and platelet count $386 \times 10^9/l$. The cerebrospinal fluid (CSF) was slightly blood stained but as there was no xanthochromia it was assumed it had been a traumatic tap. The glucose and chloride concentrations were normal but the protein concentration was elevated at 2.04 g/l. No organisms were seen on Gram stain nor on subsequent culture. An EEG showed bursts of bilateral high voltage delta waves seen maximally over the parietal areas. Viral studies on blood and cerebrospinal fluid were negative.

Dexamethasone was given (4 mg tds) but the patient's condition continued to deteriorate with recurrence of adverse seizures and development of a mild right hemiparesis. Pyrexia (37.6-39.2°C) and sinus tachycardia persisted throughout the illness. A repeat CT scan showed a decrease in the size of the left frontoparietal lesion and the following day a brain biopsy was performed to exclude herpes simplex encephalitis. The patient died the following day, 16 days post-partum. Autopsy revealed antemortem thrombus with prominent lines of Zahn filling both pulmonary arteries. Antemortem thrombus was also present in the deep veins of the calves and in the uterine veins.

Sections from the sagittal and lateral sinuses showed numerous foci of recent thrombosis and also thrombus which was estimated from its degree of organisation to have been present for 3 weeks. There was evidence of thrombophlebitis over the surfaces of both hemispheres with hemorrhagic infarction of the underlying brain (see Figure 2).

Comments

This patient's illness was characterised by headache occurring in the puerperium and followed by focal fits, fever, tachycardia and right hemiparesis. She died from pulmonary embolism. Abnormalities observed on CT scanning were not specific for CVT.

Case 2

A 21 year old woman was observed by her husband to be jerking in her sleep three weeks after delivery by Caesarean section. When he woke her up she was drowsy, irritable and confused. She had been taking insulin for diabetes mellitus since the age of 6 and thyroxine since she developed Hashimoto's thyroiditis at the age of 13. The last trimester of her pregnancy had been characterised by difficulty in diabetic control requiring prolonged hospitalisation. Caesarean section had been performed following her failure to progress in labour. She had subsequently breast-fed her baby.

Assuming that she was hypoglycemic her husband had given her honey but she had remained drowsy. On admission to Westmead Centre her blood glucose level was 3 mmol/l. She was afebrile (36.5°C) with a pulse rate of 88/min and a blood pressure of 130/50 mmHg. She lay with her eyes shut and groaned when spoken to. She would not obey commands but spontaneously moved her limbs. At times she opened her eyes and looked

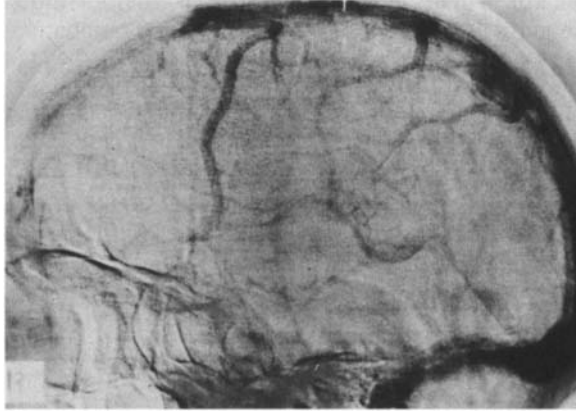

Figure 3: Lateral view of the venous phase of the right carotid angiogram in Patient 2 showing failure of filling of the anterior portion of the superior sagittal sinus.

around her. There was no neck stiffness. Reflexes were symmetrical. There was no papilledema. Shortly after admission she was incontinent of urine and feces. Investigations revealed a hemoglobin of 12.1 gm/dl, white cell count $7.5 \times 10^9/l$ and platelet count $281 \times 10^9/l$. The PTTK was 34 seconds (control 42 seconds). The concentration of fibrin degradation products was 10 $\mu\text{g/ml}$ and of fibrinogen 2.5 g/l. The thrombin time was 15 seconds (control 14 seconds). The biochemical screen was normal as were the arterial blood gases, chest and skull x-rays. Lumbar puncture revealed a colourless CSF at a pressure of 14 cm of water. The fluid contained no polymorphs, three mononuclear cells and 1,005 red cells/ cm^3 . Bacterial cultures were negative. The CSF protein was 0.19 g/l, chloride 132 mmol/l and glucose 4.3 mmol/l. An EEG showed diffuse high voltage delta waves but no localising features. A CT scan was normal both before and after contrast. Bilateral carotid angiography showed prolonged stasis of contrast for up to 12 seconds in the cortical veins draining the right frontal lobe. The anterior third of the superior sagittal sinus failed to fill from this side (see Figure 3). The features were those of sagittal sinus thrombosis. During the next 24 hours the patient remained irritable and had frequent grand mal seizures despite anticonvulsant therapy. She became febrile (38.8°C) and had a persistent tachycardia. Her level of consciousness deteriorated further and she was commenced on dexamethasone (4 mg tds), mannitol, aspirin suppositories and intravenous heparin. She subsequently required intubation and an althesin infusion was necessary to control the fits. She remained febrile over the next four days. Blood cultures were negative. A

ANTICOAGULANTS AND THROMBOSIS

chest x-ray showed right lower zone consolidation and intravenous antibiotics were given. A repeat CT scan was normal. On the fifth day following admission her clinical condition improved markedly and she was extubated. Heparin was ceased a further five days later after satisfactory anticoagulation had been achieved with warfarin. She was discharged a further ten days later and remained on warfarin for two months. Barrier contraception was used initially but she was subsequently sterilised laparoscopically.

Comments

In this patient cerebral venous thrombosis presented as drowsiness, irritability and generalised fits occurring in the puerperium. She was febrile and had a tachycardia which persisted even when her fits were controlled. The diagnosis was confirmed by carotid angiography, CT scanning showing no abnormality. She was anticoagulated and made a full recovery.

Case 3

A 43 year old woman was admitted with a two-week history of a right-sided headache and a two-day history of vomiting. On the day of admission she had noticed weakness of the left side of her body. There had not been any recent illness or pregnancy and she was not on any medication.

She was fully conscious and her temperature, pulse and blood pressure were all normal. There was evidence of early papilledema in the left eye and the left outstretched arm drifted downwards. Both plantar responses were extensor. There were no other abnormal physical signs.

Investigations included a hemoglobin of 17.7 g/dl, hematocrit 50%, white cell count $16.7 \times 10^9/l$ with a neutrophil leucocytosis and an ESR of 3 mm/h. A biochemical screen was normal. Beta-HCG was 1 mIU/ml and anti-nuclear antibodies were negative. Prothrombin time was 14.5 s (control 15 s), PTTK 31.5 s (control 40.5 s), thrombin time 14 s (control 13 s), and fibrin degradation products between 40 and 80 $\mu\text{g/ml}$. Plasma fibrinogen was 3.0 g/l, antithrombin III activity 58% and haptoglobin level was >100 mg/dl. An electrophoretogram showed an elevation in acute phase reactants and the sucrose lysis test was negative. CT scan with and without contrast was normal. On the following day an electroencephalogram showed generalised bursts of 3-4 Hz slow wave activity, these being of high amplitude over the left temporal area. A nuclear brain scan showed reduced flow to the right hemisphere in the dynamic phase, while in the static phase there was accumulation of tracer in the right parietal lobe.

Aust NZ J Med 1984; 14

645

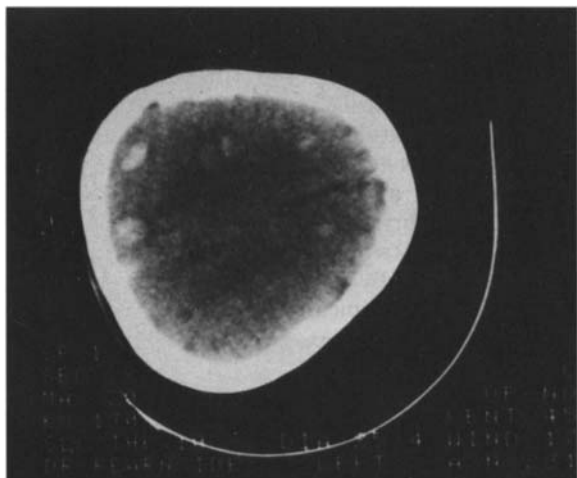


Figure 4: Pre-contrast CT scan of Patient 3 showing multiple small areas of high density consistent with hemorrhagic infarction.

The patient's condition deteriorated. She became drowsy and febrile (38.4 °C) and was noted to have mild neck stiffness. Several left-sided Jacksonian seizures were observed and on three occasions these became generalised. Anticonvulsant therapy was commenced, and on the basis of the EEG and nuclear scan results, a brain biopsy was performed to exclude herpes simplex encephalitis. Post-operatively she continued to have Jacksonian and grand mal seizures. These were not readily controlled and she required intubation and ventilation. Dexamethasone therapy was also initiated. A

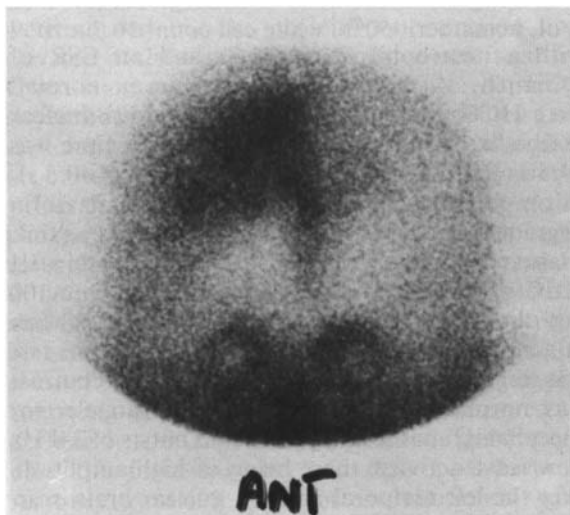


Figure 5: Static brain scan of Patient 3 showing accumulation of radionuclide in the right parietal lobe.

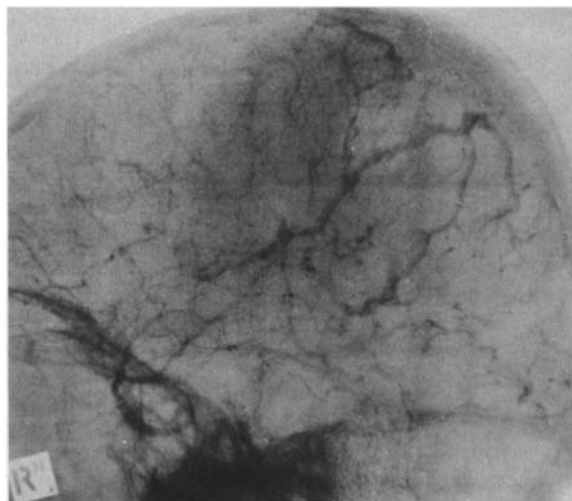


Figure 6: Lateral view of the venous phase of the right carotid angiogram in Patient 3 showing failure of filling of the superior sagittal sinus and delayed emptying of the cortical veins.

repeat CT scan showed multiple small areas of hemorrhage in the right cerebral hemisphere and one on the left side (see Figure 4). A radio-isotope brain scan showed uptake in the right parietal lobe (see Figure 5). On bilateral carotid angiography the cortical veins only partially filled and were slow to empty. Contrast failed to enter the superior sagittal sinus (see Figure 6).

Forty-eight hours after admission venous congestion and edema were noticed in both arms and to a lesser extent in the right leg. There was a persistent pyrexia (38.3-39.5 °C) and mild tachycardia with no obvious source of sepsis. Initial and subsequent chest x-rays were normal. In addition to the anticonvulsants and dexamethasone, antibiotics and Dextran 40 were given. Heparin was given by intravenous infusion at a dose sufficient to prolong the PTTK time by a factor of two. By the tenth day the fever and tachycardia had subsided, and there was gradual improvement in the level of consciousness. The edema in the arms subsided, and the weakness in the left arm and leg lessened.

Improvement continued on a regimen of aspirin, subcutaneous heparin and regular physiotherapy. After three weeks, medication was ceased and she was discharged. She has continued to improve but has been left with slight weakness of the left arm and mild papilledema.

Comments

The cause of CVT in this patient was never established. Dehydration due to vomiting may have

contributed to her problem but her headaches antedated this by several days. Like the first patient she had focal fits, hemiparesis, fever and tachycardia. She also developed venous thrombosis of the limbs. Her initial CT scan was normal and, while the second scan was suggestive of cerebral venous thrombosis, definitive diagnosis depended upon carotid angiography. Although the CT scan showed small areas of hemorrhagic infarction she tolerated full anticoagulation without ill-effect.

DISCUSSION

The diagnosis of CVT is often delayed or only made post mortem.⁵ This reflects both its rarity and the fact that its individual clinical features (see Table 2) are shared by other conditions. Diagnosis thus depends upon having a high index of suspicion when some or all of these symptoms and signs occur in a setting known to predispose to CVT. The conditions with which it is most likely to be confused are viral encephalitis and cerebral arterial occlusion or hemorrhage. It may not be possible to distinguish these on clinical grounds alone.⁶ Arterial occlusion is less likely to cause severe headaches, fits, fever and tachycardia, and in a drowsy patient is more likely to be associated with a dense neurological deficit such as hemiplegia than is the case with CVT.⁷

The definitive investigation for CVT is bilateral carotid angiography, where delayed oblique views and subtraction techniques may be necessary to demonstrate the occluded vessels. It is not sufficient to demonstrate failure of opacification of part of the dural sinuses to make a diagnosis of cerebral venous thrombosis.⁸ In some patients the anterior portion of the superior sagittal sinus is congenitally absent. In such patients a large ascending frontal vein usually runs parallel to the normal position of the sinus in the frontal region. The lateral sinus may also be absent on one side in normal subjects. Cerebral venous thrombosis is distinguished from congenital agenesis of dural sinuses by the fact that circulation is slowed in the area of thrombosis. This will only be recognised if the film series is continued up to 15 seconds after injection of contrast material.

Specific changes of CVT have been described on CT scanning⁹ but none of these was present in our patients. CT scanning is probably more useful in guiding therapy and excluding other conditions than in confirming the diagnosis. Dynamic radionuclear scanning may be of value in some cases.¹⁰ The diffuse slow waves seen in the EEG of patients with CVT may help to distinguish it from cerebral arterial occlusion where the abnormality is often unilateral. PTTK was shortened in the two patients in whom the test was done. A mild coagulopathy

TABLE 2
Clinical Features of Cerebral Venous Thrombosis

- | |
|---|
| 1. Headache |
| 2. A neurological deficit such as hemiparesis or dysphasia which is often mild even at the height of the illness. |
| 3. Depressed conscious level |
| 4. Fits: focal or generalised |
| 5. Evidence of venous thrombosis in the limbs |
| 6. Fever and sinus tachycardia |

has been reported in other patients with CVT² and this may be useful supporting evidence for the diagnosis. Blood cultures should be done but these are likely to be negative unless there is a recent history of chronic otitis media, sinusitis, bacterial endocarditis or tuberculosis. Chronic otitis media should be considered if the sigmoid and transverse sinuses are found to be thrombosed on angiography (the usual site of thrombosis in this condition).

Although much has been written on CVT no clear guidelines as to the best form of therapy have yet emerged. The physician is thus in the unenviable position of managing a patient, most commonly a young woman with a newly born baby, who has an illness that carries a 30% mortality and for which the treatment is controversial. Fits can be controlled with anticonvulsants; corticosteroids and mannitol may be used to reduce intracranial pressure. Neither of these measures, however, tackles the underlying process of venous thrombosis. While anticoagulants such as heparin and warfarin are of uncertain benefit in the management of arterial thrombosis¹¹ where the thrombus is largely composed of platelets, their value in preventing extension of red thrombus in the veins of the legs and in the chambers of the heart is not disputed. Thrombus forming in the cerebral veins and sinuses is of the latter variety.

Martin¹² first used anticoagulants for CVT in 1941 and his example was followed by many others.¹³⁻¹⁶ The dangers of anticoagulation were first emphasised by Barnett and Hyland¹⁷ who drew attention to the fact that intracerebral and subarachnoid hemorrhage are commonly found in patients who have died of CVT. At post-mortem cerebral infarcts in these patients show intense engorgement of vessels with extravasation of red cells (see Figure 2). Anticoagulants under these circumstances would clearly be contra-indicated. Their use, however, might be justified early in the course of the disease before hemorrhage or cerebral infarction have occurred. With the advent of CT scanning it is now possible to detect cerebral hemorrhage with a high degree of certainty. Significant subarachnoid hemorrhage can be excluded by CSF examination, and physical examination of the patient is likely to reveal whether major cerebral infarction has occurred. CT

scanning is also useful in detecting cerebral infarction, in half the cases an abnormality being visible within 48 hours.¹⁸ That anticoagulants have been given without ill effect to many patients in the past suggests that the risks associated with their use have been overemphasised.

The case against anticoagulants has been expressed most forcefully in recent times by Gettelfinger and Kokmen.⁵ The first three of their seven patients were anticoagulated. Two of these died and were found to have large intracerebral hematomata. The third patient made an uneventful recovery. The circumstances leading to the demise of the two patients is worth reviewing. One developed a cerebral hemorrhage at a time when she was known to have thrombocytopenia and was having thrombolytic therapy in addition to heparin. CVT occurred in the second patient in the setting of paroxysmal nocturnal hemoglobinuria. While on subcutaneous heparin, given for pelvic vein thrombosis, the patient developed sagittal sinus thrombosis and subsequently bled into the left cerebral hemisphere. It is well recognised that even full anticoagulation is often not effective in managing venous thrombosis when it occurs in this extremely rare condition.¹⁹ It is questionable whether cerebral hemorrhage in this patient resulted from uncontrolled cerebral venous thrombosis or was due to the heparin, particularly as the latter was only given by the subcutaneous route presumably in small doses.

The case against using anticoagulation in CVT cannot therefore be regarded as proven. This form of therapy would appear to be appropriate for preventing the extension of thrombus in the cortical veins and would have the additional benefit of reducing the risk of a fatal pulmonary embolism, a common cause of death in this condition (as occurred in Case 1). We propose therefore that anticoagulation should be considered in patients in whom there is no evidence clinically or on CT scanning of cerebral hemorrhage or major infarction. On this basis our third patient should not have been anticoagulated as her CT scan showed small areas of hemorrhagic infarction. That she did not sustain further hemorrhage on this treatment suggests that even this appearance may not be an absolute contra-indication to anticoagulation in a patient who is deteriorating. Heparin therapy should be carefully monitored and preferably administered as a continuous infusion

until satisfactory oral anticoagulation has been achieved. The duration of anticoagulation will depend on the underlying cause. In the case of the puerperium the hyper-coagulable state may persist for up to two months.²⁰ In patients with infective cerebral thrombo-phlebitis anticoagulation is probably not indicated, the main aim of treatment being the elimination of sepsis by antibiotics.³

Acknowledgements

We wish to thank Dr Jonathon Leicester for his helpful criticism and advice in the preparation of this paper.

Accepted for publication: 25 May 1984.

References

1. Carroll JD, Leak D, Lee HA. Cerebral thrombophlebitis in pregnancy and the puerperium. *Q J Med* 1966; 139: 347-67.
2. Estanol B, Rodriguez A, Conte G, Aleman JA, Loyo M, Pizzuto J. Intracranial venous thrombosis in young women. *Stroke* 1979; 10: 680-4.
3. Averback P. Primary cerebral venous thrombosis in young adults: the diverse manifestations of an underrecognized disease. *Ann Neurol* 1978; 3: 81-6.
4. Reading PV, Schurr PH. Thrombosis of the sigmoid sinus: past and present. *Lancet* 1956; 2: 473-6.
5. Gettelfinger DM, Kokmen E. Superior sagittal sinus thrombosis. *Arch Neurol* 1977; 34: 2-6.
6. Cross JN, Castro PP, Jennet WB. Cerebral strokes associated with pregnancy and the puerperium. *Br Med J* 1968; 3: 214-8.
7. Plum F, Posner JB. The diagnosis of stupor and coma. 3rd edn. F. A. Davis and Co., 1982: 134.
8. Newton TN, Potts DG. Radiology of the skull and brain. Vol. 2, Book 4. C. V. Mosby and Co. 1974; 2375-400.
9. Buonanno FS, Moody DM, Ball MR, Laster DW. Computed cranial tomographic findings in cerebral sinovenous occlusion. *J Comp Ass Tom* 1978; 2: 281-98.
10. Barnes B, Winestock DP. Dynamic radionuclide scanning in the diagnosis of thrombosis of the superior sagittal sinus. *Neurology* 1977; 27: 656-61.
11. Mackie MJ, Douglas AS. Oral anticoagulants in arterial disease. *Br Med Bull* 1978; 34: 177-82.
12. Martin JP, Sheehan HL. Primary thrombosis of cerebral veins (following childbirth). *Br Med J* 1941; 1: 349-53.
13. Stansfield FR. Puerperal cerebral venous thrombosis treated with heparin. *Br Med J* 1942; 1: 438.
14. Krayenbuhl HA. Cerebral venous and sinus thrombosis. *Clin Neurosurg* 1966; 14: 1-24.
15. Atkinson EA, Fairburn B, Heathfield KWG. Intracranial venous thrombosis as a complication of oral contraceptives. *Lancet* 1970; 1: 914.
16. Fairburn B. Intracranial venous thrombosis complicating oral contraception: treatment by anticoagulant drug. *Br Med J* 1973; 2: 647.
17. Barnett HJM, Hyland HH. Noninfective intracranial venous thrombosis. *Brain* 1953; 76: 36-49.
18. Houser DW, Campbell JK, Baker HL, Sundt TS. Radiological evaluation of ischemic cerebrovascular syndromes with emphasis on computed tomography. *Radiologic Clinics of North America* 1982; 20: 123-42.
19. Woznia AJ, Kitchens CS. Prospective hemostatic studies in a patient having paroxysmal nocturnal hemoglobinuria, pregnancy and cerebral venous thrombosis. *Am J Obstet Gynecol* 1982; 142: 591-3.
20. Bonnar J, Hathaway WE (eds). *Perinatal Coagulation*. New York: Grune and Stratton, 1978: 180.