

Acute *Kingella kingae* Endocarditis with Recurrent Cerebral Emboli in a Child with Mitral Prolapse

Wei Ling Lee, MD, and Elizabeth C. Dooling, MD

An 11-year-old girl had sudden onset of right hemiplegia and dysphasia with fever. Blood cultures grew *Kingella kingae*. Echocardiography showed a prolapsed mitral valve vegetation, which became larger during a prolonged course of antibiotics. After seven weeks of therapy, when surgery was being planned, the child deteriorated abruptly. A repeat echocardiogram showed that the vegetation had disappeared. Conservative medical management is usually inadequate in treating vegetations associated with bacterial endocarditis; surgery is advised.

Lee WL, Dooling EC: Acute *Kingella kingae* endocarditis with recurrent cerebral emboli in a child with mitral prolapse. *Ann Neurol* 16:88-89, 1984

There are many causes of strokes in children, but few are more amenable to prevention than the neurological complications of bacterial endocarditis (BE). Several studies have shown that BE occurring in patients with mitral valve prolapse tends to be milder than BE associated with other forms of underlying valvular disease, and that embolic episodes are less common [4]. We report a child with previously undiagnosed mitral valve prolapse who evidenced acute aphasia and hemiplegia and was found to have BE resulting from *Kingella kingae*, a pathogen being recognized increasingly, especially in children [1]. During a long course of appropriate antibiotics, she had a second cerebral embolic event.

Case Report

An 11-year-old, right-handed girl was well until cellulitis developed over the left medial malleolus. The following day she awoke with a fever of 39°C, dysphasia, and right hemiplegia, and was admitted to another hospital. On examination she was found to be lethargic but obeyed simple commands. Her speech was slurred and decreased in output. The fundi were

normal. She had a right homonymous hemianopia (RHH), left gaze preference, right central facial paresis, and complete flaccid paralysis of the right limbs, with hyperactive reflexes and a right Babinski's sign. There was an ecchymosis near the left medial malleolus, with a surrounding area of redness and tenderness. Her neck was supple. No heart murmur was heard. All of five blood cultures drawn on the day of admission grew *K. kingae*, sensitive to ampicillin and penicillin but relatively insensitive to chloramphenicol. A throat culture grew normal flora. The cerebrospinal fluid (CSF) contained 11 red blood cells and 276 polymorphonuclear leukocytes per cubic millimeter, a protein level of 24 mg/dl, a sugar concentration of 65 mg/dl, and no bacterial growth. A computed tomographic (CT) scan was normal. Another CT scan 17 days later showed ring enhancement posterolateral to the left thalamus without mass effect (Figure, A). An echocardiogram on the fourth day of hospitalization showed minimal prolapse of the mitral valve leaflets and a mass 1 cm in diameter arising from the posterior leaflet. On serial echocardiograms the mass progressively enlarged. The patient was treated with ampicillin and chloramphenicol intravenously for one week, followed by penicillin for the next six weeks. The fever subsided after 12 days, and her neurological state gradually improved. Blood cultures repeated five weeks after admission were sterile.

Seven weeks after admission an echocardiogram showed a large pedunculated mass (2.4 × 1.8 × 1.0 cm) that moved to and fro between the left atrium and ventricle between systole and diastole. That night, the patient became febrile and developed severe headache, vomiting, drowsiness, and lethargy. Her right pupil dilated, and her dysphasia worsened. She was transferred to Massachusetts General Hospital. An echocardiogram showed that the pedunculated mass was no longer present. Penicillin was withheld for 12 hours, and six blood cultures were drawn. Two were incubated with penicillinase; all six cultures were sterile. A CT scan showed a second lesion in the left middle cerebral artery territory consistent with infarction or abscess (Figure, B). The patient improved with fluid restriction on a regimen of dexamethasone, mannitol, and resumption of parenterally administered penicillin.

Five days later penicillin administration was stopped. Within 36 hours the patient's condition deteriorated. Lumbar puncture showed an opening pressure of 340 mm Hg; the CSF contained 14 red blood cells and 1,120 white blood cells (53% polymorphonuclear leukocytes, 40% lymphocytes, 7% monocytes) per cubic millimeter, a glucose level of 55 mg/dl, a protein concentration of 85 mg/dl, and sterile cultures. Reinstitution of penicillin intravenously for an additional six weeks was followed by clinical improvement and improvement of the CSF formula. CT scans over the next seven weeks showed residual lesions in the distribution of the left middle cerebral artery (Figure, C). The patient remained with RHH, right-sided weakness and sensory loss, and dysphasia 14 weeks after onset of her illness.

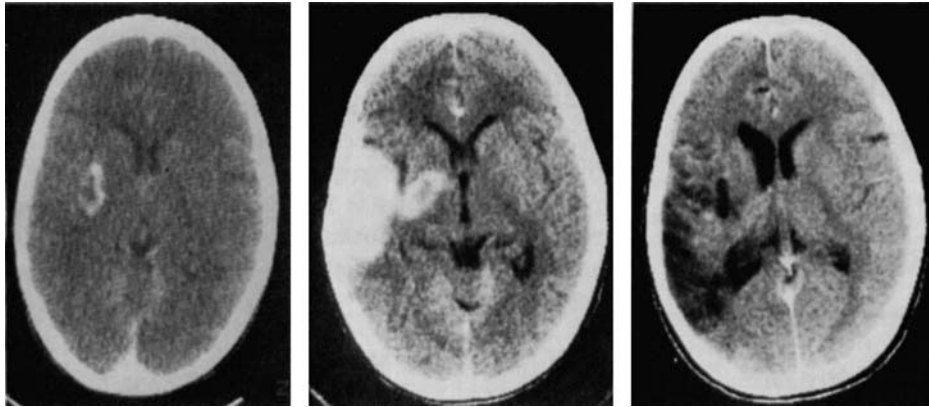
Discussion

Our patient was found to have mitral valve prolapse with BE resulting from *K. kingae*. *K. kingae*, an uncommon inhabitant of the normal upper respiratory tract, is a rare cause of infection, but it can cause BE, sep-

From the Department of Neurology, Harvard Medical School and the Pediatric Neurology Unit, Massachusetts General Hospital, Boston, MA 02114.

Received Nov 28, 1983. Accepted for publication Dec 26, 1983.

Address reprint requests to Dr Lee, Pediatric Neurology Unit, Massachusetts General Hospital, Boston, MA 02114.



Computed tomographic scan. (A) Ring enhancement posterolateral to the left thalamus without midline shift; (B) diffuse enhancement in the distribution of the left middle cerebral artery and ring enhancement in the left thalamus; (C) extensive tissue loss in the distribution of the left middle cerebral artery.

ticemia, arthritis, intervertebral disc infections, and osteomyelitis in normal as well as immunosuppressed patients [1, 8]. Henriksen [3] states that his reported incidence of 1.1% in 437 consecutive nasopharyngeal cultures may be an underestimate, because *K. kingae* grows slowly and is difficult to detect on a culture plate crowded with other nasopharyngeal flora. *K. kingae* is usually sensitive to many antibiotics and is consistently sensitive to penicillin [1, 3, 5].

Although our patient was treated with a long course of parenterally administered penicillin, the mitral valve vegetation was nevertheless enlarged and became pedunculated during this period. Anticoagulants are contraindicated in native valve BE, because they do not prevent growth of vegetations or recurrent embolization but do increase the risk of hemorrhagic complications [7]. The most frequent indication for cardiac surgery in BE is moderate or severe cardiac failure. Septic embolization is another accepted indication [2, 6]. Wann and colleagues [9] have reported that none of 43 patients with BE without vegetations evident on echocardiography required emergency surgery or died as a result of cardiac disease, and none in this group developed cerebral emboli, but 20 of 22 patients with BE with vegetations recognizable by echocardiography died or required cardiac operation. These workers found that vegetations once seen on echocardiography did not disappear with medical therapy alone and changed very little on repeated examinations.

Cardiac surgery was being scheduled when our patient's second cerebral embolism occurred but was cancelled because the vegetation disappeared. Her complicated course illustrates how important early surgical

intervention may be in the prevention of recurrent embolic episodes.

Mary Etta King, MD, kindly interpreted and provided the photographs of the echocardiograms. Drs Richard Liberthson, Joanne Borland, and Richard Katz kindly referred the patient for neurological assessment. E. P. Richardson, Jr, MD, gave advice about the manuscript.

References

1. Bosworth DE: *Kingella kingae* infections in children. *Am J Dis Child* 137:650-653, 1983
2. Boyd AD, Spencer FC, Isom OW, et al: Infective endocarditis. *J Thorac Cardiovasc Surg* 73:23-30, 1977
3. Henriksen SD: Corroding bacteria from the respiratory tract. I. *Moraxella kingii*. *Acta Pathol Microbiol Scand* 75:85-90, 1969
4. Nolan CM, Kane JJ, Grunow WA: Infective endocarditis and mitral prolapse: a comparison with other types of endocarditis. *Arch Intern Med* 141:447-450, 1981
5. Odum L, Frederiksen W: Identification and characterization of *Kingella kingae*. *Acta Pathol Microbiol Scand [B]* 89:311-315, 1981
6. Parrott JCW, Hill JD, Keith WJ, et al: The surgical management of bacterial endocarditis: a review. *Ann Surg* 183:289-292, 1976
7. Priest WS, Smith JM, McGee CJ: The effect of anticoagulants on the penicillin therapy and the pathologic lesion of subacute bacterial endocarditis. *N Engl J Med* 235:699-706, 1946
8. Ravdin JI, Brandstetter RD, Wade MJ, Roberts RB: Endocarditis resulting from *Kingella kingae* presenting initially as culture-negative bacterial endocarditis. *Heart Lung* 11:552-554, 1982
9. Wann LS, Dillon JC, Weyman AE, et al: Echocardiography in bacterial endocarditis. *N Engl J Med* 295:135-139, 1976