

The precise diagnosis of complete transposition by cross sectional echocardiography should, in most cases, obviate the need for cardiac catheterisation and angiography, provided that the operation is performed immediately so that balloon atrial septostomy is not required.

It follows, therefore, that the ideal patient for anatomic correction has simple transposition of the great arteries (the most common type) and has had no previous palliative or preparatory operation. Surgery should be performed in the early neonatal period while fetal pulmonary vascular resistance remains raised, before its fall in the first few days of life.

Because of the most satisfactory early and intermediate results of interatrial correction of transposition of the great arteries for simple transposition<sup>4</sup> we are not inclined to submit our young patients to preparation of the 'systemic ventricle' by surgical means. We feel that the neonate seen early in life is ideally suited for anatomic correction, providing the operative risk is not considered too high.

## Conclusion

We present the successful correction by anatomic repair of transposition of the great arteries and intact ventricular septum in an 18 hours old neonate. It is our opinion that this is the correct approach in the treatment of patients with this cardiac anomaly should an alternative to intra-atrial repair be sought.

## References

- 1 Jatene AD, Fontes VF, Paulista PP, *et al.* Successful anatomic correction of transposition of the great vessels. A preliminary report. *Arq Bras Cardiol* 1975;28:461-4.
- 2 Yacoub MH, Radley-Smith R, MacLaurin R. Two stage operation for anatomical correction of transposition of the great arteries with intact ventricular septum. *Lancet* 1977;1:1275-8.
- 3 Lécompte Y, Zannini L, Hazan E, *et al.* Anatomic correction of transposition of the great arteries. *J Thorac Cardiovasc Surg* 1981;82:629-31.
- 4 Ullal RR, Anderson RH, Lincoln C. Mustard's operations modified to avoid dysrhythmias and pulmonary and systemic venous obstruction. *J Thorac Cardiovasc Surg* 1979;78:431-9.

Correspondence to C Lincoln, Brompton Hospital, London SW3.

Received 16 March 1984

## Glue sniffing and cerebral infarction

M J PARKER, M J TARLOW, AND J MILNE ANDERSON

*University of Birmingham, Department of Paediatrics and Child Health, East Birmingham Hospital, Birmingham*

---

**SUMMARY** A 12 year old boy who was a habitual glue sniffer developed a dense hemiparesis in association with an episode of glue sniffing. Occlusion of the right middle cerebral artery was found. It is postulated that the stroke was precipitated by an episode of vascular spasm.

---

Glue sniffing is a practice which is increasing in prevalence, particularly among adolescent boys in lower socioeconomic groups. Recognised acute sequelae of glue sniffing include death from asphyxiation, inhalation of vomit, cardiac arrhythmias, coma, and convulsions.<sup>1</sup> We report the case of a boy who sustained a dense hemiparesis from cerebral infarction while glue sniffing.

### Case report

A 12 year old Caucasian boy, found by his parents in his bedroom unable to speak or move his right arm or leg, suffered a series of convulsions and was

admitted to hospital. He subsequently admitted to glue sniffing for the previous two years and immediately preceding the incident had been sniffing a plastic modelling glue, Britfix (the main component of which is trichlorethylene), from a plastic bag held over his mouth and nose. He had become euphoric and had twice fallen off his bunk bed. There was a past history of severe behavioural problems, involving violence to other children and a disruptive tendency in the classroom, for which he attended a residential school.

On examination he was drowsy and aphasic but responded purposefully to commands. He had a dense right hemiparesis, a facial palsy, and an extensor plantar response on the right. There was a soft mid systolic murmur radiating to the carotids. Blood pressure and pulse were normal. Computed tomography on the day of admission to hospital was normal; but a tomogram performed four days later showed substantial infarction in the area of the left middle cerebral artery. Left carotid angiography showed an occlusion of the left middle cerebral artery. There was also a congenital abnormality in

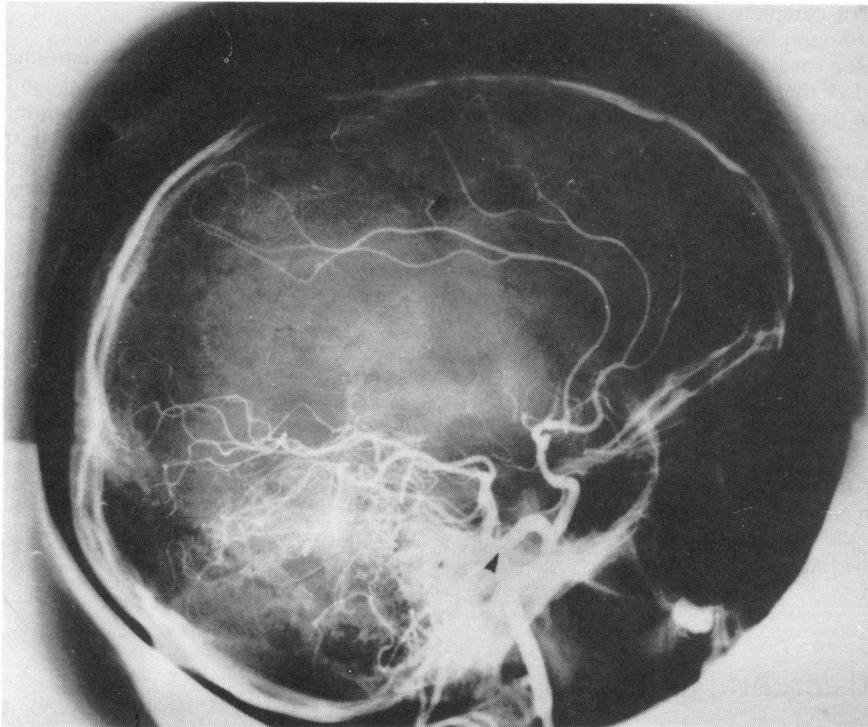


Figure Left carotid angiogram showing obstruction of the middle cerebral artery and the presence of a trigeminal artery (arrowed).

which a trigeminal artery connected the internal carotid to the basilar artery. The carotid artery in the neck was normal. Other investigations including full blood count, platelets, packed cell volume, plasma viscosity, erythrocyte sedimentation rate, biochemical profile, fasting lipids, electrocardiogram, and radiographs of the chest, skull, and cervical spine were all within normal limits. An echocardiogram showed normal heart valves and no evidence of mural thrombosis. Screening tests for homocystinuria and syphilis were negative.

#### Comment

Cerebral infarction in other forms of drug abuse has been reported in 9 patients after self administration of intravenous heroin<sup>2</sup> and in a 14 year old boy after ingestion of four tablets of lysergic acid diethylamide (LSD).<sup>3</sup> The mechanism by which these drugs cause cerebral infarction remains unclear—an immune aetiology has been suggested for heroin,<sup>2</sup> and vascular spasm had been implicated in the aetiology of stroke after LSD abuse.<sup>3</sup> Cerebral

infarction in our patient may have been the result of the latter mechanism. Trichlorethylene is known to sensitise end organ receptors in blood vessel walls to the effect of circulating catecholamines.<sup>4</sup> This effect may be potentiated both by hypercapnoea associated with rebreathing from a plastic bag,<sup>5</sup> and by the catecholamine release expected in the excitement phase of glue sniffing.

Trauma to the carotid artery in the neck with subsequent embolism, after a fall from the bunk bed has been excluded by the normal cervical angiogram. The echocardiogram failed to show any evidence of mural thrombus formation or any other intracardiac pathology. There was no evidence to support a transient hypercoagulability of blood while glue sniffing. Platelet count, packed cell volume, and erythrocyte sedimentation rate were all normal and there was neither an increase in acute phase reactants nor any suggestion of disseminated intravascular coagulation. Alterations in blood coagulability have not, to our knowledge, been reported in association with glue sniffing. The presence of the persistent trigeminal artery on the

angiogram is probably coincidental but may possibly have contributed to thrombus formation by shunting blood away from the left cerebral artery.

While cerebral infarction from glue sniffing has not previously been described, the rarity of cerebrovascular incidents at this age and the onset of symptoms while glue sniffing must make the association highly probable.

#### References

- <sup>1</sup> Edwards IR. Solvent abuse. *NZ Med J* 1982;**95**:879–80.
- <sup>2</sup> Caplan LR, Hein DB, Banks G. Stroke and drug abuse. *Stroke* 1982;**13**:869–72.
- <sup>3</sup> Sobel J, Espinas O, Friedman S. Carotid artery obstruction following LSD capsule ingestion. *Arch Intern Med* 1971;**127**:290–1.
- <sup>4</sup> Bass M. Sudden sniffing death. *JAMA* 1970;**212**:2075–9.
- <sup>5</sup> Price H, Lurie AA, Jones RE, *et al.* Cyclopropane anaesthesia II: epinephrine and norepinephrine in initiation of ventricular arrhythmia by carbon dioxide inhalation. *Anesthesiology* 1958;**19**:619–30.

Correspondence to Dr M J Tarlow, University of Birmingham, Department of Paediatrics and Child Health, East Birmingham Hospital, Bordesley Green East, Birmingham B9 5ST.

Received 13 March 1984