

Painful Ataxic Hemiparesis

Julien Bogousslavsky, MD; Franco Regli, MD;
Joseph Ghika, MD; Jean-Jacques Feldmeyer, MD

● **Right hemiparesis with right-sided pain and ataxia developed in a 68-year-old man. Sensation, neuropsychological function, and somatosensory evoked potentials were normal. Computed tomography showed an isolated fresh infarct in the left part of the thalamus. The pain and ataxic disturbances were related to involvement of the thalamus itself, but the hemiparesis with hyperactive tendon reflexes and Babinski's sign was probably due to associated dysfunction in the adjacent internal capsule from compression or edema. In the available clinicopathological reports of cases with hemiparesis and thalamic infarction, contiguous involvement of the internal capsule or no associated lesion has been reported. Because of the occurrence of pain, which is not present in pontine, mesencephalic, or capsular ataxic hemiparesis, we suggest that the syndrome seen in our patient be called "painful ataxic hemiparesis."**

(*Arch Neurol* 1984;41:892-893)

Occurrence of hemiparesis and cerebellar ataxia on the same side of the body has been called *ataxic hemiparesis*,¹ and is usually caused by a small deep infarct in the contralateral upper pons or internal capsule.¹⁻⁹

Accepted for publication Aug 13, 1983.

From the University Department of Neurology, Centre Hospitalier Universitaire Vaudois, Lausanne, Switzerland.

Reprint requests to Department of Neurology, Centre Hospitalier Universitaire Vaudois, 1011 Lausanne, Switzerland (Dr Bogousslavsky).

Ataxic hemiparesis is a rather uncommon syndrome, and its frequency has been evaluated from less than 1% to 9% among deep infarcts and lacunae.¹⁰⁻¹² We report a case of ataxic hemiparesis with associated pain in the homolateral arm, but without altered sensation, in which computed tomography (CT) showed evidence of an isolated recent infarct in the contralateral thalamus.

REPORT OF A CASE

A 68-year-old former policeman without known vascular risk factors suddenly experienced violent burning pains in the right arm and shoulder that were associated with weakness and clumsiness of the right arm and leg. No diplopia or other visual symptom, speech, or mental disturbances were present. After seven days, when he was admitted to the hospital, the pain, as well as the hemiparesis, had improved, but the patient still complained of right-sided ataxia.

Neurological Examination

Optic fundi, visual acuity, and visual fields were normal. The pupils were in the medium range and fully reacted to light and accommodation. Ocular movements were normal, without nystagmus. Optokinetic nystagmus was normal and symmetrical. Facial sensation was preserved, with symmetrical corneal reflex. A slight inferior facial paresis was noted. Mandibular movements were intact, as was the jaw reflex. There was no dysarthria or dysphagia, and the palate moved symmetrically. Gag reflex was normal. The tongue protruded in the midline. Bilateral conduction hypoacusis was present. There was right-sided weakness of the limbs, with crural

and proximal predominance (3/5). Tendon reflexes were hyperactive on that side, with Babinski's sign. Palmomental and grasp reflexes were absent. The superficial abdominal reflexes were present and symmetrical. There was right-sided dysmetria, hypermetria, and dysdiadochokinesia, with intention tremor and abnormal rebound phenomena. No asterixis was present. The disturbances were more severe in the leg than in the arm. Touch, pain, temperature, position, and vibration sensation were fully preserved, with normal two-point discrimination, graphesthesia, topeesthesia, and stereognosis. The gait was only slightly disturbed by the right-sided disturbances, without gross ataxia. Detailed neuropsychological examination did not disclose any speech, memory, gnosis, or praxia disturbance. No motor, sensory, visual, or auditory neglect was present. Results of general examination were normal. The right arm and shoulder did not show any local abnormality that would explain the pain. No carotid bruit was heard. Blood pressure was 140/90 mm Hg.

Results of standard blood and urine tests were normal. The ESR was 2 mm in the first hour. The ECG was normal. On Doppler ultrasonography, the carotid and ophthalmic arteries were normally detected, but the left vertebral artery could not be detected (retromastoid approach). The CSF was normal. Somatosensory evoked potentials (stimulation of the median nerve) did not show any asymmetry or abnormal responses. Computed tomography (Fig 1) showed a hypodense area in the lateral part of the left side of the thalamus. The cerebral hemispheres, the brain stem, and the cerebellum did not show any other area of decreased attenuation.

Evolution

After ten days, the pain and weakness had nearly disappeared, but ataxia and Babinski's sign still persisted. Computed tomography (Fig 2) showed a better demarcation of the area of decreased attenuation in the left part of the thalamus.

Fig 1.—Initial computed tomographic scan seven days after onset of symptoms. Note area of low density in lateral part of left side of thalamus.

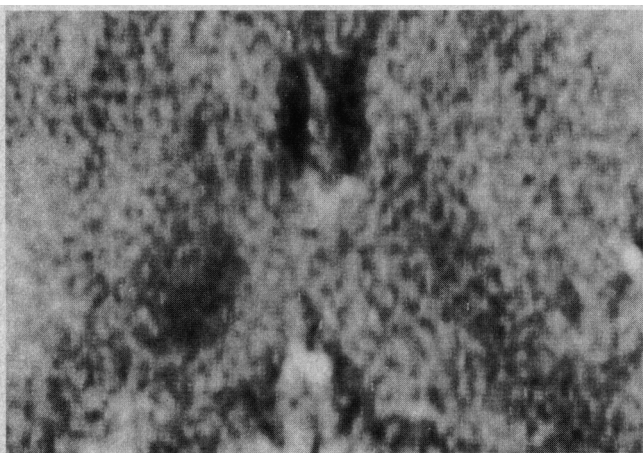
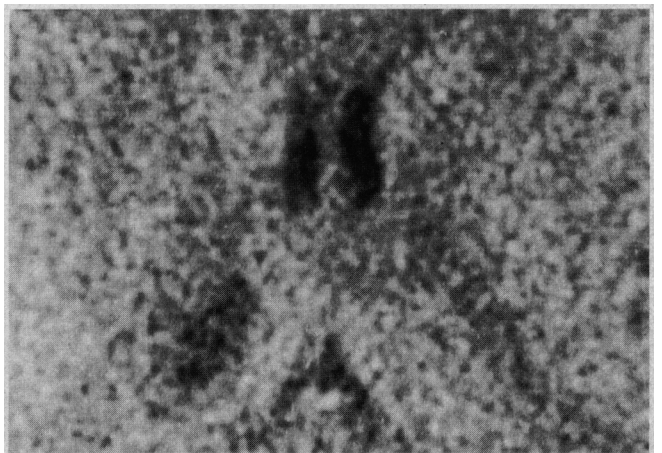


Fig 2.—Second computed tomographic scan done seven days after that in Fig 1. Hypodense area at same site is better demarcated.



COMMENT

Ataxic hemiparesis, the combination of homolateral weakness and "cerebellar" dysfunction, was initially reported as a vascular syndrome in 14 patients with homolateral ataxia and crural paresis.² In the one case studied at autopsy, infarction of the posterior limb of the contralateral internal capsule was present, but was associated with other infarcts. Since then, the only available pathological examinations showed lacunar infarction in the upper basis pontis in three cases¹ and pontine glioma in one case.¹³ In these cases, the lesion interrupted the corticospinal fibers and the corticopontine fibers before the decussation of the superior cerebellar peduncles. In these patients with pontine infarction, tumor, or hemorrhage,¹⁴ associated oculomotor disturbances¹ or cranial nerve dysfunction⁴ are usually present.

Other reports with CT study^{3,5,6,11,12} described small deep infarcts involving the posterior limb of the contralateral internal capsule sometimes extending toward the corona radiata region. In these cases, the frontopontine and temporoparietopontine bundles are not involved, because they respectively course in the anterior limb and the retrolenticular or sublenticular portion of the internal capsule. The cerebellar dysfunction is probably related to destruction of corticopontine fibers from the precentral cortex or connecting fibers between the ventrolateral nucleus of the thalamus and the precentral region. Unlike the situation in pontine lacuna, no oculomotor or cranial nerve abnormality is present. Ataxic hemiparesis from a mass in the contralateral rostral mesencephalon has also been reported.¹⁵

Our patient showed typical ataxic hemiparesis, and CT scan showed an isolated hypodense area compatible with fresh contralateral infarction of the thalamus, immediately adjacent to the posterior limb of the internal capsule. No objective sensory disturbances were present, but the patient complained of initial burning pain in the corresponding upper limb. Although the typical Dejerine-Roussy syndrome (hypoesthesia with hyperpathia) is more usual, a painful syndrome without altered sensation has already been reported in thalamic infarcts.^{16,17} Usually, thalamic lacuna or gross infarction produce objective sensory disturbances, and sometimes mental dysfunction, aphasia, dysmnnesia, or neglect.^{8,18-22} None of these troubles was present in our case. However,

contralateral cerebellar ataxia may also be present, when the middle part of the lateral thalamus is involved, with subsequent interruption of the dentato(rubro)thalamic afferent fibers.^{16,17,21}

Also, Garcin²³ and Garcin and Lapresle¹⁶ reported the cases of two patients with unilateral cerebellar ataxia, in whom an isolated infarction of the ventrolateral nucleus of the contralateral thalamus (in the first case) and an infarction involving the dorsomedial nucleus, the anterior part of the centromedian nucleus, and intralaminar nuclei of the contralateral thalamus (in the second case) were demonstrated at autopsy. The first patient initially showed associated pain in the inferior limb and transient disturbances of deep sensation. The second patient showed associated numbness and paresis of the lower limb, with Babinski's sign. In this case, in our case, and in other reported cases with corticospinal dysfunction,^{17,21,24-26} hemiparesis and Babinski's sign may be related to functional involvement of the adjacent internal capsule, from local edema or compression.^{16,25} In the autopsied cases,^{16,25} no visible focal lesion along the corticospinal pathways could be established. Associated infarction of the adjacent portion of the internal capsule may be another explanation, although such a possibility has been reported only once.²⁷ Involvement of the cerebral peduncle, as in the hemiplegic syndrome of the posterior cerebral artery,²⁸ seems less probable, because of the absence of severe paresis, hemianopia, or alexia.

In summary, our case suggests that ataxic hemiparesis may be related to contralateral thalamic infarction. Another case with ataxic hemiparesis was reported in association with a thalamic syndrome,¹³ but no CT scan was provided, and the point was not discussed. In our case, involvement of the ventrolateral nucleus of the thalamus was probably responsible for the ataxia, because CT scan showed infarction of the lateral part of the thalamus. More medial nuclei (dorsomedial nucleus, intralaminar nuclei) were probably not involved. Despite initial pain, the ventroposterior nucleus was probably partially spared because of normal sensation and somatosensory evoked potentials. Because severe pain was initially present in the corresponding upper limb, we suggest that homolateral ataxia and corticospinal dysfunction from thalamic infarction should be called "painful ataxic hemiparesis."

References

1. Fisher CM: Ataxic hemiparesis. *Arch Neurol* 1978;35:126-128.
2. Fisher CM, Cole M: Homolateral ataxia and crural paresis: A vascular syndrome. *J Neurol Neurosurg Psychiatry* 1965;28:48-55.
3. Perman GP, Racy A: Homolateral ataxia and crural paresis: Case report. *Neurology* 1980;30:1013-1015.
4. Sakai T, Murakami S, Ito K: Ataxic hemiparesis with trigeminal weakness. *Neurology* 1981;31:635-636.
5. Ichikawa K, Tsutsumushita A, Fujioka A: Capsular ataxic hemiparesis. *Arch Neurol* 1982;39:585-586.
6. Iragui VJ, McCutchen CB: Capsular ataxic hemiparesis. *Arch Neurol* 1982;39:528-529.
7. Jokelainen M, Pilke A: Ataxic hemiparesis. *Arch Neurol* 1983;40:326.
8. Tredici G, Bogliun G, Sanguineti I: Capsular ataxic hemiparesis. *Arch Neurol* 1983;40:326.
9. De Renzi E, Nichelli P, Crisi G: Hemiataxia and crural hemiparesis following capsular infarct. *J Neurol Neurosurg Psychiatry* 1983;46:561-563.
10. Pullicino P, Nelson RF, Kendall BE, et al: Small deep infarcts diagnosed on computed tomography. *Neurology* 1980;30:1090-1096.
11. Weisberg LA: Lacunar infarcts: Clinical and computed tomographic correlations. *Arch Neurol* 1982;39:37-40.
12. Donnan GA, Tress BM, Bladin PF: A prospective study of lacunar infarction using computerized tomography. *Neurology* 1982;32:49-56.
13. Radhakrishnan K, Malhotra AK, Shridharan R, et al: Ataxic hemiparesis: Clinical, electrophysiologic, radiologic and pathologic observations. *Clin Neurol Neurosurg* 1982;84:91-100.
14. Schnapper RA: Pontine hemorrhage presenting as ataxic hemiparesis. *Stroke* 1982;13:518-519.
15. Bendheim PE, Berg BO: Ataxic hemiparesis from a midbrain mass. *Ann Neurol* 1981;9:405-407.
16. Garcin R, Lapresle J: Incoördination cérébelleuse du membre inférieur par lésion localisée de la région interne du thalamus contralatéral. *Rev Neurol* 1969;120:5-13.
17. Martin JJ: Sémiologie et neuropathologie thalamiques humaines. *Acta Neurol Belg* 1970;70:771-794.
18. Fisher CM: Pure sensory stroke involving face, arm, and leg. *Neurology* 1965;15:76-80.
19. Fisher CM: Thalamic pure sensory stroke: A pathologic study. *Neurology* 1978;28:1141-1144.
20. Castaigne P, Lhermitte F, Buge A, et al: Paramedian thalamic and midbrain infarcts: Clinical and neuropathological study. *Ann Neurol* 1980;10:127-148.
21. Bogousslavsky J, Regli F, Schneider C: Les ramollissements dans le territoire de l'artère cérébrale postérieure: Syndromes cliniques, manifestations initiales, facteurs de risque: Etude de 50 cas. *Med Hyg* 1981;39:3469-3478.
22. Mohr JP: Lacunes. *Stroke* 1982;13:3-11.
23. Garcin R: Syndrome cérébellothalamique par lésion localisée du thalamus: Avec une digression sur le 'signe de la main creuse' et son intérêt sémiologique. *Rev Neurol* 1955;93:143-149.
24. Foix C, Hillemand P: Les syndromes de la région thalamique. *Presse Med* 1925;33:113-117.
25. Garcin R, Lapresle J: Deuxième observation personnelle de syndrome sensitif de type thalamique par lésion localisée du thalamus. *Rev Neurol* 1960;103:474-481.
26. Caplan LAR: 'Top of the basilar' syndrome. *Neurology* 1980;30:72-79.
27. Mohr JP, Kase CS, Meckler RJ, et al: Sensorimotor stroke due to thalamocapsular ischemia. *Arch Neurol* 1977;34:739-741.
28. Benson DF, Tomlinson EB: Hemiplegic syndrome of the posterior cerebral artery. *Stroke* 1971;2:559-564.