

Cerebral Hyperperfusion after Carotid Endarterectomy: A Cause of Cerebral Hemorrhage

Mark Bernstein, M.D., J. F. Ross Fleming, M.D., F.R.C.S.(C), and John H. N. Deck, M.D., F.R.C.P.(C)

Divisions of Neurosurgery and Neuropathology, Toronto Western Hospital and University of Toronto, Toronto, Ontario

Correction of a very high grade carotid stenosis by endarterectomy in a normotensive man was followed by the development of severe unilateral head, eye, and face pain, seizures, and on the 6th day a fatal intracerebral hemorrhage. Autopsy revealed changes in the cerebral hemisphere ipsilateral to the endarterectomy that resembled the changes seen in malignant hypertension, whereas the opposite hemisphere was normal. These changes included hypercellularity and edema of arterial and arteriolar walls, with necrosis, extravasation of erythrocytes, and exudation of fibrin. We propose that the clinical and pathological features in this case were due to relative hyperperfusion of a cerebral hemisphere in which autoregulation had been impaired because of preoperative chronic hypoperfusion with chronic maximal dilatation of its blood vessels. This state of relative hyperperfusion is probably similar to the normal perfusion pressure breakthrough that occasionally occurs after the resection of cerebral arteriovenous malformations. It is similar to the breakthrough perfusion that occurs in severely hypertensive patients and results in hypertensive encephalopathy. (*Neurosurgery* 15:50-56, 1984)

Key words: Carotid endarterectomy, Carotid stenosis, Cerebral hyperperfusion, Endarterectomy, Intracerebral hemorrhage, Malignant hypertension

Correction of high grade stenosis by endarterectomy may result in an increase in cerebral blood flow to well above normal values, with hyperperfusion of a cerebral hemisphere that had been adapted to low perfusion and had been functioning normally. Sundt et al. reported blood flow 2 to 3 times the preoperative values, with mean postoperative blood flow rates in some cases as high as 85.5 ml/100 g/minute, suggesting paralysis of autoregulatory mechanisms (12). The clinical features of such hyperperfusion may include seizures, unilateral migraine-like head, eye, and face pain, and intracerebral hemorrhage. The relationship of postendarterectomy migraine-like pain to hyperperfusion is not widely recognized, and the triad of seizures, headache, and intracerebral hemorrhage occurring in one patient has not been previously reported. When intracerebral hemorrhage occurs after endarterectomy in the absence of obvious predisposing factors such as recent cerebral infarction, hypertension, or anticoagulation, hyperperfusion may be responsible.

Hyperperfusion after the correction of high grade carotid stenosis is probably equivalent to normal perfusion pressure breakthrough, a term coined by Spetzler et al. to describe the malignant edema and hemorrhage that sometimes occur in a cerebral hemisphere after the resection of an arteriovenous malformation (9). The clinical and pathological features of our patient make a strong case for the occurrence of an acute hypertensive encephalopathy secondary to normal perfusion pressure breakthrough (relative hyperperfusion) in a hemisphere rendered susceptible by the loss of autoregulation because of chronic hypoperfusion due to high grade carotid stenosis.

CASE REPORT

A 56-year-old man was found to have bilateral carotid bruits on routine physical examination. He had previously been well except for bilateral femoral-popliteal bypass operations for leg claudication. He was not hypertensive. He had had no symptoms suggesting cerebral or retinal ischemic attacks. His neurological examination was negative. His blood

pressure was 150/80. Doppler flow studies showed bilateral carotid artery disease, with severe stenosis of the left common carotid bifurcation, failure of imaging of the left internal carotid artery, and reversal of direction of the left orbital blood flow; the lumen of the right internal carotid artery appeared to be reduced by 50%. The patient was admitted for further investigation.

Angiography revealed an extremely high grade stenosis at the origin of the left internal carotid artery (Fig. 1). A left common carotid arteriogram showed poor filling of the left middle cerebral artery and no filling of the anterior cerebral artery (Fig. 2). There was a moderate degree of stenosis at the origin of the right internal carotid artery, but right carotid injection showed good filling of the right anterior and middle cerebral arteries, as well as some cross filling of the left anterior and middle cerebral arteries (Fig. 3).

Because of the extreme degree of stenosis of the left internal carotid artery, endarterectomy was decided upon. Left carotid endarterectomy was performed 7 days after angiography. An intraoperative shunt was not used. The patient was given a single bolus of 7000 units of heparin before the artery was clamped off. The heparin was not reversed after operation. The clamp-off time was 41 minutes. There were no operative complications.

The immediate postoperative period was uneventful. Treatment with platelet antiaggregants (650 mg of enteric-coated aspirin twice daily) was commenced on the 2nd postoperative day. About 24 hours after operation, the patient began to complain of severe, pounding left orbital frontal and temporal headache. Thirty-six hours postoperatively, he had two grand mal seizures. After the seizures, the patient was neurologically normal, but he continued to experience severe left frontotemporal and periorbital pain. The pain continued during the next few days and was sometimes severe enough to require codeine. His blood pressure remained normal.

On the 6th postoperative day, the patient complained of marked worsening of the left periorbital pain, and a few hours later he began to vomit. He developed right hemiplegia that rapidly progressed, and over the course of 30 minutes he

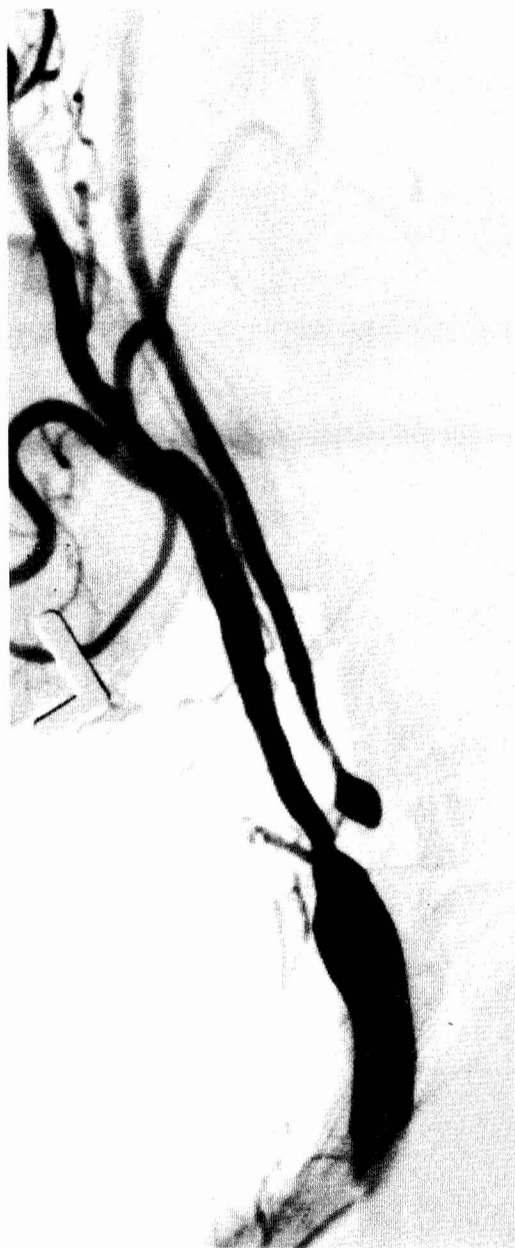

FIG. 1. Angiogram shows an extremely high degree of stenosis at the origin of the left internal carotid artery.

became profoundly comatose with bilateral dilated and fixed pupils. A computed tomographic (CT) scan showed a large, high density, irregularly shaped hematoma extending into the frontal, temporal, and parietal lobes of the left hemisphere (Fig. 4). His oculocephalic and corneal reflexes were lost. Endotracheal intubation, hyperventilation, and intravenous mannitol brought about no improvement. Because of the devastated neurological condition and the extensive destruction of the left cerebral hemisphere, evacuation of the hematoma was not attempted. The patient deteriorated and died 12 hours after the onset of the hemorrhage.

At autopsy, the heart showed left ventricular hypertrophy with a heart weight of 470 g. Coronary atherosclerosis was severe, with 90% stenosis of the right coronary artery. A subendocardial infarct of the posterior septum and the lateral wall of the left ventricle was 1 week old.

The left carotid endarterectomy site was free of thrombus, and the left common, internal, and external carotid arteries were widely patent at all levels. Examination of the brain revealed a fresh, massive hematoma in the left cerebral hemisphere (Fig. 5), resulting in herniation of the left hippocampal gyrus, infarction in the left posterior cerebral artery distribution, and secondary hemorrhages in the upper brain stem.

Small arteries and arterioles throughout the left cerebral hemisphere showed reactive changes consisting of swelling of endothelial cells and hyperplasia of these and other blood vessel cells indicated by hypercellularity and the presence of occasional mitotic figures. Some of these vessels showed margination and extravasation of neutrophils. In the left parietal lobe, small arteries showed, in addition, necrosis with extravasation of erythrocytes and exudation of fibrin (fibrinoid necrosis); there was marked edema of the adjacent brain. These features are highly reminiscent of the changes seen in cases of malignant hypertension. Small blood vessels of the opposite hemisphere showed none of these changes (Figs. 6 to 9).

DISCUSSION

Intracerebral hemorrhage is an uncommon complication after carotid endarterectomy. In published reports, the factors most often associated with postendarterectomy cerebral hemorrhage include recent cerebral infarction (2-4, 11, 13, 15) and severe postoperative hypertension (1, 2, 5, 8, 13). Other factors that may be associated with postendarterectomy cerebral hemorrhage include frequent transient ischemic attacks immediately before operation (1, 2), previous (old) cerebral infarction (1), and the use of systemic anticoagulants postoperatively (10, 12). None of these factors was present in our patient. He was a normotensive man with no history of transient ischemic attacks or cerebral infarction; after the surgical correction of a very high grade carotid stenosis, he developed migraine-like head, eye, and face pain and seizures, followed by intracerebral hemorrhage. He had not received postoperative anticoagulants.

We suggest that the state of chronically reduced perfusion pressure in the microcirculation of the left cerebral hemisphere caused by the extremely tight left internal carotid stenosis had rendered the microcirculation unusually susceptible to injury. Injury analogous to that occurring in malignant hypertension was precipitated by the sudden elevation of perfusion pressure to more normal levels after endarterectomy. The pathological findings in this case form the basis for such an hypothesis. Evidence of beginning adaptation to the altered hemodynamic state is manifest by active proliferation of the cells of small arterial walls, evidence of altered vascular permeability, and fibrinoid necrosis of small arteries. These changes were confined to the left cerebral hemisphere.

The reactive changes of small arteries in the left cerebral hemisphere were not thought to be secondary to the mass effect of the left parietal lobe hematoma because they were present throughout the entire hemisphere in areas remote from the hematoma and had features indicating an age greater than the 12-hour interval between hemorrhage and death. Nor were they a reaction to ischemia that might possibly have occurred at the time of operation or postoperatively, for there was no histological evidence of any ischemic change in the brain parenchyma. The findings suggest that the microcirculation had become ill-adapted to withstand normal perfusion pressure and had reacted to it in a manner analogous to that exhibited by normal vessels when exposed to suddenly elevated perfusion pressure, as in malignant hypertension.

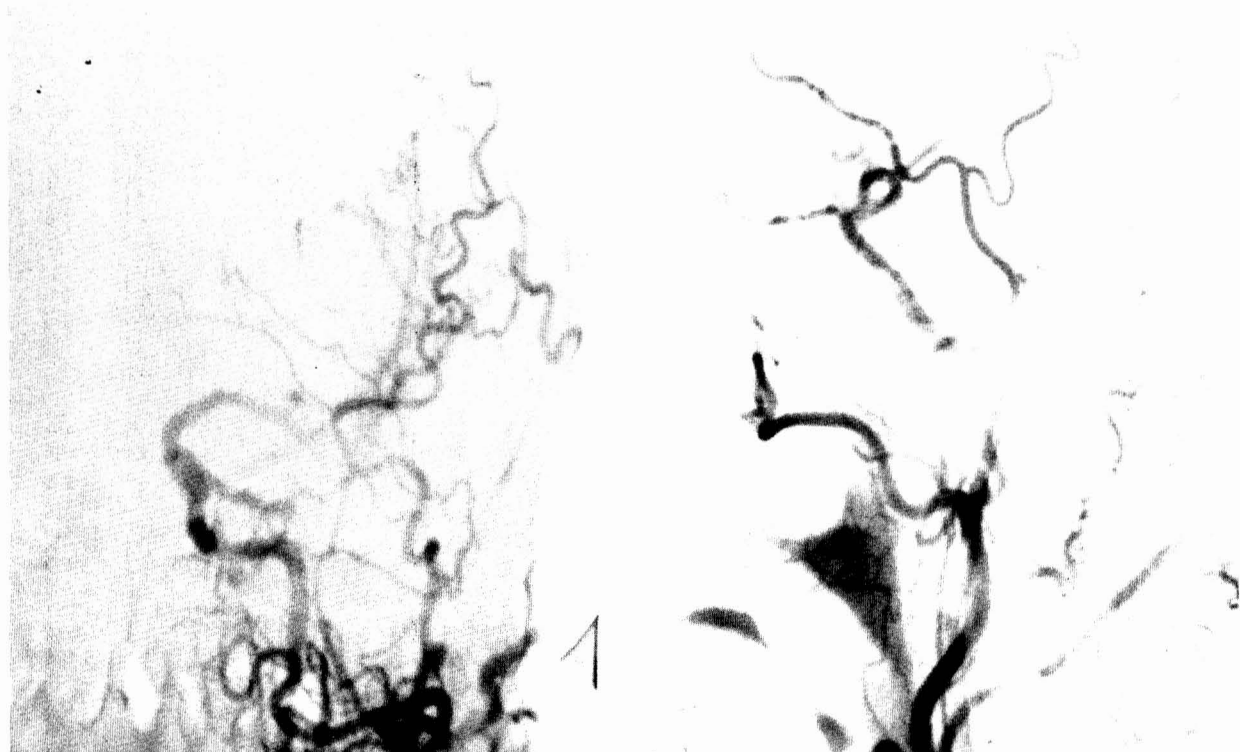


FIG. 2. Left common carotid injection of contrast medium (anteroposterior (*left*) and lateral (*right*) projections) shows poor filling of the left internal carotid and middle cerebral arteries and no filling of the anterior cerebral artery.

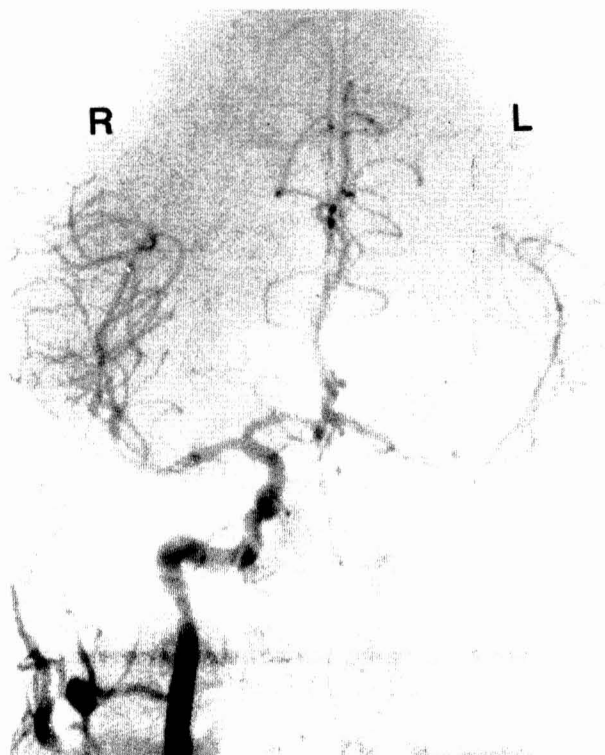


FIG. 3. Right common carotid injection of contrast medium shows good cross filling of the left anterior and middle cerebral arteries.

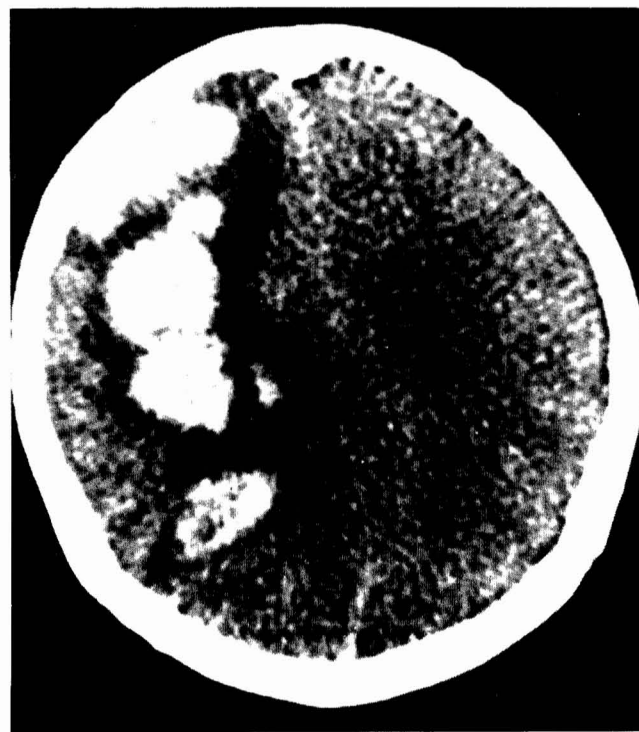

FIG. 4. CT scan 6 days after carotid endarterectomy shows a large, irregularly shaped hemorrhage extending through the left frontotemporal and parietal lobes.

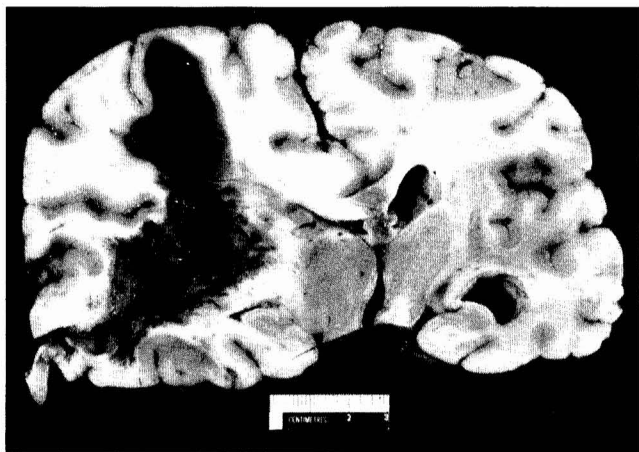


FIG. 5. Section of the brain at autopsy 7 days after carotid endarterectomy shows massive fresh hematoma extending through the left cerebral hemisphere.

A similar suggestion was made by Sundt et al. on the basis of cerebral blood flow studies performed before and after carotid endarterectomy (12). They reported a group of patients in whom blood flow in the affected cerebral hemisphere was reduced preoperatively to values between 20 and 25 ml/100 g/minute (40% of normal flow). After correction of very high grade stenosis, flows increased by as much as 200% in some patients, with values up to between 75 and 85 ml/100 g/minute. The occurrence of such marked hyperemia after the restoration of normal perfusion pressure confirmed that cerebral autoregulation was severely impaired. Sundt et al. concluded that their data supported "the contention that cerebral hyperperfusion can result in a form of unilateral hypertensive encephalopathy." Our findings show that there is a structural basis for the hyperperfusion syndrome and that it is indeed analogous to hypertensive encephalopathy.

The cerebral hemodynamics that we are proposing could be considered analogous to the hyperperfusion syndrome seen after the resection of some arteriovenous malformations. Spetzler et al. concluded that, in a hemisphere made chronically ischemic by a steal caused by an arteriovenous fistula, normal

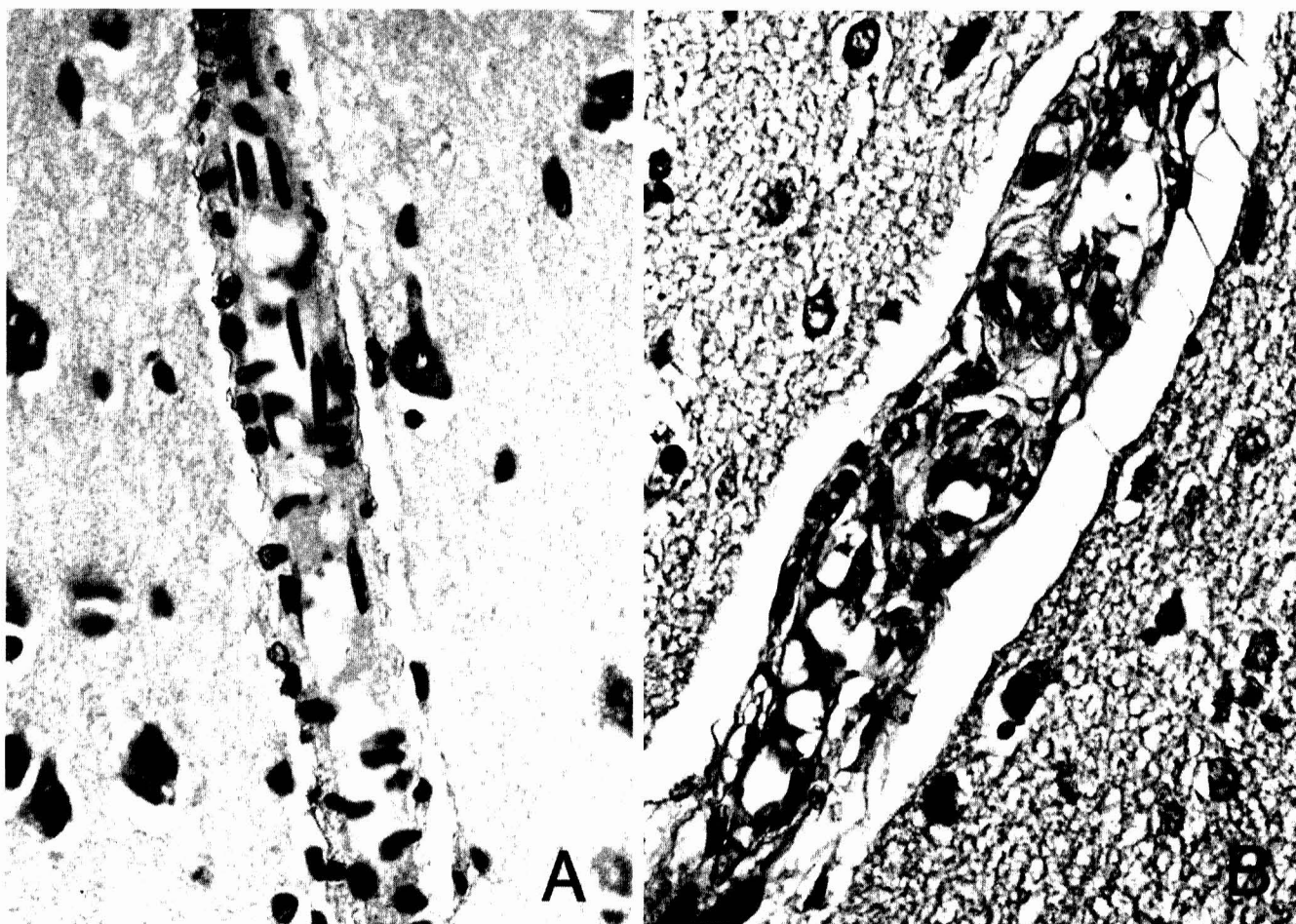


FIG. 6. *A*, penetrating cortical artery in the right posterior frontal lobe shows normal cellularity of endothelial cells with longitudinal nuclei and smooth muscle cells. The adjacent neuropil is also normal. *B*, penetrating cortical artery in the corresponding portion of the left posterior frontal lobe shows hypercellularity with plump and proliferating endothelial and smooth muscle cells. The adjacent neuropil is edematous. (Hematoxylin and eosin stain (H&E), $\times 40$.)

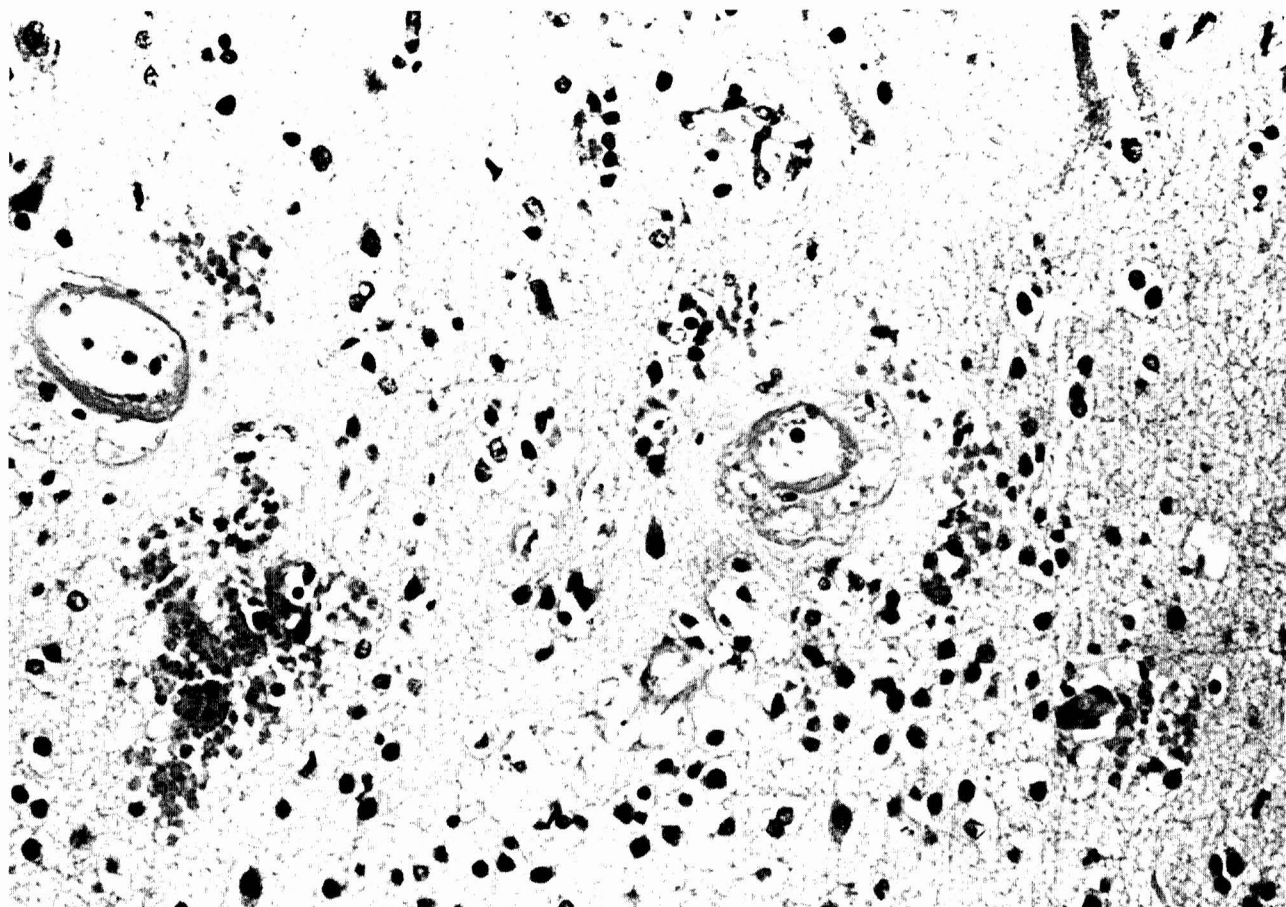


FIG. 7. Left parietal lobe shows fibrinoid necrosis of small blood vessels in association with extravasation of erythrocytes and marked edema of the neuropil. ($\times 25$.)

autoregulation is impaired and the arterial network in brain tissue remote from the fistula is chronically dilated (9). When normal perfusion is reestablished after removal of the fistula, the regulating capacity of the vessels is surpassed and they have no resistance to blood flow; because they cannot regulate to the new pressure, edema and hemorrhage result. Spetzler et al. termed this the normal perfusion pressure breakthrough theory.

Extrapolating from the analysis put forward by Spetzler et al., we propose that, because of chronic relative hypoperfusion of the hemisphere distal to a high grade carotid stenosis, small blood vessels remain maximally dilated to ensure maximal blood flow. The chronic vasodilatation results in loss of autoregulation. Upon correction of the high grade carotid stenosis, blood flow at a normal or elevated perfusion pressure is restored to the previously hypoperfused hemisphere. Because of paralyzed autoregulatory control, there cannot be sufficient vasoconstriction to protect the capillary bed, and "breakthrough" perfusion pressure results in edema and hemorrhage. Normal perfusion pressure breakthrough in a hypoperfused brain is also considered to be analogous to the hypertensive breakthrough that occurs in the brains of patients with malignant hypertension.

Unilateral headache not uncommonly occurs for a few days after endarterectomy. Messert and Black, in reviewing 50 consecutive patients after endarterectomy, noted severe hemispheric pain ipsilateral to the side of operation in 5 patients;

they attributed the pain to injury or manipulation of the carotid vessels or sheath (7). Leviton et al. reported 2 patients with severe unilateral headache after endarterectomy and attributed the headache to a transient disturbance in cerebral autoregulation (6). The latter explanation is also endorsed by Sundt et al., who found, in 6 patients with postoperative unilateral headache, an increase in cerebral blood flow from mean preoperative values of 43.2 ± 16 to 83.2 ± 39.8 ml/100 g/minute postoperatively (12).

Convulsions after carotid endarterectomy are uncommon. Wilkinson et al. reported focal convulsions in three patients 4 to 6 days after endarterectomy (14). All three patients had permanent neurological deficits after the onset of the seizures, and the authors concluded that the seizures were secondary to cerebral infarction caused by emboli from the endarterectomy site. Seizures were also reported at the onset of a fatal intracerebral hemorrhage following endarterectomy both by Caplan et al. (3) and by Bruetman et al. (2). Seizures occurring in the absence of postoperative cerebral infarction or occurring several days before a postendarterectomy intracerebral hemorrhage, as in our patient, were attributed to cerebral hyperperfusion and the early stages of hypertensive encephalopathy by Sundt et al. (10-12). Eleven of their patients developed seizures between the 5th and 7th postoperative day; their cerebral blood flows had increased from mean preoperative values of 37.3 ± 13.4 to 85.5 ± 31.8 ml/100 g/minute after operation (12).

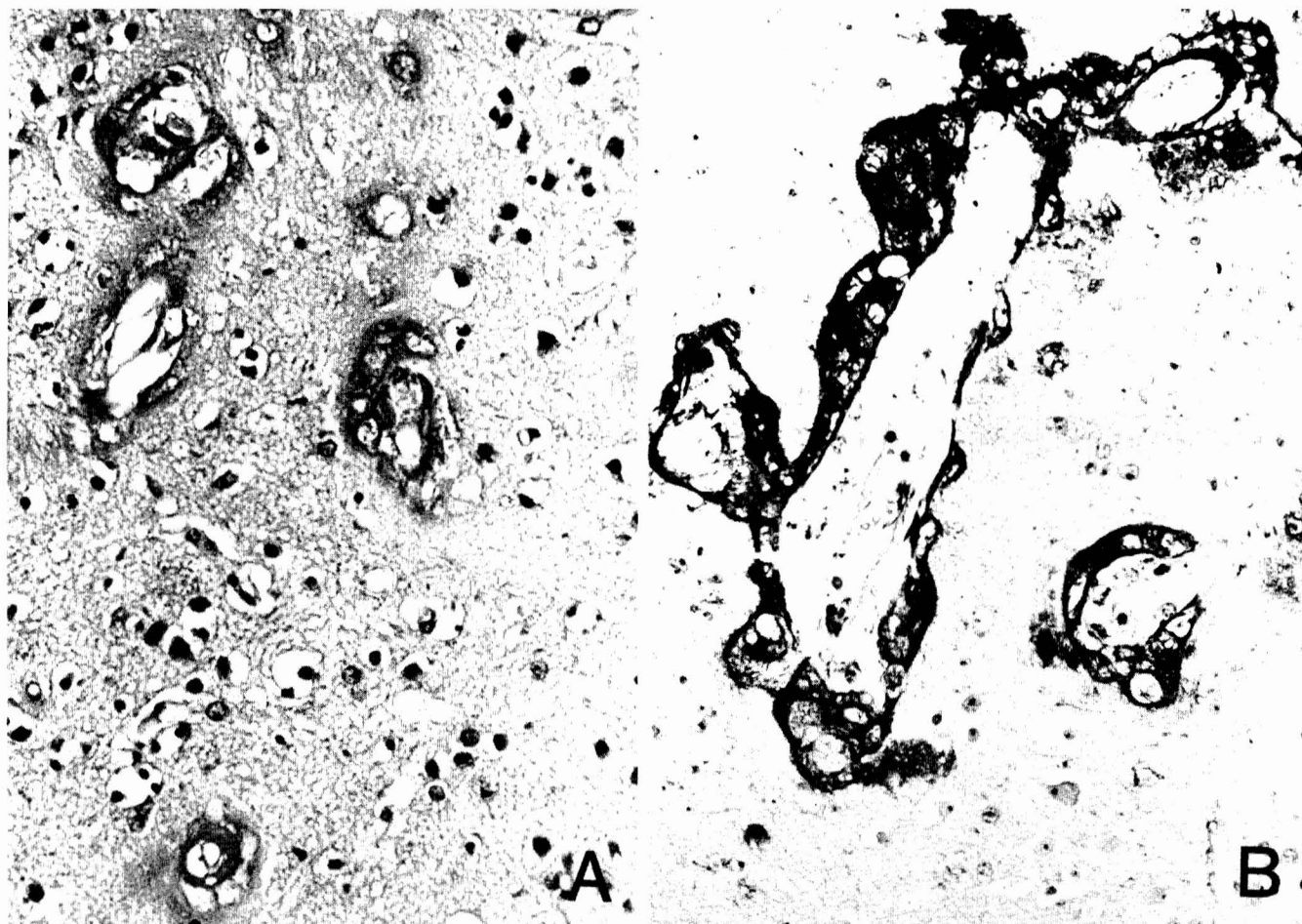


FIG. 8. Left parietal lobe shows marked edema of the neuropil (A) and fibrinoid necrosis of arterioles (B). (A, H&E; B, phosphotungstic acid-hematoxylin (PTAH) stain for fibrin; both, $\times 40$.)

Intracerebral hemorrhage occurring after carotid endarterectomy in the absence of predisposing factors, such as cerebral infarction, hypertension, or anticoagulants, is most likely related to cerebral hyperperfusion. Sundt et al. found that, in five patients who had a postoperative intracerebral hemorrhage, the cerebral blood flow had increased from a mean value of 29.6 ± 20 to 76.8 ± 18.5 ml/100 g/minute after endarterectomy (12). The "breakthrough bleeding" that occurs after the resection of some cerebral arteriovenous malformations almost certainly represents an analogous situation (9).

Our case is unique in that the clinical triad of unilateral head, face, and eye pain, seizures, and delayed intracerebral hemorrhage after endarterectomy has not hitherto been recorded in one patient. It is also unique because we were able to demonstrate pathological changes in the blood vessels of the affected cerebral hemisphere that are identical to those seen in malignant hypertension, thus providing histological evidence of the vascular reactivity to hyperperfusion that is the basis for the clinical picture.

Several therapeutic implications emerge from our study of this case. Correction of very high grade carotid stenosis may be especially dangerous if performed within 3 or 4 weeks of cerebral infarction, for there may be danger of hemorrhage into the softened brain parenchyma when the perfusion is increased. Uncontrolled hypertension after the correction of

very high grade carotid stenosis may be exceptionally hazardous because of increased risk of hemorrhage into the already hyperperfused brain in the absence of normal autoregulation. The occurrence of unilateral head, face, and eye pain or seizures after endarterectomy may reflect the development of a unilateral hyperperfusion syndrome and should signal a warning. Blood pressure should be diligently controlled in the face of such symptoms; anticoagulants and even platelet antiaggregants may increase the hazards, and their use should be avoided when these symptoms occur after endarterectomy.

Received for publication, January 3, 1984; accepted, March 10, 1984.

Reprint requests: Dr. J. F. Ross Fleming, 25 Leonard Avenue, Suite 207, Toronto, Ontario, Canada M5T 2R2.

REFERENCES

1. Bland JE, Chapman RD, Wylie EJ: Neurological complications of carotid artery surgery. *Ann Surg* 171:459-464, 1970.
2. Bruetman ME, Fields WS, Crawford ES, DeBakey ME: Cerebral hemorrhage in carotid artery surgery. *Arch Neurol* 9:458-467, 1963.
3. Caplan LR, Skillman J, Ojemann R, Fields WS: Intracerebral hemorrhage following carotid endarterectomy: A hypertensive complication? *Stroke* 9:457-460, 1978.
4. Hass WK, Clauss RH, Goldberg AF, Johnson AL, Imparato AM,

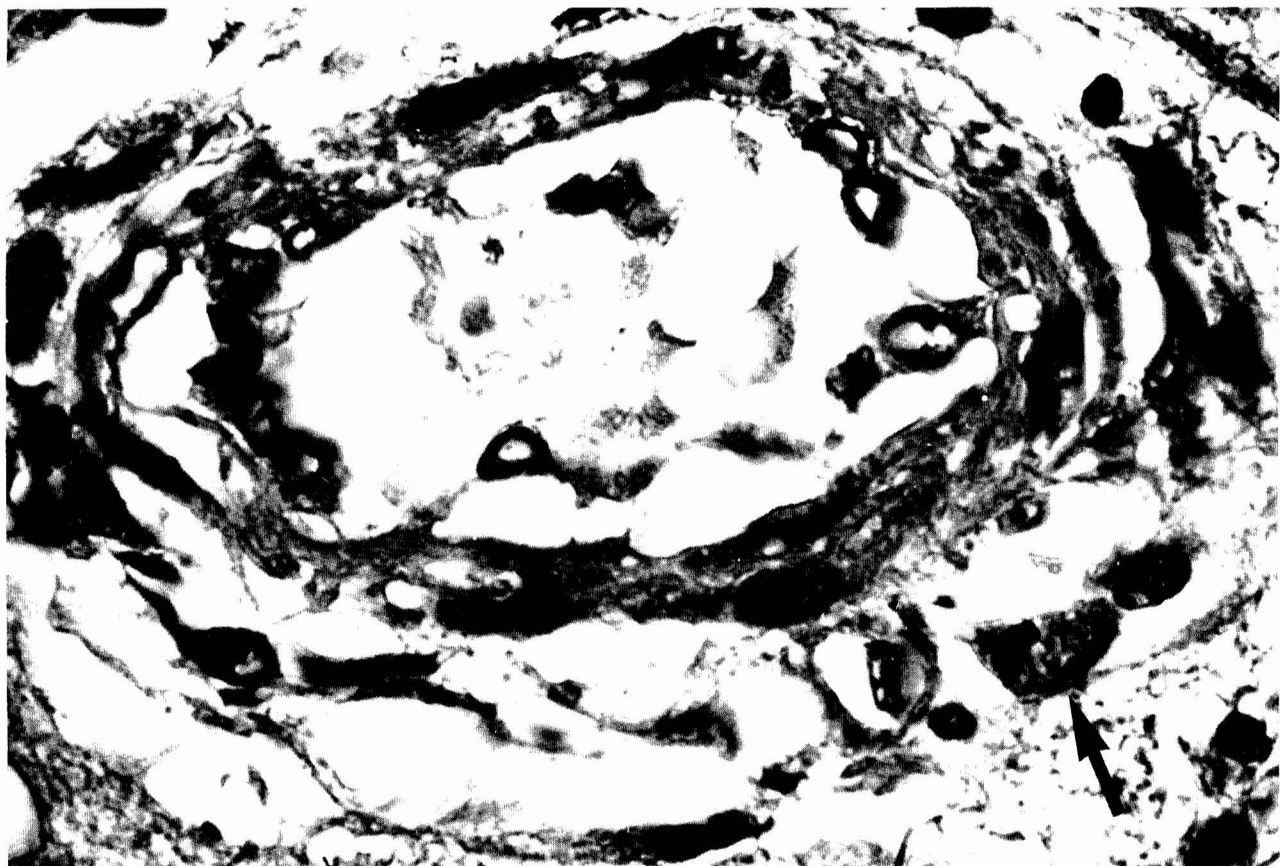


FIG. 9. Left parietal lobe shows marked hypercellularity of a small artery with a mitotic figure (arrow) in an adventitial cell, indicative of the reactive proliferative process. (H&E, $\times 40$.)

- Ransohoff J: Special problems associated with surgical and thrombolytic treatment of strokes. *Arch Surg* 92:27-31, 1966.
5. Lehv MS, Salzman EW, Silen W: Hypertension complicating carotid endarterectomy. *Stroke* 1:307-313, 1970.
 6. Leviton A, Caplan L, Salzman E: Severe headache after carotid endarterectomy. *Headache* 15:207-210, 1975.
 7. Messert B, Black JA: Cluster headache, hemicrania, and other head pains: Morbidity of carotid endarterectomy. *Stroke* 9:559-562, 1978.
 8. Ojemann RG, Crowell RM, Roberson GH, Fisher CM: Surgical treatment of extracranial carotid occlusive disease. *Clin Neurosurg* 22:214-263, 1975.
 9. Spetzler RF, Wilson CB, Weinstein P, Mehdorn M, Townsend J, Telles D: Normal perfusion pressure breakthrough theory. *Clin Neurosurg* 25:651-672, 1978.
 10. Sundt TM Jr: The ischemic tolerance of neural tissue and the need for monitoring and selective shunting during carotid endarterectomy. *Stroke* 14:93-98, 1983.
 11. Sundt TM Jr, Sandok BA, Whisnant JP: Carotid endarterectomy: Complications and preoperative assessment of risk. *Mayo Clin Proc* 50:301-306, 1975.
 12. Sundt TM Jr, Sharbrough FW, Piepgras DG, Kearns TP, Messick JM Jr, O'Fallon WM: Correlation of cerebral blood flow and electroencephalographic changes during carotid endarterectomy: With results of surgery and hemodynamics of cerebral ischemia. *Mayo Clin Proc* 56:533-543, 1981.
 13. Thompson JE: Complications of carotid endarterectomy and their prevention. *World J Surg* 3:155-165, 1979.
 14. Wilkinson JT, Adams HP Jr, Wright CB: Convulsions after carotid endarterectomy. *JAMA* 244:1827-1828, 1980.
 15. Wylie EJ, Hein MF, Adams JE: Intracranial hemorrhage following surgical revascularization for treatment of acute strokes. *J Neurosurg* 21:212-215, 1964.

COMMENT

This is a most interesting and instructive case. Surgeons who perform carotid endarterectomy have long appreciated that some patients complain of unilateral headache after the procedure. Most often, the headache is self-limited and disappears after some days or possibly several weeks. I personally have never seen a patient with cerebral hemorrhage after carotid endarterectomy unless the patient had sustained a recent cerebral infarction. This report shows that headache after carotid endarterectomy is not necessarily a benign condition and may occasionally herald a parenchymal brain hemorrhage.

The message seems to be that, if patients complain of severe headache after carotid endarterectomy, it may be prudent to treat the patient with antihypertensive drugs even if the blood pressure is in the normal range.

Russel H. Patterson, Jr., M.D.
New York, New York