

Ataxic Hemiparesis From Small Capsular Hemorrhage

Computed Tomography and Somatosensory Evoked Potentials

Etsuro Mori, MD; Atsushi Yamadori, MD; Yutaka Kudo, MD; Masayasu Tabuchi, MD

● We studied three cases that fit the clinical syndrome of ataxic hemiparesis. Computed tomography revealed small hemorrhages of the posterior limb of the internal capsule in all the cases, and somatosensory evoked potential studies predicted a disturbance of the lemniscal pathway from the thalamus to the parietal sensory cortex without demonstrable sensory loss. These results suggested that ataxia of the contralateral limbs following capsular lesion might result from a disruption of the thalamocortical sensory projection. The site of the lesion, the pathologic cause, and the underlying mechanism of ataxia are not necessarily homogeneous within the syndrome.

(*Arch Neurol* 1984;41:1050-1053)

Ataxic hemiparesis has been recognized as one of the classic forms of the lacunar syndrome.¹ In 1965, Fisher and Cole² described a peculiar form of the lacunar stroke in which the main feature was a combination of weakness and ataxia involving the limbs on the same side, affecting the leg more than the arm. Subsequently, Fisher³ performed pathologic examinations of three cases of the syndrome that each revealed a lesion in the upper basis pontis, contralateral to both the pyramidal and the cerebellar

signs, and named the syndrome ataxic hemiparesis. More recently, there have been several reports of this syndrome (confirmed by computed tomography [CT]) in which the lesion involved the posterior limb of the internal capsule and the corona radiata, instead of the basis pontis. The name capsular ataxic hemiparesis has been suggested for this syndrome.⁴⁻¹⁰ Originally, Fisher and Cole² tentatively located the lesion in the posterior capsular-corona radiata that caused ataxic hemiparesis; it was also known to cause other types of lacunar syndromes.¹ To our knowledge, there are no reports of that syndrome due to a capsular hemorrhagic lesion. We described three cases of ataxic hemiparesis that resulted from hemorrhages in the posterior limb of the internal capsule that were confirmed by CT. In addition, somatosensory evoked potentials (SEPs) provided other information on the pathogenetic mechanism of the contralateral ataxia.

REPORT OF CASES

CASE 1.—A 78-year-old hypertensive man who was without prior strokes experienced sudden light-headedness and right-sided weakness one week before admission to our hospital. He was unable to stand without support and noticed that the right side of his face and his left hand and foot were numb. There was no nausea, vomiting, or dysphasia. He was admitted to an emergency hospital and was transferred to our hospital one week later for further treatment. His condition had improved slightly on admission to our hospital. The

results of a general physical examination were normal; his BP was 150/100 mm Hg. The neurologic examination showed that the patient was fully alert and oriented. There was no aphasia. The only abnormalities of cranial nerve function were right hemifacial hypoesthesia and difficulty in peripheral hearing. There was weakness of the right extremities that was much more severe in the leg. The strength was reduced to 4/5 in the right upper extremity and in the hip and the knee of the right leg. At the right ankle, the dorsiflexion strength was 2/5 and the plantar flexion strength was 3/5. The tone was slightly decreased on the right side. The tendon reflexes were almost symmetric but the plantar response was extensor on the right side. On the finger-nose and heel-knee-shin tests there was a moderate ataxia on the right side, that was more apparent in the arm than in the leg. Rapid alternating movements were clumsy on the right side, with a marked rebound phenomenon. The intensity of ataxia was not increased when the eyes were closed. The sensory examination showed that the pinprick, touch, and vibration senses were slightly diminished in the right hand, and that the position sense was absent from the right fingers. The patient's graphesthesia was normal, but two-point discrimination and stereognosis was impaired in the right hand. The sensation in the right leg was normal.

The patient showed gradual improvement in his right limb power. However, the ataxia became more outstanding during the next two weeks. An examination one month later showed normal strength of the right upper and lower extremities except for the peroneus muscle, which remained at a strength of 4/5. The ataxia in the right limbs, however, remained almost unchanged. All of the sensory impairment, except for the paresthesia in the right

Accepted for publication Oct 23, 1983.
From the Neurology Service, Hyogo Brain and Heart Center, Himeji, Japan.
Reprint requests to Neurology Service, Hyogo Brain and Heart Center at Himeji, 520 Saisho-Ko, Himeji, 670 Japan (Dr Mori).

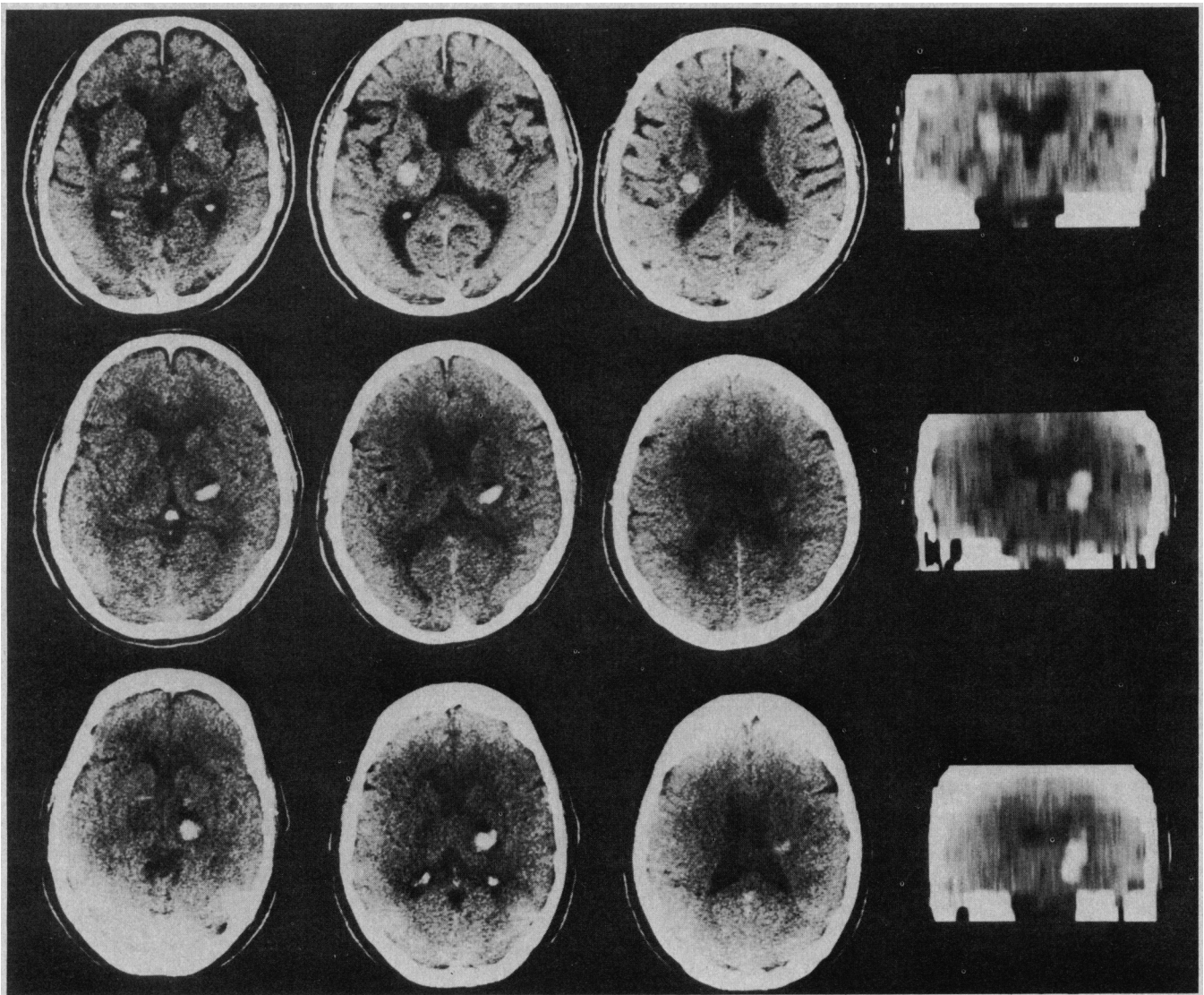


Fig 1.—Computed tomographic sections and coronal reconstruction. Top, Case 1; center, case 2; and bottom, case 3. Small hemorrhage is located posterior to center of posterior limb of internal capsule and corona radiata.

hand and right perioral region, improved.

CASE 2.—A 50-year-old, hypertensive man experienced sudden numbness and clumsiness of the left arm when he was in the toilet four hours before admission. He was unable to stand up and walk without support. There was no headache, nausea, or vomiting. On admission, the patient was fully alert and intelligent. The general physical examination revealed a BP of 160/100 mm Hg but was otherwise unremarkable. A neurologic examination showed that the cranial nerve functions were intact except for the left hemifacial sensory loss. The power in the left upper extremity was almost normal, with questionable weakness in the shoulder. The strength in the left lower extremity was reduced to 4/5 except for the peroneal muscle, which showed a strength of 3/5. The tone was slightly reduced in the left side. The tendon reflexes were symmetric but the plantar response was extensor on the left. The finger-nose and heel-knee-

shin tests revealed an intention tremor and marked dysmetria, and rapid alternating movements were slow and clumsy on the left side. There was also an exaggerated rebound phenomenon on that side. Eye closure did not influence the intensity of the ataxia. Pinprick, light-touch, and vibration sensations were slightly decreased on the left side of the face and the left arm and leg. The position sense was slightly diminished in the left arm and leg and was almost absent from the fingers and toes. Graphesthesia, two-point discrimination, and the double simultaneous stimulation sense were preserved, but stereognosis was severely impaired in the left hand.

The weakness and sensory impairment gradually improved during the next two weeks. An examination two weeks later showed normal muscle strength. All the sensory deficits had subsided completely, although the patient complained of paresthetic sensations in the left hand and the

left perioral area. The patient was able to walk easily when using a cane. The ataxia in the left limbs, however, improved only slightly and even three months later it persisted, with some improvement.

CASE 3.—A 70-year-old woman experienced the sudden onset of left-sided weakness seven hours before admission. She had been treated for hypertension and asthma and had suffered from the exacerbation of an asthmatic attack two days before the incident. There was no headache, nausea or vomiting. The general physical examination demonstrated a BP of 170/100 mm Hg and dry rales that were audible over both lung bases. The patient appeared to be well with intact cognitive functions, but she had mild dysarthric speech. The deficit was confined to a left-sided sensorimotor abnormality. There was little spontaneous movement in the left upper and lower extremities. Pinprick, touch, and vibration sensations were moderately decreased on the left side of the

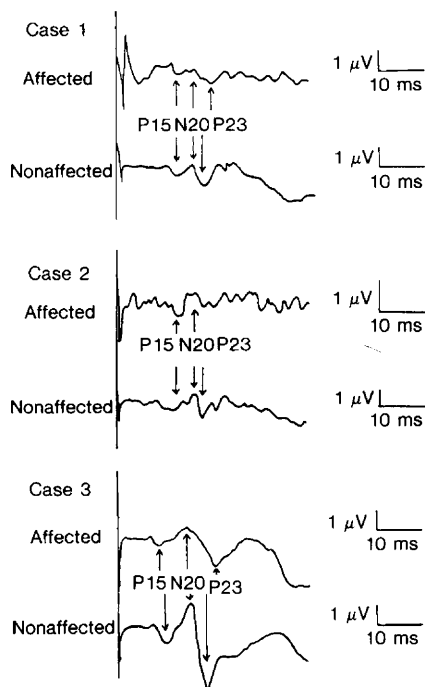


Fig 2.—Parietal-recorded somatosensory evoked potentials following contralateral median nerve stimulation. Note normal P15, attenuation of N20 with normal interpeak latency of P15 to N20, and prolonged interpeak latency of N20 to P23 (cases 1 and 3) or complete abolition of P23 (case 2), recorded on side with lesion after stimulation of affected limb.

body. There was no detection of passive movement of the left finger joints and diminished detection of passive movement in the left wrist. The stretch reflexes were increased on the left side and the plantar response was extensor on that side. The left limbs showed hypotonia. By the following day, the left-sided weakness had improved slightly and some movements of the left upper limb reappeared; they were stronger in the distal than in the proximal portion of the limb. As the weakness improved, the left upper limb ataxia stood out. Muscle testing one month later revealed the left-sided weakness, with strength at the upper limb of 4/5, at the hip and knee of 3/5, and at the ankle of 2/5. On the finger-nose test there was a marked dysmetria and an intention tremor of the cerebellar type, although there was sufficient power to carry out the test. Wild oscillatory movements of the left hand on that test frequently caused the patient to strike her own eyes. Her stretched left arm swayed from side to side. Rapid alternating movements were clumsy and slow on that side. There was a marked rebound phenomenon in the left arm. The heel-knee-shin test was not performed well because of the weakness. A sensory examination demonstrated a slight hypoaesthesia to pinprick and light-touch sensations on the left side, and the patient complained of a tingling sensation in the left hand and perioral region. The position sense re-

turned to normal. The patient could walk with a cane and a brace.

RESULTS

Computed tomographic scans of the brain were performed on admission in all three patients. In each case, a well-defined, small, high-density, area, consistent with acute hemorrhage, was demonstrated in the posterior limb of the internal capsule and caudal portion of the corona radiata. The lesion was predominantly located posterior to the center of the posterior limb. A zone of hypodensity surrounding the high-density area that was consistent with focal edema was demonstrated in each case. The dimensions of the area of hyperdensity were 10 (transverse) \times 10 (longitudinal) \times 20 (vertical) mm in case 1, 12 \times 8 \times 20 mm in case 2, and 12 \times 10 \times 25 mm in case 3. The hemorrhagic lesion extended medially, possibly involving the most lateral portion of the thalamus. The lesion in each case was situated predominantly in the rostral portion of the posterior limb of the internal capsule, although the lesion in case 3 extended caudally, probably reaching the uppermost part of the cerebral peduncle (Fig 1).

The SEPs in response to median-nerve stimulation were studied three weeks (in cases 1 and 2) or two months (in case 3) after the onset of the illness. When the SEPs were recorded, although numbness in the hand and perioral area was present, objectively demonstrable sensory deficits were absent or minimal. The SEPs were elicited by 0.2-ms electric square-wave pulses that were delivered to the median nerve at the wrist through two surface electrodes at a frequency of 2 Hz and an intensity that was 10% above the motor threshold. The brain potentials were amplified and 500 to 1,000 samples were averaged during an analysis time of 50 ms. The activities were recorded at a site on the scalp 2 cm behind C_z and 7 cm from the midline, contralateral to the stimulated side, using interconnected earlobe electrodes as a reference. Simultaneously, a brachial plexus component from Erb's point was registered to allow precise measurement of the central conduction times. The test was repeated at least once to verify the waveforms. The changes in the SEPs that were observed following stimulation of the affected side were characterized by normal P15 potentials, a decreased N20 amplitude with a normal interpeak latency from P15 to N20, compared with those of the opposite (nonaffected) side, and a pro-

longed interpeak latency from N20 to P23, compared with that of the opposite side (in cases 1 and 3), or complete abolition of P23 and the later potentials (case 2) (Fig 2).

COMMENT

Ataxic hemiparesis is still somewhat controversial. The first issue is whether ataxic hemiparesis is a pathognomonic sign of lacunar infarction or not. Several reports of pure motor hemiparesis, another classic lacunar syndrome, have suggested that various causes are present in this syndrome, such as cortical infarction, brain tumor, multiple sclerosis, chronic subdural hematoma, and intracerebral hemorrhage.¹¹⁻¹³ Recently, Miller¹⁴ reviewed lacunar stroke and suggested that lacunar syndromes have pathologic heterogeneity. Although there are several descriptions of hemorrhagic lesions causing classic lacunar syndromes, eg, pure motor hemiparesis,^{12,13} pure sensory stroke,^{15,16} dysarthria-clumsy hand syndrome,¹⁷ and "pontine" ataxic hemiparesis,¹⁸ this is, to our knowledge, the first report of capsular ataxic hemiparesis due to hemorrhage.

The second issue is whether sensory impairment coexists with ataxic hemiparesis. In Fisher and Cole's original article, they reported that eight of 14 cases had paresthesia and that some cases demonstrated some objective sensory loss.² However, Fisher stated, in a second report of three cases of pontine ataxic hemiparesis that were studied pathologically, that there was no numbness or sensory loss.³ In his latest review of lacunar stroke, Fisher reported that at the onset, there often is numbness without a demonstrable sensory deficit.¹ In recent case reports of ataxic hemiparesis, the patient's sensory functions ranged from normal to moderately impaired.^{4,7} Therefore, in our opinion, the coexistence of sensory deficits would not prevent the physician from diagnosing ataxic hemiparesis. A review of our cases and previously reported ones has caused us to reach the following conclusion: patients with capsular ataxic hemiparesis are apt to have a sensory loss, while those patients with hemiparesis resulting from a pontine lesion do not.^{3,17-19} Even if sensory deficits cannot be demonstrated, subclinical sensory involvement might be disclosed by measuring the SEPs, as in our patients. Chokroverty and Rubino¹¹ studied 15 patients who had pure motor hemiparesis and found subclinical sensory involvement

in seven patients by studying the SEPs as well.

The problems of the site of the lesion responsible for ataxic hemiparesis and the pathogenesis of contralateral ataxia have been discussed since Fisher and Cole described this syndrome. The junction of the third and medial segments of the contralateral basis pontis,³ the contralateral rostral midbrain,²⁰ and the superior part of the posterior limb of the contralateral internal capsule⁴⁻¹⁰ were proposed as the responsible lesions. The present cases are consistent with the last proposal. It has been suggested that the corticospinal fibers are organized in a somatotopic arrangement within the anterior third quarter of the posterior limb of the internal capsule, so that those fibers concerned with the lower extremity are arranged most posteriorly,²¹ and that the sensory thalamocortical radiation lies further posterior than the corticospinal fibers.¹⁵ According to this theory, the fact that all of our patients demonstrated both hemiparesis predominantly affecting the leg and sensory impairment indicated that those lesions were situated in the posterior half of the posterior limb, an indication that was supported by the CT findings.

It had been postulated that the contralateral ataxia resulting from a cap-

sular lesion was caused by an interruption of the corticopontine fibers passing from the precentral cortex through the posterior capsular region to the pontine nuclei,^{2,5-8} or by an interruption of the reciprocal fiber connection between the ventrolateral thalamic nucleus and the precentral area passing through the superior portion of the posterior limb of the internal capsule.^{6,7} However, it has also been suggested that a lesion of the ventral posterolateral nucleus of the thalamus²² or a lesion of the parietal sensory cortex^{22,23} can cause ataxia similar to that caused by cerebellar disease in the contralateral limbs. Lesions such as the ones we and others detected in the internal capsule by CT might also involve the ventral posterolateral thalamic nucleus itself, and/or its radiation, which occupy the posterior quarter of the posterior limb adjacent to the thalamus. Abnormal SEPs indicated that subclinical sensory impairment resulting from interruption of the lemniscal pathway remained even after the demonstrable sensory loss disappeared. The abnormalities of the N20 potentials, which are believed to be generated in the thalamus or its projecting pathway,^{24,25} and the abnormalities of the P23 potentials, which, it is generally agreed, originate in the parietal sensory cortex,²⁵ would indicate the dis-

ruption of the thalamic sensory nucleus and/or the thalamocortical sensory projection. Thus, clinical and subclinical proprioceptive deficits are a possible cause of the ataxia in the present cases. In addition to the involvement of the corticopontine fibers and the ventrolateral nucleus-precentral cortex connection, we present this hypothesis as a mechanism of the ataxia resulting from a capsular lesion.

In conclusion, the syndrome of ataxic hemiparesis is a useful nosologic description of an unusual combination of ipsilateral corticospinal and cerebellar signs; however, it includes some problems concerning pathologic heterogeneity, semiologic diversity, the variety of the responsible lesion, and the complex mechanism of the contralateral ataxia. Our cases emphasize that a small capsular hemorrhage must be considered in the differential diagnosis of ataxic hemiparesis, although there is little doubt that in many patients, ataxic hemiparesis is due to a lacunar infarction in the basis pontis or the internal capsule. A further investigation with physiologic and pathologic studies is indicated to clarify the clinical, physiologic, and pathologic correlation of capsular disease.

References

1. Fisher CM: Lacunar strokes and infarcts: A review. *Neurology* 1982;32:871-876.
2. Fisher CM, Cole M: Homolateral ataxia and crural paresis: A vascular syndrome. *J Neurol Neurosurg Psychiatry* 1965;28:48-55.
3. Fisher CM: Ataxic hemiparesis: A pathologic study. *Arch Neurol* 1978;35:126-128.
4. Perman GP, Racy A: Homolateral ataxia and crural paresis: Case report. *Neurology* 1980;30:1013-1015.
5. Iragui VJ, McCutchen CB: Capsular ataxic hemiparesis. *Arch Neurol* 1982;39:528-529.
6. Ichikawa K, Tsutsumishita AS, Fujioka A: Capsular ataxic hemiparesis. *Arch Neurol* 1982;39:585-586.
7. De Renzi E, Nichelli P, Crisi G: Hemiataxia and crural hemiparesis following capsular infarct. *J Neurol Neurosurg Psychiatry* 1983;46:561-563.
8. Sage JI, Lepore FE: Ataxic hemiparesis from lesions of the corona radiata. *Arch Neurol* 1983;40:449-450.
9. Weisberg LA: Lacunar infarcts. *Arch Neurol* 1982;39:37-40.
10. Donnan GA, Tress BM, Bladin PF: A prospective study of lacunar infarction using computerized tomography. *Neurology* 1982;32:49-56.
11. Chokroverty S, Rubino FA: 'Pure' motor hemiplegia. *J Neurol Neurosurg Psychiatry* 1975;38:869-899.
12. Weisberg LA: Computed tomography and pure motor hemiparesis. *Neurology* 1979;29:490-495.
13. Nelson RF, Pullicino P, Kendall BE, et al: Computed tomography in patients presenting with lacunar syndromes. *Stroke* 1980;11:256-261.
14. Miller VT: Lacunar stroke: A reassessment. *Arch Neurol* 1983;40:129-134.
15. Groothuis DR, Duncan GW, Fisher CM: The human thalamocortical sensory path in the internal capsule: Evidence from a small capsular hemorrhage causing a pure sensory stroke. *Ann Neurol* 1977;2:323-331.
16. Rosenberg NL, Koller R: Computed tomography and pure sensory stroke. *Neurology* 1981;31:217-220.
17. Tuhim S, Yang WC, Rubinowitz H, et al: Primary pontine hemorrhage and the dysarthria-clumsy hand syndrome. *Neurology* 1982;32:1027-1028.
18. Schnapper RA: Pontine hemorrhage presenting as ataxic hemiparesis. *Stroke* 1982;13:518-519.
19. Sakai T, Murakami S, Ito K: Ataxic hemiparesis with trigeminal weakness. *Neurology* 1981;31:635-636.
20. Bendheim PE, Berg BO: Ataxic hemiparesis from a midline mass. *Ann Neurol* 1981;9:405-407.
21. Fisher CM, Curry HB: Pure motor hemiplegia of vascular origin. *Arch Neurol* 1965;13:30-44.
22. Garcin R: The ataxias, in Vinken PJ, Bruyn GW (eds): *Handbook of Clinical Neurology*. Amsterdam, North-Holland Publishing Co, 1969, vol 1: *Disturbance of Nervous Function*, pp 309-355.
23. Appenzeller O, Hanson JC: Parietal ataxia. *Arch Neurol* 1966;15:264-269.
24. Mauguière F, Courjon J: The origins of short-latency somatosensory evoked potentials in humans. *Ann Neurol* 1981;9:607-611.
25. Chiappa KH, Ropper AH: Evoked potentials in clinical medicine. *N Engl J Med* 1982;306:1205-1211.