

- * D'Alonzo AJ, McArdle JJ. An evaluation of fast and slow twitch muscle from rats treated with 20,25-diazacholesterol. *Exp Neurol* 1982; **78**:46-66.
- * DeCoursey TE. Sodium currents in normal and myotonic muscle fibers. Ph.D. Dissertation, University of Cincinnati, 1979.
- ¹⁰ Hille B, Campbell DT. An improved vaseline gap voltage clamp for skeletal muscle. *J Gen Physiol* 1976; **67**:265-93.

Pontine ataxic hemiparesis, a lateral penetrator syndrome?

Sir: Ataxic-hemiparesis due to a pontine lesion was first described in post mortem studies by Fisher.¹ Since then, most studies using computed tomography have reported internal capsule lesions in ataxic hemiparesis. Only one previous case of brainstem infarct has been documented with computed tomography.² We wish to describe a second case.

A 52-year old Chinese female had a known history of diabetes mellitus and hypertension under treatment. She was admitted to hospital because of sudden onset of left sided weakness. There was no diplopia, vertigo, or other symptoms. On examination she had a blood pressure of 130/70 mm Hg. There was grade 3 power in the left upper limb, and grade 4 in the left lower limb. The reflexes were exaggerated on the left, Babinski's sign was absent. Marked cerebellar incoordination, and dysidiadochokinesia was noted in the left upper and lower limbs. There was no cranial nerve abnormality, nor any sensory loss. Somatosensory evoked responses to median and tibial nerve stimulation was normal. CT scan showed a low density area in the right pons (fig). She improved progressively but 3 months later was still ataxic whilst having normal power and exaggerated tendon reflexes on the left side.

We have recently reported four cases of ataxic hemiparesis due to internal capsule and corona radiata infarction.³ These cases, as well as similar cases in the literature all had sensory impairment. In contrast, all ataxic hemiparesis cases due to brainstem lesions reported so far have had normal sensory findings. We postulated that the supratentorial cases could be separated, from brainstem cases by the absence of cranial neuropathy, nystagmus, dysarthria, and the presence of sensory impairment. The present case of pontine infarct supports our previous contention in that there was no clinical evidence of sensory impairment and somatosensory evoked responses was normal. Clinical recognition

of the difference may have more than casual interest, since ataxic-hemiparesis due to non-ischaemic lesions have all been situated in the brainstem.⁴⁻⁶

Fisher had previously demonstrated three cases of ataxic hemiparesis associated with infarcts in the brainstem.¹ All the infarcts were in the junction of the upper third and lower two-thirds of the basis pontis. Two of the cases had midline infarct cavities, and one had a more laterally situated infarct. The basilar artery was patent in all three cases, but a plaque was found in a branch artery in one case. Sakai *et al* reported a case with an infarct in the ventromedian aspect of the pons.² Their case had also trigeminal weakness, suggesting that the lesion extended further laterally, and they thought a short circumferential branch rather than a median penetrating artery was likely to have been involved. The present case showed a lesion in the ventrolateral aspect of the pons.

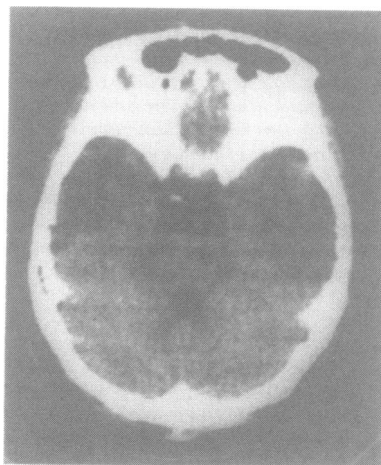


Fig Unenhanced scan showing a small low density area in the ventrolateral aspect of right pons.

Four cases of pontine haemorrhages causing ataxic hemiparesis also have been reported.^{5,6} These have all been small haematomas in the dorsolateral aspects of the pons. They did not exhibit features of lateral tegmental brainstem haemorrhage: all radiologically or pathologically confirmed cases had spinothalamic involvement, and frequently also eye movement disorders.⁷ Ataxia in lateral tegmental brainstem haemorrhage was also bilateral or contralateral to the weakness. The brainstem receives blood supply from

paramedian arteries arising directly from the basilar artery, and a series of lateral penetrators from short circumferential branches of the basilar artery. In addition, branches from the long circumferential arteries supply parts of the lateral tegmentum.⁸ Both the pyramidal tract and medial lemniscus lie in the territory of the paramedian penetrators. It seems more likely therefore that the brainstem haemorrhage causing ataxic hemiparesis had been in the lateral penetrator territory. Fisher's case 1, Sakai's case, and the current case, seem to have also lesions in the lateral penetrator rather than paramedian territory. Pontine ataxic hemiparesis, whether ischaemic or haemorrhagic in origin may simply be a pontine lateral penetrator territory syndrome.

Paramedian territory infarcts, unless limited, probably give rise to such significant hemiparesis that ataxia cannot be observed. Fisher's two other cases may have been exceptional examples of such limited paramedian infarcts. However the acute ischaemia could have extended more laterally.

Fisher had speculated that in addition to involvement of the corticospinal tract, the pontine nuclei sending fibres to the opposite cerebellar hemisphere, or the crossing fibres from the opposite pontine nuclei, had to be involved to cause ataxia. It was unclear why the cerebellar signs were not bilateral. However, in his three cases, the infarcts were all described as extending only 5-7.5 mm in the anterior posterior direction. Our case had an infarct which was seen only on one CT slice. It is possible that crossing fibres from the pontine nuclei travel obliquely in the rostral caudal plane, so that a lesion limited in this plane, may affect only the pyramidal tract and pontine nuclei, and spare the contralateral crossing fibres, thus giving rise to homolateral ataxic hemiparesis. However the pontine nuclei are themselves aggregated in longitudinal columns in the rostral caudal direction,⁹ so that a small lesion may be expected also not to affect the nuclei or their projections significantly. On the other hand, the corticopontine fibres descend with the corticospinal tracts, to terminate in the ipsilateral pontine nuclei. Ataxia could conceivably result from a critical lesion in the upper pons which interrupted both the corticopontine and corticospinal projections, without necessarily affecting the pontine nuclei or its projections.

CY HUANG,
KH CHAN,

Department of Medicine,

University of Hong Kong,
Queen Mary Hospital,
Hong Kong.

References

- ¹ Fisher CM. Ataxia hemiparesis: a pathologic study. *Arch Neurol* 1978;35:126-8.
- ² Sakai T, Murakami S, Ito K. Ataxia hemiparesis with trigeminal weakness. *Neurology (NY)* 1981;31:635-6.
- ³ Huang CY, Lui FS. Ataxic-hemiparesis, localization and clinical features. *Stroke* 1984;15(2):in press.
- ⁴ Bendheim PE, Berg BO. Ataxia hemiparesis from a midbrain mass. *Ann Neurol* 1981;9:405-7.
- ⁵ Lee KY, Lie SK, Chiang TR. Small intracerebral hemorrhage clinically simulating lacunar infarction. *Journal of the Formosan Medical Association* 1983;82(9):993-1000.
- ⁶ Schnapper RA. Pontine hemorrhage presenting as ataxic hemiparesis. *Stroke* 1982;13:518-9.
- ⁷ Caplan LR, Goodwin JA. Lateral segmental brainstem haemorrhage. *Neurology (NY)* 1982;32:252-60.
- ⁸ Stephens R, Stillwell D. In: Charles C, ed. *Arteries and Veins of the Human brain*. Springfield: Thomas, 1969.
- ⁹ Brodal A. *Neurological Anatomy, in relation to Clinical Medicine*. New York OUP, 1981.

Accepted 24 March 1984

Giant global intracranial aneurysm in an infant

Sir: Nonthrombosed giant global aneurysms rarely occur in the cerebral vessels and seem to be unrelated to saccular aneurysms. They usually arise from the larger cerebral arteries and rarely rupture; instead, they present as a space-occupying lesion.^{1,2} Giant intracranial aneurysm has a characteristic diagnostic computed tomography (CT) appearance.³ The symptoms and signs are those of an expanding intracranial mass and cardiac failure, rather than those of subarachnoid hemorrhage. We report an infant with a giant global aneurysm of the middle cerebral artery which compressed adjacent brain tissue causing hemiparesis and cardiac failure.

A 10-month-old boy was admitted to hospital in November, 1981, with symptoms of nausea, vomiting and right-sided spastic weakness of 3 months duration. He was born at the end of the 38th week of gestation after an uneventful pregnancy and a normal delivery. Family history was not significant. The child had shown congestive heart failure for one month after birth. Development was generally delayed

and the infant often manifested cyanosis and respiratory difficulty on crying until 3 months after birth. The right side of the extremity has moved less well than the left since 3 months of age and there was steady enlargement of head. At the age of 10 months, he became irritable with enlarged head and increased weakness of the right extremity and was transferred to our hospital. On admission, physical examination revealed an alert and fairly nourished baby. Growth and development were delayed. The cranial circumference was over 95 percentile and the fontanels were bulging. There was no audible intracranial bruit. Visual acuity was not impaired, extraocular movements were normal and the other cranial nerves were also intact. A spastic right hemiparesis with exaggerated deep tendon reflexes and Babinski sign were present. Cerebellar functions were normal. The CT scan demonstrated a large round mass with a density greater than that of the brain in the right temporal fossa, and the mass measured 6 × 5 cm in size. Following contrast enhancement the density of the mass increased markedly, and a homogeneous round mass without perifocal oedema was seen (fig). The mass compressed the left lateral ventricle and the midline was shifted to the right. Carotid angiography showed a large global aneurysm arising from a branch of the right middle cerebral artery, and the aneurysm was situated in the sylvian region.

A right frontotemporal craniotomy was performed. A part of the aneurysm was exposed on the cortex and a corticotomy was performed on the surface of the aneurysm. A large global aneurysm with smooth, purple-reddish wall was encountered at a depth of 1.5 cm and it extended

subcortically into the frontal, parietal and temporal opercular areas. The aneurysm was completely resected under induced hypotension after ligation of the dilated parent artery, which was a branch originating from bifurcation of the middle cerebral artery. Postoperative angiogram revealed a complete extirpation of the aneurysm.

At examination 3 months later, the baby was in good condition. There was no evidence of cardiac failure. The right hemiparesis was gradually improving and he was able to walk without support.

Adams and Richardson⁴ postulated that the giant aneurysm is different from the saccular aneurysm because of its larger size, different location, and clinical manifestation related to its space-occupying nature. Giant aneurysms make up 5% of all intracranial aneurysms⁵ and are frequently found at the cavernous portion or bifurcation of the internal carotid artery, middle cerebral artery, basilar artery and vertebral basilar artery junction.^{6,7}

Giant aneurysms of global type from the middle cerebral artery cause neurological pictures by at least two mechanisms; local pressure and distal ischaemia caused by arterial steal. These aneurysms have most often shown evidence of an expanding mass effect rather than of a subarachnoid haemorrhage. A considerable volume of blood flows through the aneurysm and may deprive blood flow from the adjacent brain. On the other hand the aneurysms may enlarge to some extent, then progressive thrombosis may take place in the sac. In this situation, with progressive narrowing of the vascular channel in the lumen of the aneurysm, ischaemia may result in the territory of the parent artery. Neurological deficit of this case may have resulted from

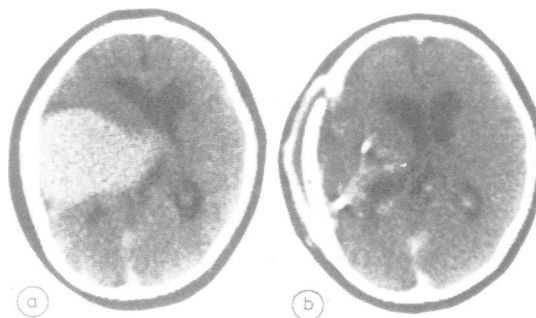


Fig 1 Postcontrast enhanced CT scans show a well circumscribed, enhancing giant aneurysm in left sylvian area (A) and restoration of the lateral ventricle to normal position following operation (B).