

# Delayed Onset Dystonia Following Hemiplegic Migraine

J.A. Obeso, E. Martinez Vila, G. Delgado, J. Vaamonde, E. Maravi, J.M. Martinez Lage

From the Movement Disorders Unit, Department of Neurology, Clinica Universitaria, University of Navarra Medical School, Pamplona, Spain.

Reprint requests to: Dr. J.A. Obeso, Neurologia, Clinica Universitaria, Apdo. 192, Pamplona, Spain.

Accepted for Publication: October 20, 1983

## SYNOPSIS

A 22-year-old woman developed complete left hemiplegia and sensory loss during an attack of migraine. She recovered almost totally but two months later incoordination and twisting of the left limb was noticeable. Examination showed tremor of the left arm and dystonia of the hand and foot secondary to a small infarction of the right posterolateral thalamic nuclei. Late onset dystonia may be another sequela of complicated migraine.

(*Headache* 24:266-268, 1984)

Permanent hemiplegia as a consequence of complicated migraine is uncommon.<sup>1,2,3</sup> Although late development of involuntary movements is known to occur after hemiplegia,<sup>4,5</sup> delayed-onset dystonia secondary to hemiplegic migraine seems to be extremely rare.<sup>6</sup> This report concerns a patient with such unusual combination associated with a small infarction in the contralateral postero-lateral thalamic nuclei.

## CASE REPORT

A 22-year-old woman developed a left hemiplegia in November 1981 during an episode of migraine lateralized to the right side of her head. She had been pregnant for 5 months and had a previous history of migraine. The initial neurological examination revealed complete hemiplegia and sensory loss on the left. Visual fields were normal. Detailed cardiovascular examinations, including EKG and echocardiography, were normal. CT showed a large area of low density affecting the right postero-lateral thalamus, internal capsule and striatum (figure, I-A). The patient recovered motor power almost completely within a week after the complicated migraine and only a minimal hypoesthesia of the finger tips could be detected on sensory examination. She complained of a sharpening pain and a feeling of burning on the left arm which was mainly provoked by light touch of this extremity.

Mobility returned to normal over the following two months and the disaesthetic sensations disappeared. She had a normal delivery. However, a progressive difficulty in controlling the right arm and a tendency of the right foot to twist had become noticeable just before delivery. Ten months after the acute episode,

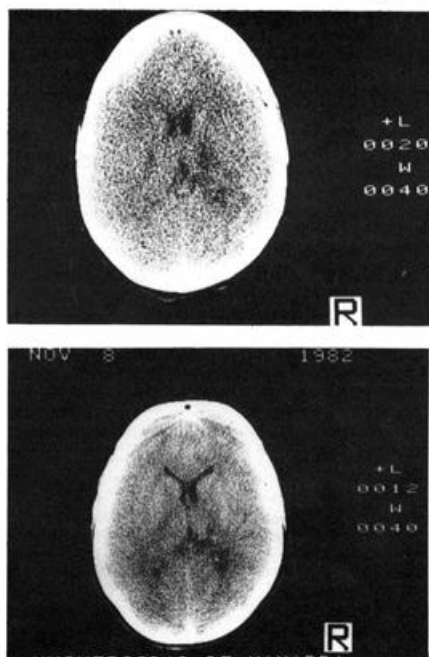


Fig 1.—A. CT Scan taken 24 hours after the initiation of symptoms. Large patchy area of low density affecting putamen, internal capsule and postero-lateral thalamic nuclei on the right hemisphere are present. B. CT Scan taken 10 months after the episode of complicated migraine. A small low density area restricted to the right postero-lateral thalamic nuclei is observed.

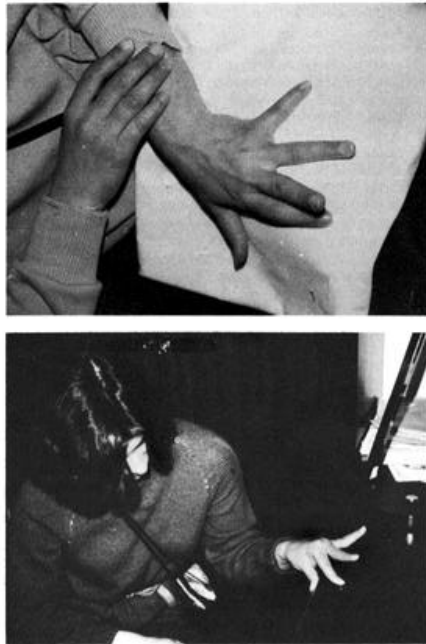

Fig 2.—A. Ulnar deviation of the wrist and athetosis of the fingers. B. Severe impairment of left arm coordination due to tremor and dystonia.

examination showed left arm dystonia of distal distribution (figure 2, A and B) and a coarse action tremor involving proximal arm muscles. A slight internal rotation of the left foot on walking was also observed. A new CT showed a small area of low density in the postero-lateral thalamic nuclei (figure, I-B). A right carotid and vertebral angiography was normal. Platelet aggregation tests and coagulation studies were normal.

The patient could not return to work because of the dystonic movements. Treatment with Pimozide (6 mg per day) for two months did not improve the upper limb dystonia but the foot twisting disappeared during that period. A 30% improvement in left arm motor control was observed under treatment with Propranolol (200 mg per day). Treatment with Propranolol (240 mg per day) and Valproate (600 mg per day) produced a marked reduction of the tremor and dystonia. This was accompanied by extreme drowsiness. Valproate was substituted by Clonazepam (3 mg per day), resulting in a 80% improvement in both tremor and dystonia. Such improvement allowed the patient to use her left arm in daily activities for the first time in 16 months.

### COMMENT

The clinical spectrum of complicated migraine includes ophthalmoplegia, facioplegia, psychiatric disturbances ("dysphrenic migraine"), brain-stem signs ("vertebro basilar migraine") and hemiplegia, independently or in combination.<sup>3,6</sup> Dyskinetic movements have not often been reported in association with migraine. Infield<sup>7</sup> described in detail the case of a young patient with previous migraine history, who at the end of one attack suffered a shooting lightning-pain throughout the right half of her body, followed by transient hemiplegia. She developed right hemichorea four weeks later. Another case published early this century by Schob,<sup>8</sup> showed irregular muscle jerking affecting the four limbs during migraine attacks. The pathological findings were consistent with widespread vascular lesion.<sup>9</sup> Recently, Grimes et al<sup>10</sup> have reported three patients with delayed-onset posthemiplegic dystonia, one of whom had an identical clinical presentation and evolution than the case we have studied. However, the CT of that patient showed a large area of infarction affecting the contralateral putamen, caudate and thalamus.

Focal basal ganglia infarction causing one limb dystonia or hemidystonia is the most frequently recognized etiology of late onset dystonia.<sup>11,12</sup> Thromboembolic occlusions of the small perforating arteries supplying the basal ganglia nuclei are thought to be responsible for such ischemic lesions. The pathogenesis of stroke in patients with migraine is uncertain. Vasospasm of the intracranial arteries<sup>13</sup> or thromboembolism secondary to the hypercoagulability state present in many patients with migraine<sup>14</sup> may cause permanent neurological deficit in complicated migraine. Either of these mechanisms separately or in combination may have been responsible for the lesion of our patient, who in addition had an increased risk of thromboembolic complications due to pregnancy.

Although the experience is limited to two patients, delayed-onset dystonia following hemiplegic migraine does not seem to differ as to the evolution and pharmacological response from other cases of focal symptomatic dystonia. This is the second patient whom the combination of Propranolol and Valproate or Clonazepam produces a dramatic improvement of coarse action tremor.<sup>15</sup> The pharmacological and pathophysiological reasons underlying the need of two drugs to control severe symptomatic action tremor are not known at present. Further experience with a larger number of patients is required before attempting to reach any conclusion on this regard.

### REFERENCES

1. Bradshaw P, Parsons M: Hemiplegic migraine, a clinical study. *Quar J Med* 133:65-85, 1965.
2. Whitty CWM: Familial hemiplegic migraine. *J Neurol Neurosurg Psychiatry* 16: 172-177, 1963.

3. Cohen RJ, Taylor JR: Persistent neurologic sequelae of migraine. A case report. *Neurology* 29:1175-1177, 1979.
4. Dooling EC, Adams RD: The pathological anatomy of posthemiplegic athetosis. *Brain* 98:29-48, 1975.
5. Burke RE, Fahn S, Gold AP: Delayed onset dystonia in patients with "static" encephalopathy. *J Neurol Neurosurg Psychiatry* 43:789-797, 1980.
6. Bruyn GW: Complicated migraine. In *Handbook of Neurology, Amsterdam, Elsevier North Holland Inc, Vol. 5*, pp 59-95, 1968.
7. Infeld M: Zur Kenntmis der bleibenden Folgen des Migraine-Anfalles. *Wien Klin Wsdir* 14:673-675, 1901.
8. Schob F: Beitrag zur Kenntmis der schweren Migräneformen (Migräne mit Herdsymptomen und psychische Störungen). *Z Ges Neurol Psychiat* 35:151-174, 1917.
9. Hilpert P: Ein Beitrag zur schweren Migraneform mit anatomischem Befund. *Z Ges Neurol Psychiat* 7:478-487, 1925.
10. Grimes JD, Hassan MN, Quarrington AM et al: Delayed-onset posthemiplegic dystonia: CT demonstration of basal ganglia pathology. *Neurology [Ny]*. 32:1033-1035, 1982.
11. Russo LJ: Focal dystonia and lacunar infarction of the Basal Ganglia. *Arch Neurol* 40:61-62, 1983.
12. Traub MM, Ridley A: Focal dystonia in association with cerebral infarction. *J Neurol Neurosurg Psychiatry* 45:1073-1074, 1982.
13. Dukes HT, Vieth R: Cerebral arteriography during migraine prodrome and headache. *Neurology* 14:626-639, 1964.
14. Kalendovsky Z, Austin J: Changes in blood clotting systems during migraine attacks. *Headache* 16:293-313, 1977.
15. Obeso JA, Narbona J: Posttraumatic tremor and myoclonic jerking. *J Neurol Neurosurg Psychiatry* 48:788, 1983.