

Department of Neurology, Centre Hospitalier Universitaire Vaudois, Lausanne,
Switzerland

**Benign Outcome in Unoperated Large Cerebellar
Haemorrhage**
Report of 2 Cases

By

J. Bogousslavsky, F. Regli, and X. Jeanrenaud

With 2 Figures

Summary

We studied two patients with large cerebellar haemorrhages, who were conscious on admission and did not deteriorate during the following days. Surgical decompression was not performed and the patients regained their former level of activity, except for moderate persisting ataxia. We suggest that cerebellar haemorrhage may have a benign spontaneous outcome, more often than previously assumed from autopsy series. The main selection criteria for surgery is an impaired state of consciousness and evidence of neurological worsening. Taken alone, the size of the haemorrhage on computerized tomography is not a reliable criterion for surgery.

Cerebellar haemorrhage usually bears a catastrophic outcome, because the patients rapidly die from acute intracranial hypertension with brainstem compression^{2,7,15}. During the last 25 years, early surgical decompression has been emphasized by most authors in order to avoid this relentless evolution^{1,2,4,11,13,14,16}. However, isolated cases with a small haemorrhage have also been reported doing quite well without surgery^{4,6,14}. We now report two cases with a large cerebellar haemorrhage, who were successfully managed with a conservative approach.

Case 1

This 80-year-old hypertensive (untreated) man was in good health until two years prior to admission, when he suffered a right hemiparesis that progressively disappeared in three weeks. He took dicoumarol during four months at that time. Two years later, he showed an increasing fatigue, with postural instability, and disorientation, which progressively develop within a few days. Gait disturbances increased and the patient was admitted after he showed recurrent vomiting.

The patient was afebrile, blood pressure was 180/110 mm/Hg, with a regular pulse (80 min). An aortic murmur (2/6) was present but auscultation of the carotid arteries was normal. Optic fundi were normal. Visual acuity and visual fields were preserved. Ocular mobility was slowed in all directions, and optokinetic nystagmus was absent to the left. No pupillary disturbances were present. Other cranial nerves were normal. Strength and tonus appeared symmetrical and normal in the four limbs, but a slight increase in the tendon reflexes was present on the right side of the body, with a bilateral Babinski sign. Sensation was completely preserved. A dysmetria and hypermetria were present in the right superior and inferior limbs. Adiadochokinesia and the rebound phenomenon were present in the right arm. The patient remained well-oriented, but was quickly fatigued during the examination.

Standard blood and urine tests were normal. ECG showed atrial fibrillation (60 min) with a partial right bundle-branch block. A computerized tomographic scan of the brain showed a large intraparenchymatous haemorrhage in the right cerebellar hemisphere also involving the vermis and the left paravermis. Widening of the cerebral sulci and enlargement of the lateral ventricles was also present.

The patient was not operated on because of the absence of signs of intracranial hypertension. He remained stable for 10 days and was referred for convalescence to another hospital, which he could leave after six weeks, being able to walk with a stick. Alpha-methyl dopa (250 mg/day) was introduced to control the hypertension.

Case 2

This 75-year-old non-insulin dependent diabetic man suffered an anterior myocardial infarction with residual angina pectoris, three years prior to the present admission. He was taking aspirin, dipyridamole, oxprenolol and isosorbide dinitrate. The day before admission he suddenly complained of rotatory vertigo without directional preponderance, with exacerbations on head movements. A few hours later he experienced vertical diplopia, and vomited three times.

On admission the following day, the patient was well-oriented and still complained of vertical diplopia and dizziness, but without headache. No meningitis was present. There was a skew deviation with the left eye being higher than the right eye, with a gaze-paretic nystagmus to the left and no response on optokinetic stimulation to the right. Other cranial nerves were normal. No hemiparesis was present, but the patient showed a massive axial deviation to the right in the sitting position, and walking was impossible. Tendon reflexes were slightly hyperactive in the left limbs, with a left Babinski sign. Sensation was

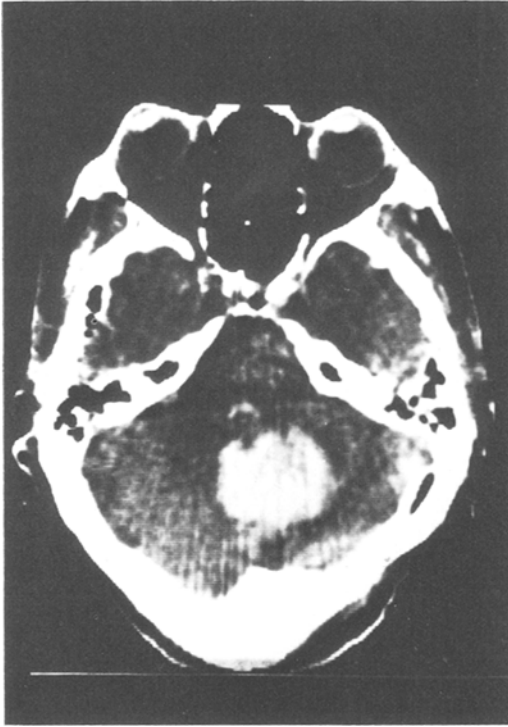

Fig. 1. *Case 1*: CT scan on admission. Large vermian and right hemispheric haemorrhage in the cerebellum

normal, except a moderate distal tactile hypaesthesia in the inferior limbs. Blood pressure was 190/110 mmHg, pulsations were 100 min and regular, general examination was normal.

Standard blood and urine tests were normal. CSF (lumbar puncture) was bloody, with 10,000 red cells/ml and three white cells/ml (1 polymorphonuclear, 2 lymphocytes); protein content was 1,530 mg/l. A CT scan performed on the same day showed a vermian and left hemispherical haemorrhage in the cerebellum (Fig. 2 a) and diffuse cortical atrophy.

Because of clear consciousness and absence of acute intracranial hypertension the patient was not referred for surgery. He remained stable during the following days, except that some cerebellar dysmetria and adiadochokinesia developed in the superior limbs, with visual hallucinations (animals). Dexamethasone, which had been introduced on admission (20 mg/day i. v.) was discontinued after one week. A control of the CT scan showed a progressive resolution of the haemorrhage (Fig. 2 b).

The patient was discharged four weeks after admission. He was able to walk

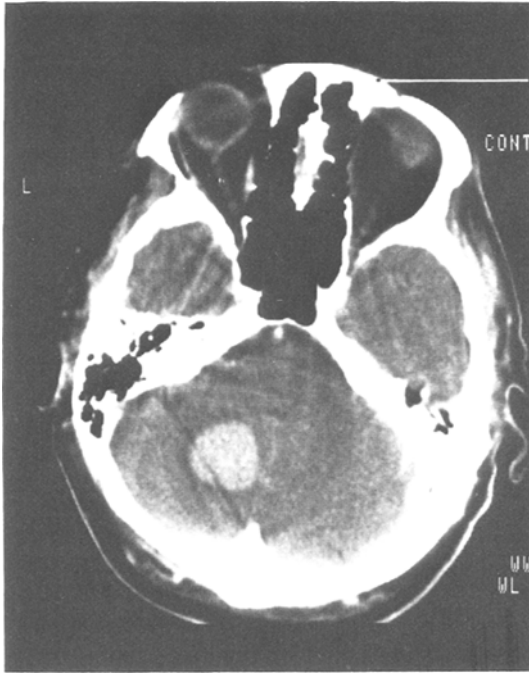


Fig. 2a. *Case 2*: CT scan on admission. Large vermian and left hemispheric haemorrhage in the cerebellum

alone and showed only a slight axial instability. A moderate dysmetria was still present in the left superior limb, with bilateral postural tremor. The tendon reflexes were still hyperactive in the left limbs, with a Babinski sign.

Discussion

The rate of intracerebellar haemorrhage has been found to be 5–13 per cent of intracerebral haemorrhages^{8,12,14}. In most published series, the natural evolution of spontaneous cerebellar haemorrhage has been fatal, because of the quick development of intracranial hypertension and brainstem compression^{1,2,4,11,14,15}. Thus, surgical decompression has been suggested, being imperative as soon as the diagnosis has been made^{1,2,4,11,13,14,16}. However, it should be emphasized that most of the large published data deal with autopsy series, and may not include some more benign cases^{4,14}. In fact, a few recent studies reported that isolated unoperated cases might survive, when the haemorrhage is limited and the mass effect minor^{3,4,6,9,14}. This finding is partially related to

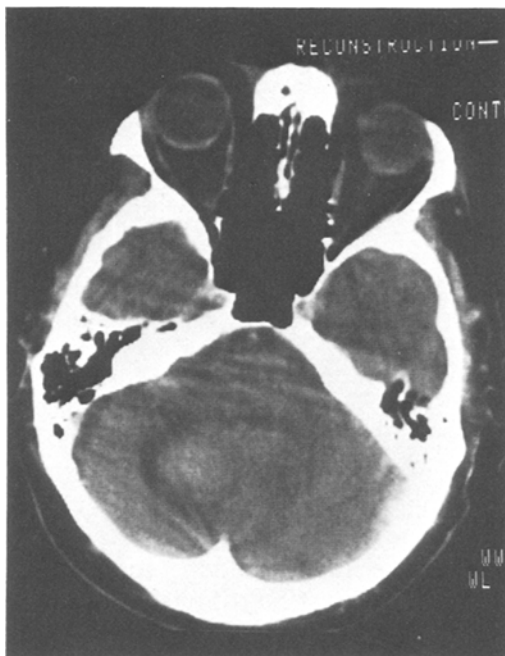


Fig. 2 b. *Case 2*: CT scan after two weeks. Partial resolution of the cerebellar haemorrhage

the development of computed tomography (CT), which allowed clinicians to make an earlier diagnosis, because the signs and symptoms of cerebellar haemorrhage are usually non-focalizing or may suggest pontine haemorrhage^{2,4,10,14}. However, even if the patient spontaneously survives, the evolution may not be “benign”, because of persisting and disabling neurological sequelae^{5,9}.

In our two cases with a large intracerebellar haemorrhage we were able to avoid surgical treatment, because the patients' conditions remained stable and no coma developed. It is probable that both our patients benefited from the cerebral (and probably cerebellar) atrophy demonstrated by CT, which attenuated the mass effect of the haemorrhage and its consequences on the brainstem. The most important point that incited us to medically treat our patients was the well-preserved state of consciousness on admission, without further deterioration. Some authors suggested that *all* patients suffering a spontaneous cerebellar haemorrhage should be rapidly operated on^{2,11,13,16}. However, other reports suggested that in stable and conscious patients, a conservative

approach could be tried (unless delayed deterioration develops)^{3,4,6,9}, but this situation is not common in the literature. Heiman and Satya-Murti⁴ recently reported two patients with a spontaneously benign outcome, but on CT scan the cerebellar haemorrhage was rather small, as it was in 4 cases reported by Labauge *et al.*⁹. Chin *et al.*³ also reported cases with rather benign outcome, but CT features were not described. Our cases, especially Case 1, show that the indication for surgery does not depend on the extent of the haemorrhage on CT, but rather on clinical features.

We agree with an early surgical decompression when the patients are stuporous on admission or when they show a rapid deterioration, and it should be pointed out that delayed and sudden worsening may occur as late as one week after the initial event^{7,14}. However, we think that in conscious patients who do not deteriorate, a conservative therapy should be tried, with permanent and careful neurological controls to detect any worsening.

“Benign” cerebellar haemorrhages may be more frequent than previously assumed, because in older patients with non-specific clinical findings, CT may not be routinely performed.

References

1. Aronson, H., Shafey, S., Gargano, F., Intracerebellar haematoma. *J. Neurol. Neurosurg. Psychiat.* 28 (1965), 442–444.
2. Brennan, R. W., Bergland, R. M., Acute cerebellar haemorrhage. Analysis of clinical findings and outcome in 12 cases. *Neurology* 27 (1977), 527–532.
3. Chin, D., Carney, P., Acute cerebellar haemorrhage with brainstem compression in contrast with benign cerebellar haemorrhage. *Surg. Neurol.* 19 (1983), 406–409.
4. Fisher, C. M., Picard, E. H., Polak, A., Dalal, P., Ojemann, R. G., Acute hypertensive cerebellar haemorrhage: Diagnosis and surgical treatment. *J. Nerv. Ment. Dis.* 140 (1965), 38–57.
5. Freeman, J. W., Kennedy, R. M., Petty, S. S., Prognosis of nonoperated cerebellar haemorrhage. *Ann. Neurol.* 4 (1978), 389–390.
6. Heiman, T. D., Satya-Murti, S., Benign cerebellar haemorrhages. *Ann. Neurol.* 3 (1978), 366–368.
7. Heros, R. C., Cerebellar haemorrhage and infarction. *Stroke* 13 (1982), 106–109.
8. Hyland, H. H., Levy, D., Spontaneous cerebellar haemorrhage. *Can. Med. Assoc. J.* 71 (1954), 315–323.
9. Labauge, R., Boukobza, M., Zinszer, J., Blard, J. M., Pages, M., Salvaing, P., Hématomes spontanés du cervelet. Vingt-huit observations personnelles. *Rev. Neurol.* 139 (1983), 193–204.

10. Little, J. R., Tubman, D. E., Etheir, R., Cerebellar haemorrhage in adults. Diagnosis by computerized tomography. *J. Neurosurg.* 48 (1978), 575–579.
11. McKissock, W., Richardson, A., Walsh, L., Spontaneous cerebellar haemorrhage. A Study of 34 consecutive cases treated surgically. *Brain* 83 (1960), 1–9.
12. Mitchell, N., Angrist, A., Spontaneous cerebellar haemorrhage. Report of 15 cases. *Amer. J. Pathol.* 18 (1942), 235–253.
13. Norris, J. W., Eisen, A. A., Branch, C. L., Problems in cerebellar haemorrhage and infarction. *Neurology* 19 (1969), 1043–1050.
14. Ott, K. H., Kase, C. S., Ojemann, R. G., Mohn, J. P., Cerebellar haemorrhage: Diagnosis and treatment. *Arch. Neurol.* 31 (1974), 160–167.
15. Rey-Bellet, J., Cerebellar haemorrhage. A clinico pathologic study. *Neurology* 10 (1960), 217–222.
16. Siris, H., Beller, J., Spontaneous intracerebellar haemorrhage: surgical treatment. *Surg. Clin. North. Amer.* 28 (1948), 412–415.

Authors' address: Dr. J. Bogousslavsky, Prof. Dr. F. Regli, and Dr. X. Jeanrenaud, Department of Neurology, Centre Hospitalier Universitaire Vaudois, CH-1011 Lausanne, Switzerland.