

Residual Reading Capability in a Patient with Alexia without Agraphia

DARIO GROSSI, NINA A. FRAGASSI, ARTURO ORSINI,
FABRIZIO A. DE FALCO,* AND ORNELLA SEPE*

*Clinica Neurologica, Il Facolta di Medicina, Naples, and *Ospedale S. Maria
di Loreto Nuovo, Naples*

A case of pure alexia due to an ischemic lesion of the occipital temporal region is described. Written words could be matched but not read. Immediate memory span for graphemes was defective. The reading defect probably depends on the inability to modify the written word "globally"; the phonological process was intact, but the memory disturbance impeded reading. The dissociation is explained by the preservation of word forms, which are linked to the semantic stage. Non-written stimuli trigger a "meaning" which evokes the word form and so the written word is recognized even though it cannot be read. © 1984 Academic Press, Inc.

Alexia without agraphia is a relatively usual clinical syndrome. It was first described by Dejerine in 1892 and has been associated with involvement of the medial occipital region in the dominant hemisphere (Benson, Brown, & Tomlinson, 1971), often related to occlusion of the left posterior cerebral artery (Gloning, Gloning, & Hoff, 1968; Benson & Geschwind, 1969).

A residual reading capability has been found in patients with alexia. Kreinder and Ionaşescu (1961) used facilitating ("unblocking") auditory and visual tests to permit the reading of certain words and sentences in a patient with "pure" alexia. Albert, Yamadori, Gardner, and Howes (1973), in a patient with a particular form of alexia with agraphia, found that perception of written words was intact and that semantic understanding of them was relatively well preserved. Caplan and Hedley-White (1974) in a patient with alexia without agraphia demonstrated that reading was possible only when naming was not required or when cueing was introduced. Rothi and Heilman (1981) reported a patient with alexia and

The authors are grateful to Professor Hans Spinnler of the Centro di Neuropsicologia of Milan for advice concerning investigation methods, and to Professor Virgilio Agnetti of the Neurological Department, University of Sassari for providing the map of the lesion. Address correspondence to Dr. Dario Grossi, Clinica Neurologica, II Facoltà di Medicina, Via Pansini 5, 80131 Naples, Italy.

agraphia who had intact spelling and comprehension of spelled words and who used "ideographic letter-naming strategy" to read.

We report a clinical neuropsychological investigation of a patient with pure alexia. We found a dissociation between naming and recognition of written words, and an impaired memory span for graphemes.

This study highlights the role played by the internal representation of written words in first recognizing, then connecting written words to meaning (semantic stage), and the role of memory in letter-by-letter reading.

CASE REPORT

Our patient is a 64-year-old, right-handed decorator and sign painter, with primary school education only. He had a 10-year history of diabetes, treated with oral hypoglycemic agents.

In April 1980, at the age of 62, he suddenly developed loss of strength and a sensation of cold in the lower limbs, derangement, and space-time disorientation. Upon hospitalization, examination showed blood pressure of 200 mm Hg, disorientation (which improved after a few days), anomia, right hemianopsia and alexia, and a mild loss of strength in the right upper limb. A radioisotope brain scan showed increased uptake in the left medial occipital area.

Laboratory tests and radiological examination were within normal limits. In 1982 he was admitted to the Neurological Section of S. Maria di Loreto Hospital because of the persistence of reading disturbances. Neurological examination showed right homonymous hemianopsia (confirmed by Goldman perimetry) and alexia. Sensation was unimpaired. An EEG demonstrated moderate left parieto-occipital slowing. Laboratory and radiological examinations were within normal limits. A C.T. scan showed a normal fourth ventricle, and a clearly outlined area of decreased density in the occipital and temporo-occipital region with mild enlargement of the lateral ventricle in the left hemisphere. Left thalamus and splenium were also damaged. There was no cerebral cortical atrophy. Figures 1a and b show the C.T. scan and an anatomical reconstruction of the damage. A map of the lesion is illustrated on a drawing of the medial brain face in Fig. 2.

NEUROPSYCHOLOGICAL STUDY

(1) *Agnosia*

(a) *Color agnosia (Table 1). (a1). Color matching test.* The patient was requested to pair equally colored labels within two equal series of 15 differently colored labels. Score 15/15.

(a2) *Ischihara test.* Score 21/21.

(a3) *Color naming.* The patient was requested to name 12 colored labels. Score 12/12.

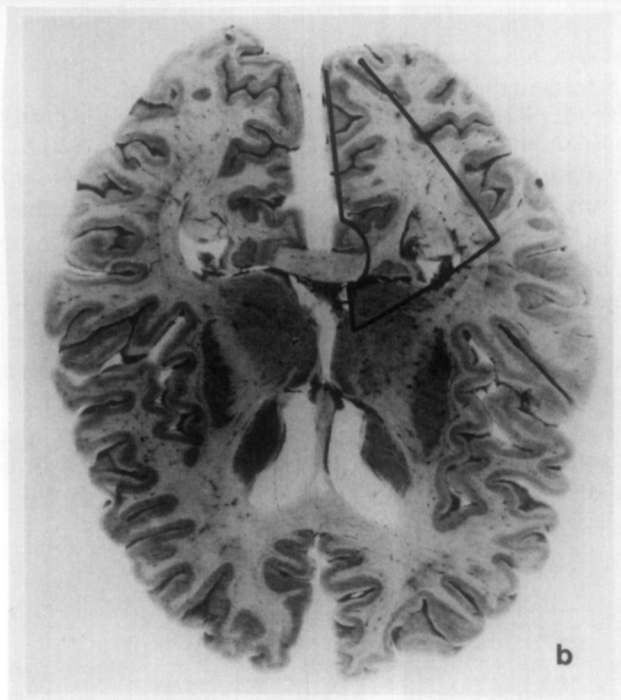
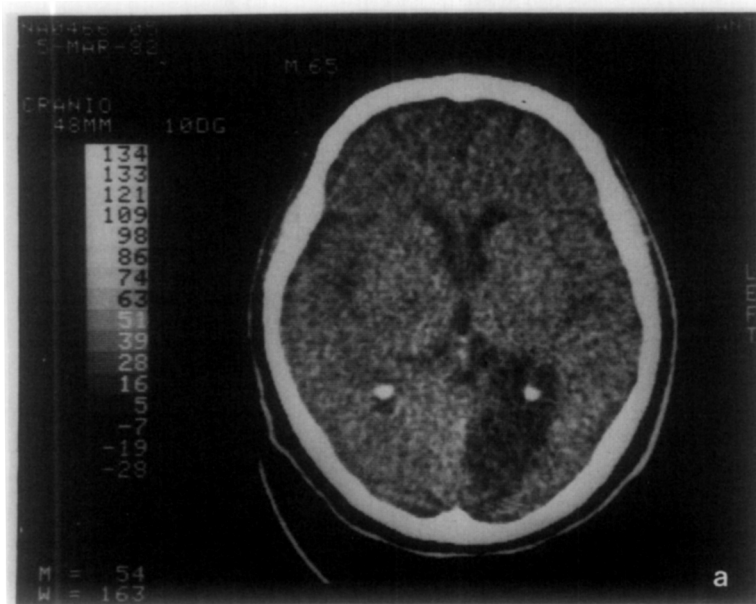


FIG. 1.

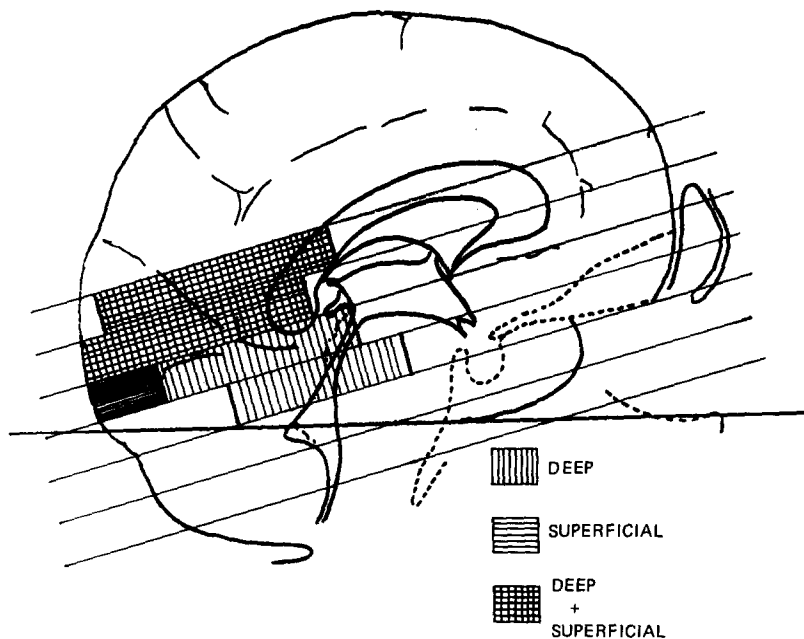


FIG. 2.

(a4) *Color recognition.* The patient was requested to identify a color named by the examiner among 12 colored labels. Score 12/12.

(b) *Picture agnosia (Table 2).* (b1) *Picture-object correlation.* The patient was shown a picture of an object. There were five objects on a table: one was the object represented in the picture (e.g., a pipe), two were objects of the same category (e.g., a cigarette and an ashtray), and two were objects of different categories (e.g., a glass and a pen). The patient was requested to select the object represented in the picture among others. All object names had a low frequency (Bortolini, Tagliavini, & Zampolli, 1972). Score 10/10.

(b2) *Naming simple drawings.* The patient was shown 15 pictures (5 of objects in everyday use, 5 of common flowers, and 5 of common fruits) one at a time. He was asked to name them. Score 15/15.

TABLE 1
COLOR AGNOSIA

| Task | Score |
|-------------|-------|
| Matching | 15/15 |
| Naming | 12/12 |
| Recognition | 12/12 |
| Ischiara | 21/21 |

TABLE 2
PICTURE AGNOSIA

| Task | Score |
|----------------|-------|
| Picture-object | 10/10 |
| Naming | 15/15 |
| Describing | 14/15 |

(b3) *Describing complex pictures.* The patient was shown the following pictures: five common objects in unusual perspectives (e.g., a glass shown from above); five architectonic perspectives generally used by architects to study a place (e.g., a bedroom shown from a corner); five bizzare pictures (e.g., a centaur with an elegant dress or a man with enormous hands and very small feet). The patient was requested to describe the pictures; he had to identify the principal subjects and the particularity of the pictures. Score 14/15.

(2) *Memory*

(a) *Immediate memory span (Table 3.) (a1) Corsi's spatial span test (Grossi, Matarese, & Orsini, 1980). Score 4.*

(a2) *Wechsler Digit Forward test. Score 4.*

(a3) *Word verbal span. Score 2.*

(a4) *Phoneme span.* The patient was asked to repeat a phoneme string (consonant and vowels). The test began with a sequence of one unit and if the patient succeeded, increasingly long sequences up to a possible maximum of eight were presented. Each time a maximum of five different sequences was given. The score was the highest string reproduced accurately three times out of five. The rate of presentation was one phoneme per second. Score 5.

(a5) *Grapheme span.* The patient was asked to repeat a grapheme string (consonant and vowels) orally. Each grapheme of one string was given, one at time, on a label in printed capitals. The patient was invited to read aloud each grapheme and then to repeat the entire string. The scoring and the rate of presentation was the same of the phoneme span test. Score 1.

TABLE 3
IMMEDIATE MEMORY SPAN

| Task | Score |
|---------------------------|-------|
| Corsi's spatial span test | 4 |
| Digit forward test | 4 |
| Word verbal span | 2 |
| Phoneme span | 5 |
| Grapheme span | 1 |

(b) *Learning.* (b1) *Spatial learning at Corsi's test* (Orsini, Schiappa, Chiacchio, & Grossi, 1982) of a span series plus two digits. The patient did not reach the criterion (two consecutive correct repetitions of the stimulus series) in 20 trials, and did not reproduce more than two digits in the correct order in any response.

(b2) *(Free) verbal learning of 10 two-syllable words in 20 trials.* The patient did not reach the criterion (two consecutive correct repetitions of all the 10 words). The maximum number of words correctly repeated was 5.

(c) *Description of places.* The patient was asked to describe places well known to him. The descriptions were incomplete and confused. On more than one occasion the patient described architectural elements that had long since disappeared (10 normal controls that live in the same place performed this task without any difficulty).

(3) *Language Examination (Table 4)*

(a) *Spontaneous speech: fluent, without paraphasia or anomia.*

(b) *Description of everyday objects* (Basso, Capitani, & Vignolo, 1979). Score 9/10.

(c) *Naming everyday objects* (Basso et al., 1979). Score 11/15.

(d) *Understanding.* Token test. Score 28/36.

(4) *Writing*

No disturbance evident in either spontaneous or dictated writing (Table 5). The patient was not able to read the words written by himself. He copied written words as they were spatial constructions.

(5) *Phonemic spelling (Table 6)*

The patient was asked to pronounce the phoneme components of presented words. We called this kind of spelling phonemic because the patient had to avoid the naming of single letters but sound them out (e.g., if a word contains the letter "b" the patient had to sound out "b" and not to name "bi"). The presented words had a low frequency, 10 of them were four letters long, 5 were five letters long, and 5 were six letters long. Each word had to be spelled correctly in its entirety.

TABLE 4
LANGUAGE EXAMINATION

| Task | Score |
|--------------------|-------------------------------------|
| Spontaneous speech | Fluent without paraphasia or anomia |
| Description | 9/10 |
| Naming | 11/15 |
| Token test | 28/36 |

TABLE 5
WRITING

| | N | Correct | | N | Correct | | N | Correct |
|---------------------|----|---------|-----------|----|---------|-----------|----|---------|
| Spontaneous writing | | | Dictated | | | Copying | | |
| Letters | 32 | 10 | Letters | 32 | 28 | Letters | 20 | 20 |
| Words | 30 | 28 | Words | 20 | 20 | Words | 20 | 20 |
| Sentences | 10 | 10 | Sentences | 10 | 10 | Sentences | 10 | 3 |
| | | | Numbers | 20 | 20 | | | |

(a) *Orally presented words.* Score 20/20.

(b) *Words in printed form.* The printed words were not removed before the patient spelled them. Score 18/20.

(b1) *Reading of words spelled correctly.* Score 0/20.

(b2) *Recalling letters of the words spelled correctly.* Score: only one letter per word.

The tests b1 and b2 were given to demonstrate the patient's inability to combine and remember recognized graphemes. It is useful to mention that letter-by-letter reading in Italian is different from letter-by-letter reading in English; in fact there are intrinsic differences between the two orthographies.

(6) *Reading*

(a) *Reading.* The patient was asked to read letters, words, nonwords, and sentences in printed and script form (Table 7); he was also presented with overturned letters (top-bottom reversal) and numbers (Table 7). Reading of the letters was slightly deficient and there was not significant difference between the type of writing presented. In most cases the patient took a very long time to identify each single letter; on several occasions he spoke a string of letters aloud until he came to the one presented. He could read only two of the words printed and none of the sentences or nonwords. He was able to match letters in printed capitals and script form. Any type of paralexia was not found.

(b) *Proprioceptive reading.* The patient was blindfolded and his finger was guided around the outline of letters, so every letter was transformed

TABLE 6
PHONEMIC SPELLING

| Task | Score |
|--|-------------------|
| Orally presented words | 20/20 |
| Words in printed form | 18/20 |
| Reading words spelled correctly | 0/20 |
| Recalling letters of correctly spelled words | 1 letter per word |

TABLE 7
READING

| | No. of tests | Correct responses |
|---|--------------|-------------------|
| Reading | | |
| Printed capital letters | 42 | 38 |
| Letters in script form | 42 | 36 |
| Words in printed capitals | 50 | 2 |
| Words in script form | 50 | 3 |
| Sentences in printed capitals | 10 | 0 |
| Sentences in script form | 10 | 0 |
| Overtured printed capital letters | 42 | 32 |
| Simple numbers | 30 | 30 |
| Complex numbers | 20 | 16 |
| Nonwords of four letters | 20 | 0 |
| Proprioceptive reading | | |
| Letters recognized blindfolded | 15 | 13 |
| Letters recognized without blindfold | 15 | 15 |
| Words recognized blindfolded | 20 | 19 |
| Words recognized without blindfold | 20 | 18 |
| Sentences recognized blindfolded | 10 | 0 |
| Sentences recognized without blindfold | 10 | 0 |
| Letters in printed form and in script form matching | 40 | 36 |

into proprioceptive information. Letters and words were almost always read, while reading of a sentence was impossible. When the blindfold was removed, the patient traced the outline of the letters himself, with the same result (Table 7).

(c) *Matching test* (Table 8). The aim of this test was to verify if the word form (the visual internal representation of the written word) was intact. Lexical items are characterized in a visual code in word form system; we attempted to reach the word forms using other codes. Word stimuli were presented with various perceptive means (visual, auditory, proprioceptive), and the patient had to select the written equivalent from

TABLE 8
MATCHING TEST

| Word stimulus | No. of tests | Correct responses | Delayed | |
|---------------------|--------------|-------------------|--------------|-------------------|
| | | | No. of tests | Correct responses |
| Auditory word | 12 | 10 | 12 | 9 |
| Proprioceptive word | 12 | 9 | 12 | 8 |
| Written word | 12 | 0 | | |
| Image | 12 | 9 | 12 | 8 |
| Object | 12 | 9 | 12 | 8 |

a list of 10 two-syllable words all beginning with the same letter. Five words of the list were similar for form. For each of the five matching tests the patient was given 12 trials and for each trial there was a different list of 10 two-syllable written words.

(c1) *Auditory word-written word*. The examiner said a two-syllable word which the patient had to select from a list of 10 written words. Score 10/12.

(c2) *Proprioceptive word-written word*. The patient was blindfolded, his finger was traced around the outline of a written word so every written letter was transformed into proprioceptive information (we called this type of stimulus "proprioceptive word"), and then the patient was requested to select the word from a list of 10 written words after removing the stimulus written word. Score 9/12.

(c3) *Picture-written word*. The patient was shown a picture of an everyday object and had to identify it from a list of 10 written words (the stimulus picture was not removed during this test). Score 9/12.

(c4) *Object-written word*. The patient was shown an object and had to find the corresponding word in a list of 10 words (the stimulus object was not removed during this test). Score 9/12.

(c5) *Written word-written word*. The patient was shown a written word and had to find the equivalent in a list of 10 words (the stimulus word was not removed during this test). Score 0/12.

(d) *Delayed matching test (Table 8)*. The above mentioned tests c1, c2, c3 and c4, were also presented with a delay of 30 sec between the presentation of the stimulus and the task performance. In c3 and c4 delayed performance tests the stimulus was removed during the tests.

COMMENT

Our patient is clearly affected by alexia without agraphia. He performed well on writing tests, while he was never able to read a word or a sentence. He had no difficulty in identifying letters regardless of the form of writing presented. Spelling of written words was nearly always correct even though it was slow and tedious: the patient compared each letter, step by step, with a series of letters that he pronounced aloud until he came to the one presented. He was never able to read a word even though he spelled it correctly, neither was he able to remember the letters he spelled correctly.

In accordance with other reports of this disorder, our patient also had an impairment of memory (Mohr, Leicester, Stoddard, & Sidman, 1971; Caplan & Hedley-White, 1974). This deficit is due to lesions of the deep structures of the temporal lobe and the thalamus of the left hemisphere (Geschwind & Fusillo, 1966), which were clearly damaged in our patient.

The patient's selective deficit of immediate memory for graphemes is particularly interesting, especially when compared to the good score

obtained at the span of phonemes (in our experience 60-year-old normal subjects under the same conditions of testing have a grapheme span between 5 and 7 well-remembered units). There is a strong memory interference for graphemes which arises from the slow, tedious device adopted by the patient to recognize letters: the test of immediate memory span was transformed into a long term memory test. The latter was impaired particularly when stimuli were presented with graphemes. The patient was unable to find a strategy which enabled him to retain written letters for several seconds, even those which were correctly recognized and named.

The most relevant finding is that the patient was able to match nonwritten stimuli to written words, as has been found in other patients with this disorder (Kreindler & Ionășescu, 1961). The internal representation of the written words, the so-called word forms, was clearly preserved. Word forms could be evoked through nonwritten stimuli and could be compared with the written word. The comparison between written word and written word failed in that the patient was unable to manipulate the stimulus as a spatial pattern.

It should be stressed that no marked differences were found between the performance on delayed tests and that on nondelayed tests. This suggests that delay tasks require different routes to those required to perform other memory tests. Similarly, comparison between word form and written word must use nerve routes other than those used to compare written word with word form, the former being possible and the latter not in this condition.

The matching tests show that to evoke the internal representation of a specific written word, a nonwritten stimulus must undergo a series of transformations (comparison with the internal representation relative to the perceptive strategy used, naming and/or connection with a certain meaning). All these transformations, which are strictly concerned with verbal processes, we call "internal language."

The tests excluded the possibility that our patient had aphasic or agnosic disturbances. His good performance on color tests contrasts with observations that color agnosia is associated with pure alexia, especially in forms due to lesions of the medial lesions of the left occipital lobe (Mohr et al., 1971). The patient's occupation as a decorator may have some bearing on the results of color tests.

CONCLUSIONS

Andreewsky (1974) proposed a model of reading based on cognitivist psychology. The model foresees a first reading process which consists of an analytical-type perceptive level (letter-by-letter, syllable-by-syllable) and a linguistic level which, depending on the phonological stage (grapheme-phoneme correspondence), precedes and conditions the semantic stage.

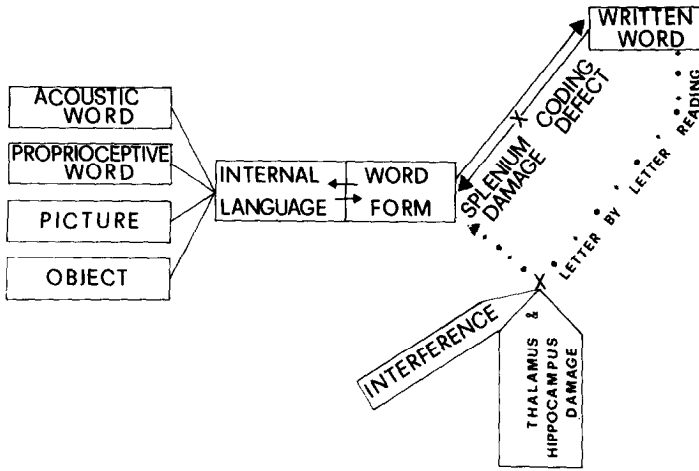


Fig. 3. "Acoustic word," "proprioceptive word," "picture," and "object" are transformed in "internal language" (meaning). From this stage access to the "word form" system is possible; an evoked specific "word form" allows written word recognition. "Written word" cannot access to the word form system directly because of splenium damage. The "letter-by-letter reading" process works but fails because of memory defect ("interference") depending on "thalamus and hippocampus damage."

The second reading process is global at the visual level, thus words are simultaneously taken as a whole, and the unit is made to coincide with a specific internal representation. At the linguistic level, reading depends on the lexical or semantic stage (nonphonological reading process). Clinical evidence has shown the independence of the two systems (Beauvois & Derouesne, 1979).

Our patient's disturbance seems to be at a perceptive level of the second reading process, that is of the global reading of a word. The semantic stage is not impaired. An inverse process at the perceptive level is possible (see Fig. 3).

- (1) A specific meaning is given to a nonwritten stimulus (internal language).
- (2) The meaning evokes a specific word form.
- (3) The word form allows the written word to be recognized.

This process shows that the meaning of a word is linked to all its mental representations (different depending on the different stimuli); moreover it shows that the meaning evokes a specific mental representation and vice versa. The meaning itself is a link between several representational events, that thus become a whole.

Regarding the first reading process, the perceptive level in our patient is intact. The phonological level works but reading is not possible because memory disturbances hinder the performance of the correct strategy.

It is likely that the splenium of the corpus callosum is indispensable

for the perceptive level of the "nonphonological" reading process. The process of word recognition could occur through other routes. Our interpretation of the selective deficit of memory span for graphemes supports the hypothesis that the left hippocampal structure is necessary for phonological reading.

We have demonstrated a residual reading capacity only when the patient was requested to read using word forms in simple recognizing tests. The patient had lost the "key" that gives access to the internal representations, and therefore, according to our model, to the meanings. The "key" is the correct combination of "grapheme clusters" (written words) made possible by both the phonological and "nonphonological" reading processes. In our patient the former was impaired by a disorder at perceptive level, and the latter by a disturbance of selective memory for graphemes.

REFERENCES

- Albert, M. L., Yamadori, A., Gardner, H., & Howes, D. 1973. Comprehension in alexia. *Brain*, **96**, 317-328.
- Andreewsky, E. 1974. Un modele semantique. Application a la pathologie du langage: Alexia aphasique. *Traitement Automatique Informations*, **2**, 3-27.
- Basso, A., Capitani, E., & Vignolo, L. A. 1979. Influence of rehabilitation on language skills in aphasic patients. A controlled study. *Archives of Neurology*, **36**, 190-196.
- Beauvois, M. E., & Derouesne, J. 1979. Phonological alexia: Three dissociations. *Journal of Neurology, Neurosurgery, and Psychiatry*, **42**, 1115-1124.
- Benson, D. F., Brown, J., & Tomlinson, E. B. 1971. Varieties of alexia. Word and letter blindness. *Neurology (Minn.)*, **21**, 951-957.
- Benson, D. F., & Geschwind, N. 1969. The alexias. In P. J. Winken & G. W. Bruyn (Eds.), *Handbook of clinical neurology*. Amsterdam: North-Holland. Pp. 112-140.
- Bortolini, U., Tagliavini, C., & Zampolli, A. 1972. *Lessico di Frequenza della Lingua Italiana Contemporanea*. Milano: Garzanti.
- Caplan, L. R., & Hedley-White, T. 1974. Cueing and memory dysfunction in alexia without agraphia. A case report. *Brain*, **97**, 251-262.
- Geschwind, N., & Fusillo, M. 1966. Color naming defects in association with alexia. *Archives of Neurology*, **15**, 137-146.
- Gloning, I., Gloning, K., & Hoff, H. 1968. *Neuropsychological symptoms and syndromes in lesions of the occipital lobe and the adjacent areas*. Paris: Gautier-Villars. Pp. 75-81.
- Grossi, D., Matarese, V., & Orsini, A. 1980. Sex differences in adults' spatial and verbal memory span. *Cortex*, **16**, 339-340.
- Kreindler, A., & Ionășescu, Y. 1961. A case of "pure" word blindness. *Journal of Neurology, Neurosurgery, and Psychiatry*, **24**, 275-280.
- Mohr, J. P., Leicester, J., Stoddard, L. T., & Sidman, M. 1971. Right hemianopia with memory and color deficits in circumscribed left posterior cerebral artery territory infarction. *Neurology (Minn.)*, **21**, 1104-1113.
- Orsini, A., Schiappa, O., Chiacchio, L., & Grossi, D. 1982. Sex differences in children's spatial serial-learning task. *The Journal of Psychology*, **111**, 67-71.
- Rothi, L. J., & Heilman, K. M. 1981. Alexia and agraphia with spared spelling and letter recognition abilities. *Brain and Language*, **12**, 1-13.