

Neuropathology of Secondary Generalized Epilepsy— (Lennox-Gastaut Syndrome)—A Case Report

Kenji Ikeda, M.D., Sumie Ikeda, M.D., Tsuyoshi Yoshimura, M.D.,
Hideaki Kato, M.D. and Masuyuki Namba, M.D.

Department of Neuropsychiatry, Gifu University School of Medicine, Gifu

INTRODUCTION

Lennox syndrome is commonly known as an age-dependent childhood epilepsy with various types of seizures (ex. tonic and atstatic seizures and atypical absences) and characteristic diffuse slow spike and wave complex in EEG's. It was taken for epileptic encephalopathy by Gastaut,² based on clinico-electroencephalographic studies. Many cases in which this syndrome developed were reported to show encephalopathies originating from various causes, which emerged mainly at the perinatal or infantile period. In fact, recent studies with computerized transverse axial tomographies³ suggest that this syndrome may be a secondary generalized epilepsy with brain lesions for a background.

In this report, an autopsy case is described—in which the patient had generalized epilepsy several years after suffering from acute encephalopathy in childhood. It is thought that the case is a Lennox syndrome, although the age and the EEG findings slightly deviate from typical ones. At the adult period the patient fell into a state of akinetic mutism caused by a head injury.

In this report we attempt to clarify the types and regions of the brain lesions corresponding to the Lennox syndrome

through clinico-neuropathological considerations about the formative process of the lesions, especially the later additional damage from a head injury occurring in the adult period. Moreover, we compare the brain lesions of this case with those of the West syndrome from a viewpoint of neuropathology.

CASE REPORT

A 23-year-old male

His family history was noncontributory. The patient's mother had no difficulties during her pregnancy and the delivery was normal. He was in perfectly good health until the age of seven, when he ran a high fever during the summer and subsequently lapsed into unconsciousness and convulsive fits. He was admitted to a hospital for a month under the suspicion of Japanese encephalitis. He recovered, remaining mental retardation, and after two months epileptic seizures of Jacksonian type occurred, beginning from the left leg or being sometimes general in nature. Gradually the frequency of the seizures increased and an epileptic character change was also noticed. He was admitted to a mental hospital at the age of 14 because of the character change and the frequent attacks of the atstatic seizures which began at the age of nine in addition to the

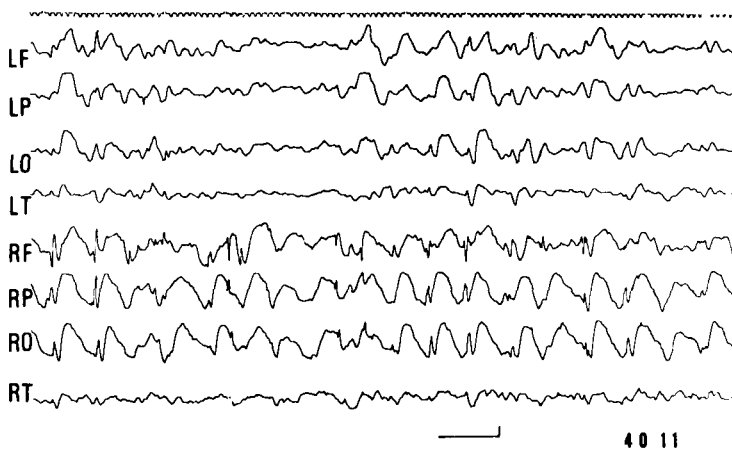


Fig. 1: Diffuse slow spike and wave complex (1.5–2 c/s) with lateralization to the right.

Jacksonian type seizures. After admission, the astatic seizures could not be controlled even with various anti-epileptic drugs, and they were observed two to three times a day on the average. Almost all Jacksonian type seizures were accompanied with a burning sensation before the beginning of the seizures and sometimes only this sensation was observed. The frequency of the seizures dwindled with the course.

No gross neurological abnormalities were noticed. Mental deterioration, slowness of speech and behavior gradually progressed during the long clinical course.

At the age of 21 years, the patient lapsed into a coma followed by a violent fall at a seizure. Subsequently, status epilepticus occurred with the recovery of consciousness. After two weeks of this state, the patient lapsed into a prolonged coma for several weeks. Finally, the patient fell into an akinetic-mute state and the epileptic seizures completely disappeared. After two years he died of pneumonia without recovery from this state.

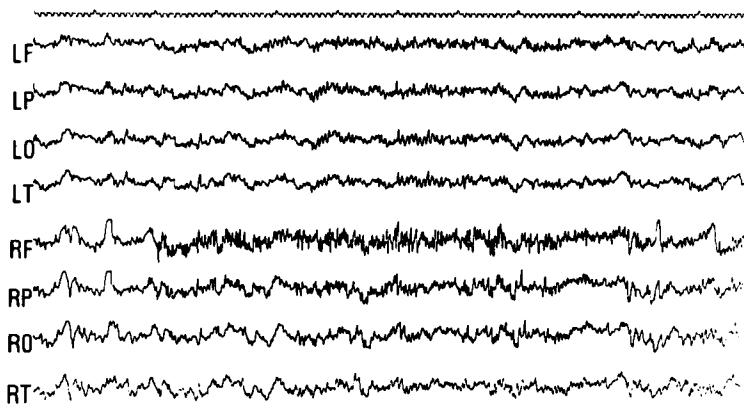
EEG findings—Electroencephalographic

examinations were performed every six months since admission at the age of 14. On admission the EEG findings were abnormal with diffuse slow spike and wave discharges (1.5–2 c/s), which lateralized to the right (Fig. 1), but later these discharges occasionally shifted. In sleep EEG's, rhythmic spikes were also observed with lateralization to the right (Fig. 2). Such characteristic findings continued until the head injury followed by the akinetic-mute state at the age of 21. In that state the EEG's were characterized by low voltage fast waves with sporadic θ waves in all leads, and no seizure discharges were observed.

NEUROPATHOLOGICAL FINDINGS

Gross

Externally, the brain showed so-called "gekreuzte Hemiatrophie". The right cerebral and the left cerebellar hemispheres were markedly reduced in size. There was a widespread, yellowish-brownish pigmentation on the external surface of the non-



413

Fig. 2: Rhythmic spikes with predominancy on the right frontal region.

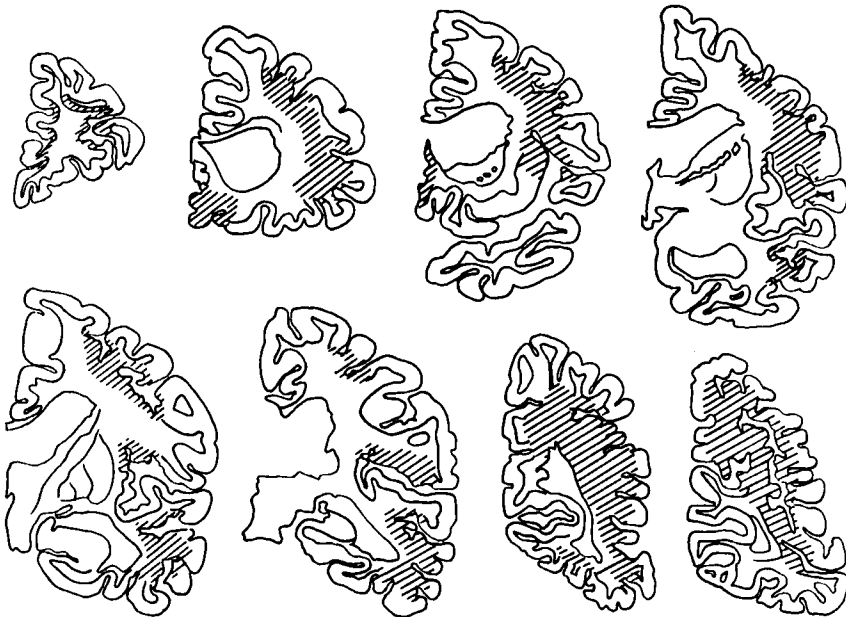


Fig. 8: Regions with necrosis and severe looseness of tissue on coronal sections of the right cerebrum are indicated by oblique lines (▨).

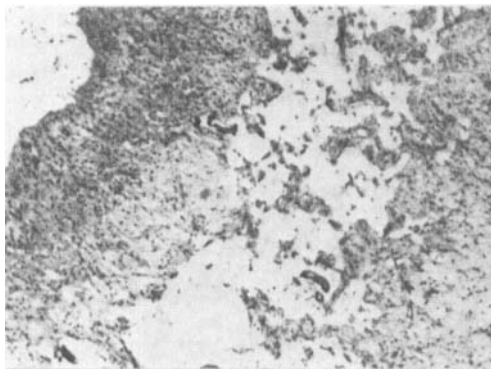


Fig. 4: Old, pseudolaminar necrosis with organization along the wall of the gyrus. Right precentral gyrus. HE stain.

atrophied left cerebrum. On frontal sections of the right cerebrum, widespread old necroses with cysts were seen. The necroses were mainly in the white matter near the cortex and spread to the valleys of the cortical gyri.

The necrotic areas in the right cerebrum were divided into three main regions as follows (Fig. 8): The greatest one was seen consecutively from the central part of the mid-temporal gyrus to the occipital lobe and spread more widely in the dorsal and the ventral directions as they moved caudally. The second one mainly impinged upon the precentral and the mid-frontal gyri and partially involved the supra- and post-central gyri and the insula. The smallest one was found in the pre-frontal area of the orbital and the rectal gyri.

On the other hand, the necroses in the left cerebrum were predominantly in the cingulate and the parahippocampal gyri and partially in the insula cortex. Moreover, small linear necroses were also found in the left pulvinar and the tectum of the midbrain along the wall of the III ventricle and the cerebral aqueduct.

Light microscopy

Cerebrum—Every necrotic region in the

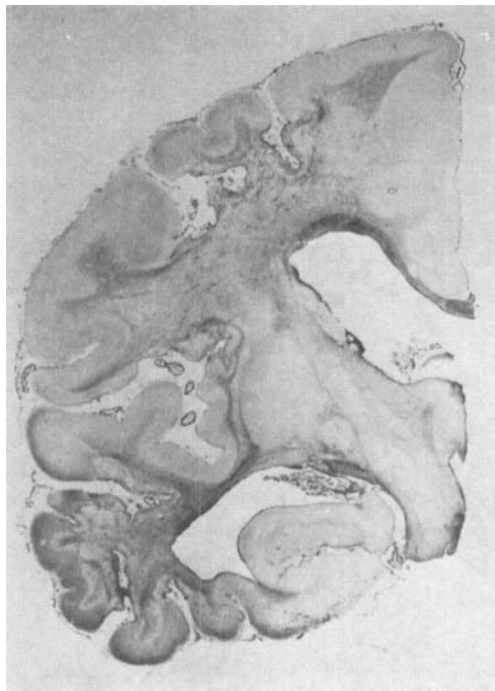

Fig. 3: A lobular sclerosis composed of predominant atrophy and fibrous gliosis in the right cerebral hemisphere. Old necrosis is seen near the border of the cortex and the medulla. Holzer stain.

right cerebral hemisphere had common findings as follows; tissue desolation with many cysts of various sizes among severely atrophied white matter, especially near the border of the cortex and the medulla. The white matter contiguous to the necrotic regions was vastly demyelinated and the surviving coarse axons were also separated. An extension of the necroses to the cortex was observed especially in the valleys of the gyri, where almost all the layers were destroyed. These necroses spread as pseudolaminar along the walls of the gyri (Fig. 4), so the gyri were far apart. The tops of the gyri mostly survived, but some of the middle to large neurons underwent ischemic cell changes. These necrotic

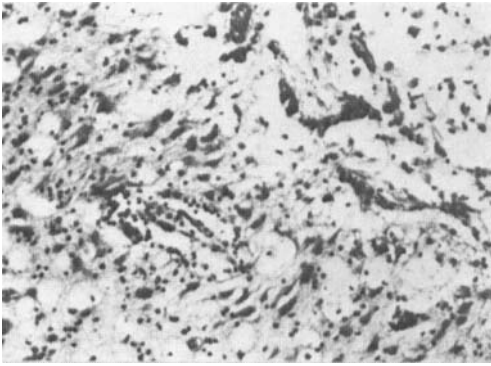


Fig. 5: Cortical necrosis with hypertrophic astrocytes, fat granule cells and vascularization in the left cingulate gyrus. HE stain.

regions of the right cerebral hemisphere represented a complete organization by the proliferation of the parenchyma, especially by the prominent fibrous gliosis. The fibrous gliosis predominantly spread throughout the whole white matter. The gray matter of the right hemispheric internal surface, such as the cingulate and the hippocampal gyri, was well preserved (Fig. 3).

In the left hemisphere, necroses were mainly found in the gray matter of the cingulate and the parahippocampal gyri. The destruction of these limbic areas was accompanied with cleaning, restorative and organizing processes; there were many fat granule cells, prominently proliferated hypertrophic astrocytes, vascularization and fibrous gliosis (Figs. 5 and 6). There was widespread hemosiderin deposition along the sulci in the pia mater and on the external surface of the left hemispheric cortex. But in the necrotic areas, depositions were not detected.

Pathological findings in the basal ganglia and the brain stem nuclei were found mainly on the side having a fiber connection with the damaged right cerebrum, where there was more chronically formed degeneration.

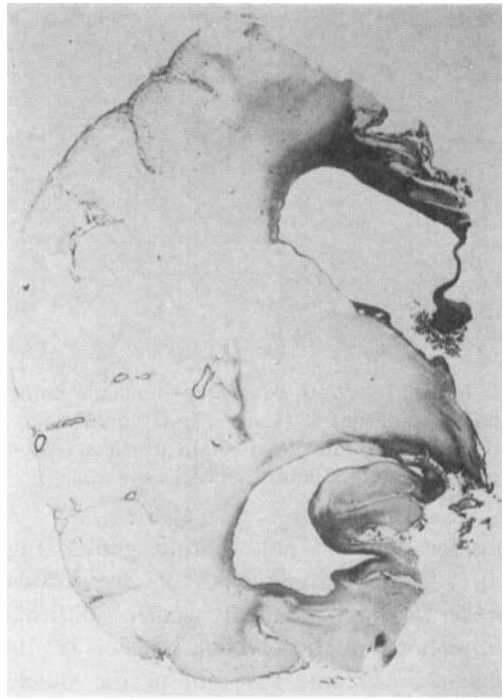

Fig. 6: Prominent fibrous gliosis in the limbic system of the left cerebral hemisphere. Holzer stain.

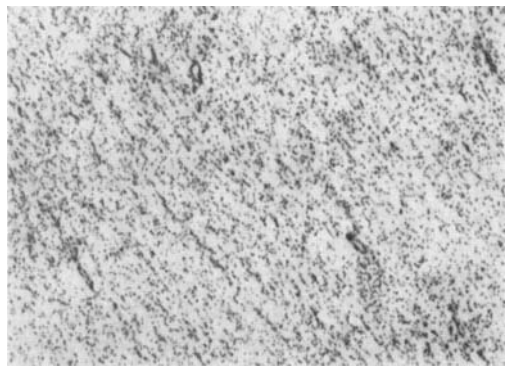


Fig. 10: Severe neuronal loss and atrophy with prominent glial cell proliferation in the lateral part of the right thalamus. Nissl's stain.

Thalamus—The right thalamus lost its normal shape and size, and became thin under the severe atrophy of its lateral portion. The lesions consisted of neuronal loss and atrophy, prominent glial cell

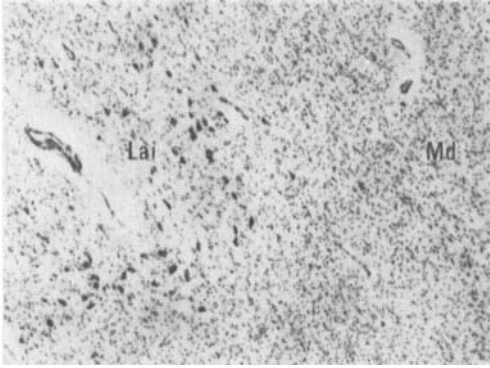


Fig. 11: Well preserved nucleus laminaris internus (Lai) and moderately degenerating nucleus medialis dorsalis (Md) of the right thalamus. Nissl's stain.

proliferation and mild fibrous gliosis (Fig. 10). These chronic types of degenerative processes were found rather diffusely throughout almost all the nuclei of the thalamus except the nonspecific nuclei (ex. Cm, La) (Fig. 11). However, some regional differences in the severity of the lesions were seen (Fig. 9). The lateral and the ventral nuclei had a similar regional tendency, that is, the dorsal and the lateral parts, especially their anterior portion, showed severe changes. The lateral part of the Mda and all the regions of the Mdp showed a moderate loss of neurons. The anterior nucleus was rather well preserved. In the pulvinar, a heavy neuronal loss and prominent glial cell proliferation were observed in the all regions except the medial and a part of the lateral regions. The nuclei of the so-called nonspecific nuclei had the mildest findings. The left thalamic nuclei were well preserved except for moderate degeneration in a part of the anterior nucleus. The linear necrosis in the left pulvinar seemed to be formed somewhat mechanically, where the stria medullaris was torn along the III ventricular wall. This finding continued to the midbrain tectum as already described.

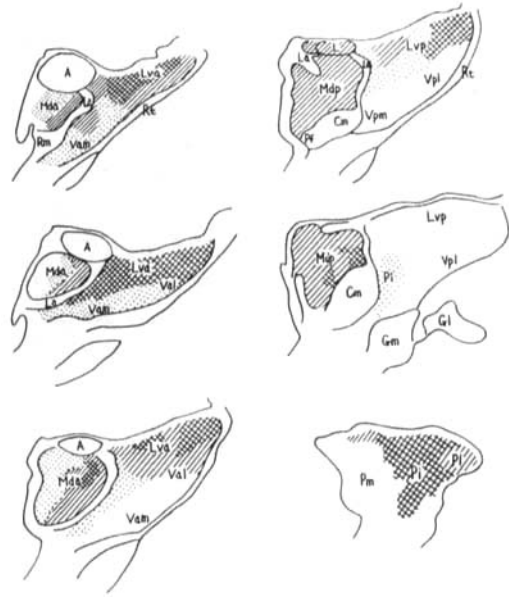


Fig. 9: Secondarily degenerative regions of the right thalamus. (⊗; severe, //; moderate, ▨; mild) A; N. anterior, Cm; N. centrum medianum, G1 (m); Corpus geniculatum lat. (med.), La; N. laminalis, Lva, Lvp; N. lateralis ventralis, Mda, Mdp; N. medialis dorsalis, Pf; N. parafascicularis, Pi, Pl, Pm; N. pulvinaris, Rm; N. reuniens medianus, Rt; N. reticularis, Val(m), Vpl(m); N. ventralis (nomenclature by Niimi).

Striatum and pallidum—Both the striatum and the pallidum were reduced in size in the right brain. The neurons did not diminish in number, but atrophied and cell gliosis was diffuse and pronounced. The left was well preserved.

Hypothalamus—The left hypothalamus showed a looseness of the tissue along the III ventricular wall, where glial clustering and also fibrous gliosis were detected. This lesion related to the linear necrosis of the pulvinar and the midbrain tectum.

Midbrain—The right cerebral peduncle was moderately demyelinated. The substantia nigra of both sides had small cystic necrosis. Slight neuronal loss, melanin




Fig. 7: Linear necrosis with many fat granule cells in the left midbrain tectum. HE stain. Inset: Fibrous gliosis around necrosis (→) and cerebral aqueduct. Holzer stain.

pigment releasing and glial proliferation were also found there. These findings were more marked on the right side.

As for the tectal region, lineally running necrosis was seen in the left central gray matter along the cerebral aqueduct. Around the necrosis, the aqueduct and the superior colliculus, fibrous gliosis was observed (Fig. 7). All the small necrosis in the mid-brain was accompanied by many fat granule cells and cellular infiltrations.

Pons—The tectal regions and the pontine nuclei of both sides were well preserved, but demyelination and slight fibrous gliosis of the pontine longitudinal fibers were seen on the right side.

Medulla oblongata—The most promi-

nent finding in the medulla was severe demyelination of the right pyramis, especially in its inner part. Neurons of the right inferior olivary nucleus were slightly reduced in number and also some were simply atrophied. The tectal regions showed no change.

Cerebellum—Some limited atrophies in the cortex that consisted of thinning of the molecular layer, Purkinje's and granule cell loss and Bergmann's glial proliferation existed in the medial region of the left hemisphere. In particular, Purkinje's cell loss and/or atrophy were detected even in the rather well preserved folia. Many neurons of the left dentate nucleus showed simple atrophy, and gliosis was noted at the hilus. The right hemisphere and the vermis were well preserved.

DISCUSSION

For the complexity of the clinical course and the brain lesions of our case, we must make clear the relation between the two to know the neuropathological aspect of Lennox syndrome.

1) Clinicopathological analyses of the prolonged coma and the akinetic mutism

The necrotic lesions of both the right and left cerebral hemispheres are thought to be formed in close correspondence to the acute, severe clinical symptoms. But the distributional and microscopical differences of the necrotic regions between both hemispheres (i.e., in the right, mainly in the white matter with complete organization; in the left, on the internal surface of the cortex yet with a cleaning process) are thought to indicate the differences of the pathogenesis and of the time when the lesions were formed.

The left brain had necrotic regions in the

cingulate and the parahippocampal gyri, and linear ones were found along the III ventricle and the cerebral aqueduct. Such distributions of necrosis are characteristic. Here we must take into consideration the fact that hemosiderin deposition was widespread on the external surface of the left hemisphere, diffused along the sulci and never found in the necrotic regions, which suggests that the patient had an episode of subarachnoidal hemorrhage.⁸

A series of these neuropathological findings on the left brain can be understood to correspond to the clinical course after the age of 21. Thus, the comatose state after the violent fall, the prolonged coma after the epileptic status and the subsequent akinetic-mute state may be explained as follows. Subarachnoidal hemorrhage most likely resulted from the violent fall, and falx and tentorial herniations of the cingulate and the parahippocampal gyri occurred due to brain edema caused by the frequent convulsions lasting two weeks. These herniations may have led to the mechanical compression and the circulatory disturbance in the brain stem, and subsequently to the linear necrotic lesions. Thus, the long-lasting unconscious state after being freed from convulsions may be due to the midbrain tectal lesions as described by G. Peters¹⁴ and others.¹⁸ The lesions of the limbic system may play an important role in the formation of the akinetic-mute state developing after the acute period.¹⁷ A series of these left brain lesions has no relation to Lennox syndrome.

2) Brain lesions during the period of Lennox syndrome.

Lennox syndrome in the present case was secondarily derived from encephalopathy when the patient was seven years old. It is well known that lobular sclerosis or cerebral hemispheric atrophy of similar

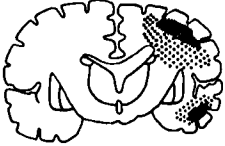


kind is often formed by perinatal injuries or acute encephalopathies in the infantile period.⁶ As the pathogenesis of such lesions, Scholz¹⁵ stresses a circulatory disturbance, while a damage mainly in the white matter caused by edematous changes is stressed by Hallervorden *et al.*⁵ In any case, the right hemispheric sclerosis of the patient may be caused by encephalopathy at the age of seven. The white matter predominancy of the necrosis leads us to the presumption of the edematous damage as the pathogenesis. The patient presented Lennox syndrome at the age of nine probably, or at the latest from 14 to 21 years old. Brain lesions of this period are assumed to be the right hemispheric sclerosis and the degenerative changes of the basal ganglia, especially of the thalamus due to the hemispheric damage.



The severe lesions of the latero-dorsal part of the thalamus suggest convulsive damages. Findings of no disseminated change and no neuronophagia against Scholz's description¹⁵ and degeneration of the pulvinar, which is damaged very rarely by convulsions,¹⁵ suggest that the convulsions must have played only an accessory role of the formation of the thalamic lesions.

The lateralities of the basal ganglionic, the brain stem nuclear and the cerebellar damages according to fiber connections with the right cerebrum lead us to the conclusion that the thalamic lesions may be mainly retrograde degeneration derived from the initial cerebral damages. Jacob's description⁷ of retrograde and transneuronal degeneration of these regions coincides with our findings.

The above described relationships between the clinical course and the formation of the brain lesions are summarized in Table 1. The neuropathological background of Lennox syndrome derived from our case

Table 1: Formation Process of Brain Lesions and Cliniconeuropathological Relationship

| Age | ? | ? ~ ? | ? ~ 14 ~ 21 | 21 | 21 ~ 25 |
|--------------------------------------|---|--|---|--|---|
| clinical events | acute encephalopathy high fever etc. | Jacksonian epilepsy dementia | Lennox syndrome astatic seizure etc. | prolonged coma | akinetic mutism |
| brain lesion | (A); R-hemispheric necrosis (mainly white matter) | (A'); R-hemispheric old lesion (precentralis etc.) | (A)+(B); basal gan- glionic degeneration (R-thalamus etc.) | (C); L-1; mbic system and mainly midbrain tectal necrosis | mainly (A)+(C); L- 1; mbic and midbrain tectal old lesion |
| genesis | edematous change | scar formation | retrograde, convul- sive degeneration etc. | falx, tentorial herniation | oldness of lesion |
| schematic main brain lesion |  | |  |  | |

; necrosis and severe looseness of tissue. ; nonspecific type of degeneration.

is that of a unilateral basal ganglionic degeneration of a later, secondarily formed type based on the diffuse cerebral lesions and good preservation of the nonspecific thalamic nuclei.

As for the Lennox syndrome, Otahara *et al.*¹³ make much account of thalamus, especially the nonspecific nuclei, from electroencephalographical and physiological considerations. The nonspecific nuclear groups of this case were better preserved than the specific nuclear groups, and such a tendency of thalamic lesions is common to physically and mentally severely disturbed children¹⁰ and some thalamic degenerative diseases.¹² This common tendency of thalamic degeneration may be one of the developing factors in common syndromes such as "Lennox" with brain damage of various origins in children.

It is difficult to localize the cerebral regions responsible for Lennox syndrome in our case with diffuse cerebral lesions of the hemisphere. We should consider this syndrome from the viewpoint of the functional relations between cerebrum and basal

ganglia, and of intrathalamic connections based on such nonspecific brain lesions. Considering the fact that epileptic seizures completely disappeared after the age of 21, when the brain lesions may have spread to both hemispheres, the cerebral functions would have to be preserved in some degree for Lennox syndrome to occur. In this sense, cerebral lesions may work only as a pacemaker for seizures as Gloor⁴ and others¹⁸ described. Accordingly, the manner or the degree of damage in the cerebrum should be more significant than the regional specificity.

Some reports of West syndrome,¹⁹ which is clinically closely related with Lennox syndrome, are quite suggestive. Morimatsu⁹ pointed out common findings of West syndrome in the cerebrum, the basal ganglia and the brain stem tectum on his own autopsy cases. Comprehensively, the difference between both types of secondary generalized epilepsies depends on whether or not the brain stem tectum is damaged. Moreover, the brain stem tectal lesions of his cases belonged to such a type of

hypoplasia. This fact may explain a possibility of the shift from West to Lennox syndrome according to the maturation of brain, such as myelination. Here we point out one of the functions of brain stem tectum for a good preservation of synchronization in EEG's, because of a characteristic hypsarrhythmia in West syndrome. It is again significant that the disappearance of the seizures and desynchronization of the EEG's were observed after the brain lesions spread to both hemispheres and reached the brain stem.

SUMMARY

Neuropathological considerations were performed on a case, who went into Lennox syndrome after an acute encephalopathy at the infantile period, and moreover who fell into an akinetic-mute state derived from brain damage by herniation caused by a head injury and subsequent status epilepticus.

Neuropathological background in the present case of Lennox syndrome is thought to be based on the widespread unilateral cerebral lesions and the basal ganglionic, especially thalamic, degenerations derived secondarily from the diffuse cerebral damage.

The patient revealed akinetic mutism with the disappearance of the epileptic seizures and the desynchronization of the EEG's, when the brain lesions formed at the adult period spread over the opposite hemispheric limbic system and the brain stem tectum.

ACKNOWLEDGMENT

The authors would like to thank Jikei Psychiatric Research Institute for excellent technical assistance.

REFERENCES

- 1 Funahashi, M.: Neuropathological findings on the abnormal paroxysmal activities of the scalp EEG, *Brain and Develop.* **7**: 338–347, 1975 (in Japanese).
- 2 Gastaut, H., Roger, J., Soulayrol, R., Tassinari, C.A., Régis, H., Dravet, C., Bernard, R., Pinsard, N. and Saint-Jean, M.: Childhood epileptic encephalopathy with diffuse slow spike-waves (otherwise known as "petit mal variant") or Lennox syndrome, *Epilepsia*, **7**: 139–179, 1966.
- 3 Gastaut, H. and Gastaut, J.L.: Computerized transverse axial tomography in epilepsy, *Epilepsia*, **17**: 325–336, 1976.
- 4 Gloor, P.: Generalized cortico-reticular epilepsies. Some considerations on the pathophysiology of generalized bilaterally synchronous spike and wave discharge, *Epilepsia*, **9**: 249–263, 1968.
- 5 Hallervorden, J. and Meyer, J.-E.: Cerebrale Kinderlähmung. (Früherworbene körperliche und geistige Defektzustände.), *In: Handbuch der Speziellen Pathologischen Anatomie und Histologie*, XIII, **4**: 194–282, 1956, Springer-Verlag, Berlin.
- 6 Ishizaki, T.: Zur Histopathologie der lobären Hirnsklerose, *Psychiat Neurol Jap*, **61**: 114–138, 1959 (in Japanese).
- 7 Jacob, H.: Sekundäre, retrograde und transsynaptische Degeneration, *In: Handbuch der Speziellen Pathologischen Anatomie und Histologie*, XIII, **1**: 266–336, 1957, Springer-Verlag, Berlin.
- 8 Lindenberg, R.: Trauma, *In: Pathology of the Nervous System*, vol. 2: ed. Minckler, 1705–1765, 1971, McGraw-Hill, New York.
- 9 Morimatsu, Y., Murofushi, K., Handa, T., Shinohara, T. and Shiraki, H.: Pathological studies of severe physically and mentally handicapped—with special reference to four cases of infantile spasmus, *Advances Neurol Sci*, **16**: 465–470, 1972 (in Japanese).
- 10 Morimatsu, Y., Shinohara, T., Koya, G., Handa, T., Murofushi, K. and Shiraki, H.: Pathological studies of severe physically and mentally handicapped—with special reference to pathological changes of thalamus, *Advances Neurol Sci*, **17**: 293–304, 1973 (in Japanese).
- 11 Niimi, K.: Anatomy of the human

- thalamus, *Brain and Nerve*, **13**: 307 – 325, 1961 (in Japanese).
- 12 Oda, M., Yoshimura, T. and Okumura, A.: Degeneration of the central nervous system enhanced in the thalamus, *Advances Neurol Sci*, **17**: 238 – 255, 1973 (in Japanese).
 - 13 Ohtahara, S., Oka, E., Ban, T., Yamatogi, Y. and Inoue, H.: The Lennox syndrome —electroencephalographic study, *Clin Neurol*, **10**: 617 – 625, 1970 (in Japanese).
 - 14 Peters, G.: *Klinische Neuropathologie*, 2. Aufl.: 202 – 206, 1970, Georg Thieme Verlag, Stuttgart.
 - 15 Scholz, W.: *Die Krampfschädigungen des Gehirns*, 1951, Springer-Verlag, Berlin.
 - 16 Waltregny, A., Régis, H., Dravet, C. and Gastaut, H.: The contribution of intracarotid sodium amytal tests in the physiopathogenic study of petit mal variant (Lennox syndrome), **In**: *The Physiopathogenesis of the Epilepsies*, ed. Gastaut, H., Jasper, H., Bancaud, J. and Waltregny, A., 277 – 283, 1969, Charles C. Thomas pub., Springfield.
 - 17 Yoshida, M., Shimizu, N. and Ueki, A.: Pathological physiology of akinetic mutism, *Advances Neurol Sci*, **20**: 946 – 956, 1976 (in Japanese).
 - 18 Yoshimura, N. and Ikuta, F.: Posttraumatic chronic encephalopathies; Neuropathological review and investigation (part I), *Brain and Nerve*, **28**: 13 – 27, 1976 (in Japanese).

